



Postoperative Assessment of Pedicle Screws and Management of Breaches: A Survey among Canadian Spine Surgeons and a New Scoring System

Ahmed Aoude*, Saber Ghadakzadeh*, Hamzah Alhamzah,
Maryse Fortin, Peter Jarzem, Jean A. Ouellet, Michael H. Weber

McGill Scoliosis & Spine Centre, McGill University Health Centre, Montreal, Canada

Study Design: This study was designed as a survey amongst Canadian spine surgeon to determine a scoring system to standardize pedicle screw placement assessment.

Purpose: This study aimed to obtain and analyze the opinions of spine surgeons regarding the assessment of pedicle screw accuracy, with the goal of establishing clinical guidelines for interventions for malpositioned pedicle screws.

Overview of Literature: Accurate placement of pedicle screws is challenging, and misalignment can lead to various complications. To date, there is no recognized gold standard for assessing pedicle screw placement accuracy. The literature is lacking studies attempting to standardize pedicle screw placement accuracy assessment.

Methods: A survey of the clinical methods and imaging criteria that are used for assessing pedicle screw placement accuracy was designed and sent to orthopedic and neurosurgery spine surgeons from the Canadian Spine Society for their anonymous participation.

Results: Thirty-five surgeons completed the questionnaire. The most commonly used modalities for assessing pedicle screw position postoperatively were plain X-rays (97%) and computed tomography (CT, 97%). In both symptomatic and asymptomatic patients, the most and least worrisome breaches were medial and anterior breaches, respectively. The majority of surgeons tended not to re-operate on asymptomatic breaches. More than 60% of surgeons would re-operate on patients with new-onset pain and a ≤ 4 -mm medial or inferior breach in both thoracic and lumbar regions. If a patient experienced sensory loss and a breach on CT, in either the thoracic or lumbar levels, 90% and 70% of the surgeons would re-operate for a medial breach and an inferior breach, respectively.

Conclusions: Postoperative clinical presentation and imaging findings are crucial for interpreting aberrant pedicle screw placement. This study presents a preliminary scoring system for standardizing the classification of pedicle screws.

Keywords: Pedicle screw accuracy; Scoring system for pedicle screw placement; Guidelines for pedicle screw revision; Pedicle screw grading; Canadian spine surgeon survey

Introduction

Pedicle screws were first used by Harington in the United

States to reduce complicated cases of spondylolisthesis [1,2]. Pedicle screws are currently used for treating vertebral fractures, degenerative disc disease, spine tumors,

Received Mar 7, 2017; Revised Mar 14, 2017; Accepted Jun 4, 2017

Corresponding author: Ahmed Aoude

McGill University Health Centre, Montreal General Hospital, 1650 Cedar Ave, Montreal, QC, Canada, H3G 1A4

Tel: +1-514-758-6336, Fax: +1-514-934-8320, E-mail: ahmed.aoude@gmail.com

*These authors contributed equally to this work.

spondylolisthesis, scoliosis, and many other ailments that affect the spine. Pedicle screws that are placed within the vertebra pedicle allow for vertebral stability and restore vertebral height and alignment [3].

Screw placement accuracy is of utmost importance and is critical in spine surgery. Aberrant screw placement can lead to various complications, including neurological impairment, radicular pain, weakness or sensory loss, and even paralysis. However, the risk for such complications is usually low for trained and experienced spine surgeons [3]. We recently conducted an extensive literature review to determine the most widely used methods for the assessment of pedicle screw placement [4]. Our review revealed no clear method for assessing the position of pedicle screws but found that most surgeons use a computed tomography (CT) grading system based on 2-mm increments to assess accuracy. There were no evaluation systems that considered patient symptoms, either as part of a classification scheme or for the subsequent management of the patient.

There is currently no gold standard method for assessing pedicle screw placement accuracy. This study aimed to obtain and analyze the opinions of spine surgeons regarding the assessment of pedicle screw accuracy, with the goal of establishing clinical guidelines for surgeons who consider interventions for malpositioned pedicle screws. Such guidelines would be important for accurately assessing screws for safety reasons. In addition, given all the advances in computer-assisted surgery (CAS), these guidelines could serve as the gold standard required to judge CAS and compare it to free hand or other evaluation systems. By avoiding unnecessary procedures, such guidelines could eliminate the cost of postoperative patient follow-up.

Materials and Methods

A 29-item online survey in English (Appendix 1) was designed for use with orthopedic and neurosurgery spine surgeons who were members of the Canadian Spine Society (CSS). The survey questioned about the clinical and imaging criteria that are used by surgeons to assess pedicle screw placement accuracy and about the management of clinically symptomatic or asymptomatic patients with screw breaches of different magnitudes and at different locations. The symptoms considered included weakness, pain, and sensory loss (in more than one dermatome).

A request to participate in the survey was electronically sent to all the surgeon members of CSS; this included a link to the questionnaire, which the surgeon could anonymously complete. Only members with a previous practical experience of assessing pedicle screw accuracy were invited to participate. Descriptive statistics were used to analyze the survey results, and the responses were analyzed and grouped based on answer likelihood.

Results

The survey was sent to 111 CSS surgeon members (72 orthopedic surgeons and 39 neurosurgeons). Of these, 35 (31.5%) anonymously completed the survey, and all responded that they routinely used pedicle screws in their practice. The survey was designed to differentiate between thoracic and lumbar levels. However, it was noted that consensus was similar for both regions.

1. Types of imaging used

Intraoperatively, the majority (73.5%) of respondents used fluoroscopy as the main imaging modality. Some also used intraoperative CT (29.4%) or neuromonitoring (23.5%). These lower rates for using intraoperative CT and neuromonitoring may be owing to the Canadian or surgeon preference bias. Postoperatively, the modalities most commonly used to assess pedicle screw position were plain X-rays (97%) and CT (97%), followed by magnetic resonance imaging (MRI, 55.8%) and CT myelograms (32.5%). Although most responding surgeons used CT for assessing pedicle screws, none used CT in all cases. The surgeons were most likely to ask for CT if a patient presented with new-onset weakness (94.1%) or sensory change (70.6%) or if an intraoperative complication was present (67.6%).

2. Pedicle screw assessment criteria

When assessing pedicle screw accuracy postoperatively, more than half of the respondents (56%) deemed the most important image plane to be axial, with 6% choosing coronal cuts and 3% sagittal cuts, and the remaining 35% reporting that all three planes were equally important. Medial pedicle breaches were ranked as the most worrisome by the majority of respondents (91%), followed in the descending order of importance by inferior, lateral,

superior, and anterior breaches.

3. Criteria for re-operating on asymptomatic patients

When patients were asymptomatic, most surgeons tended not to re-operate solely on the basis of imaging for a breach in the thoracic or lumbar region. However, medial and inferior breaches of >6 mm, even without symptoms, were considered to be a concern, with almost 25% of surgeons reporting that they would remove the misplaced screw. Asymptomatic lateral, superior, or anterior breaches at the lumbar or thoracic levels were less concerning, and approximately 75% of the surgeons would not re-

operate (Fig. 1).

4. Criteria for re-operating on symptomatic patients

1) Weakness

If a patient was symptomatic with corresponding findings on imaging, the surgeons generally opted for surgical management. New weaknesses were considered to be the most worrisome when a medial breach was determined on CT in the lumbar or thoracic region; all the surgeons stated that they would re-operate to correct the screw position, with none electing for observation alone. Cases with a new weakness and corresponding inferior or lateral

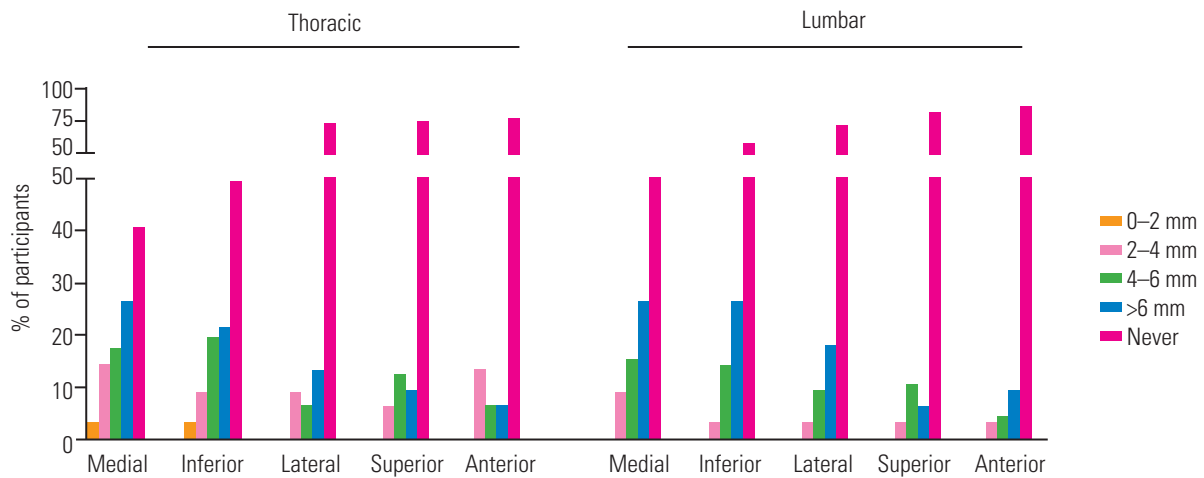


Fig. 1. Asymptomatic patients with a postoperative pedicle screw breach. The majority of surgeons tended not to re-operate on asymptomatic breaches. However, almost 25% of surgeons would remove the misplaced screw when there was a medial or inferior breach, even when patients were asymptomatic.

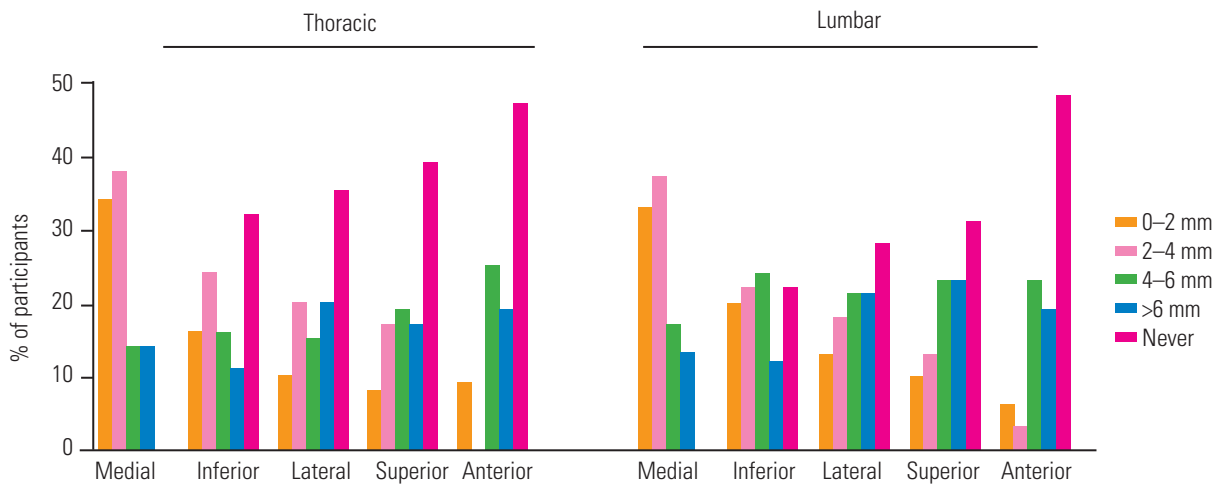


Fig. 2. New-onset weakness in patients with a postoperative pedicle screw breach. When a medial breach was identified on computed tomography in the lumbar or thoracic region, all surgeons would re-operate to correct the screw position if the patient presented with new weakness. However, 50% of surgeons would not operate on a patient with new-onset weakness and an anterior thoracic or lumbar breach.

breach were the next most concerning problems, with 40% and 30% of the surgeons, respectively, electing to operate even on breaches of ≤ 4 mm. However, approximately 50% of the respondents reported that they would not re-operate on a patient with new-onset weakness and an anterior thoracic or lumbar breach, even if the breach was >6 mm (Fig. 2).

2) Pain

Among patients who postoperatively presented with new radicular pain and a corresponding breach on CT, those with medial or inferior breaches were the most concerning. For a painful medial breach in the thoracic or lumbar regions, even one of ≤ 4 mm, the majority of surgeons ($>60\%$) would re-operate. None of the surgeons elected

not to re-operate on symptomatic patients with medial breaches in the thoracic region, whereas only one surgeon (3%) selected conservative management for a case in which the breach was at the lumbar level. In contrast, approximately 50% of the surgeons would re-operate on inferior breaches as small as ≤ 4 mm in the thoracic and lumbar regions, whereas $>20\%$ of the surgeons selected not to operate on pain with inferior breaches altogether. The third most concerning breach with new-onset radicular pain was a lateral breach, with approximately 70% of surgeons deciding to operate on breaches of up to 6 mm and the rest choosing conservative treatment for both the lumbar and thoracic regions. Conservative management was more common for superior (30%) or anterior (40%) breaches in both the thoracic and lumbar regions for pa-

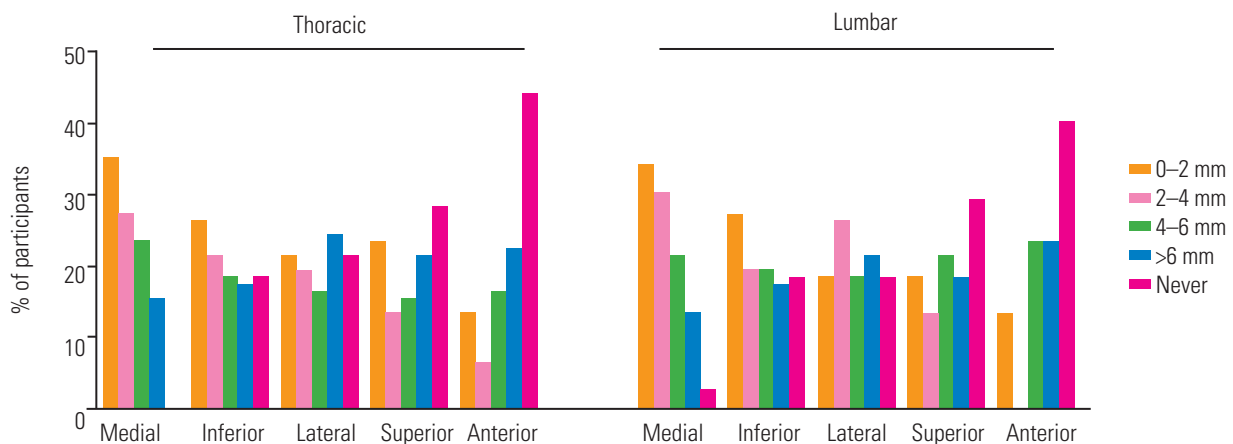


Fig. 3. New-onset pain in patients with a postoperative pedicle screw breach. More than 60% of respondents would re-operate on patients with new-onset pain and a medial breach of ≤ 4 mm in the thoracic or lumbar regions.

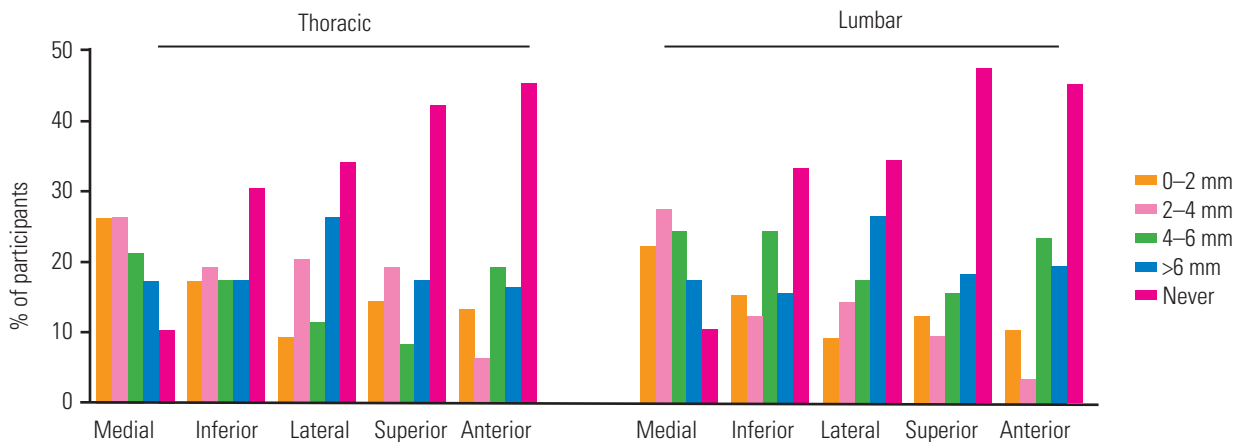


Fig. 4. New-onset sensory loss in patients with a postoperative pedicle screw breach. For a patient with sensory loss and a medial or inferior breach on computed tomography at the thoracic or the lumbar level, 90% and 70% of the surgeons, respectively, would perform a corrective operation.

tients with postoperative new-onset radicular pain (Fig. 3).

3) Sensory loss

In cases of new dermatomal sensory loss, when a medial breach in the thoracic or lumbar regions was determined on CT, 90% of the surgeons would perform a corrective operation. With these sensory symptoms, nearly 70% of the respondents also selected a surgical approach for breaches with an inferior location. However, when the same symptoms were present with a lateral, superior, or anterior breach, 35%–45% of surgeons would not re-operate. Most of the surgeons who responded in favor of re-operation for a new sensory loss would take the patient back to the operating room only if a substantial breach of >4 mm was observed on CT (Fig. 4).

5. A new scoring system

The decision to re-operate on a patient to address a misplaced screw is far from straightforward. Many surgeons base their decision on both clinical and radiological findings, as reflected in our survey results. Based on the trends observed in the surgeons' responses, we were able to generate a preliminary scoring system to help surgeons decide when to re-operate for misplaced screws. This new scoring system will allow an objective postoperative assessment of the patient before making the decision on whether to correct a pedicle screw.

The details of the scoring system are presented in Table 1. Based on the survey results and the surgeons' level of concern over the breach size, its location, and associated clinical symptoms, we assigned different scores to each predictor. The scoring system involves two main factors: (1) the location and size of the breach on CT and

(2) any corresponding clinical symptoms. A total of 0–8 points can be obtained, depending on the imaging and clinical scenario. Higher scores correspond to more worrisome breaches (i.e., medial) or symptoms (i.e., pain and weakness). Using a cutoff score of 6 in our proposed scoring system appears to predict most of the cases in the survey where the surgeons would re-operate on the patient. The scoring system, its predictor variables, and their assigned scores are under investigation and will be validated in a separate study.

Discussion

There is no gold standard clinical standard method for assessing the positions of pedicle screws postoperatively. Many different methods, including X-rays, CT, and MRI, have been described in the literature, as shown in our previous review [4]. Kim et al. [5] demonstrated that intraoperative plain radiographs could be used to determine whether a screw was malpositioned. Interestingly, however, they used postoperative CT to validate their method with an "in or out" classification. We believe there should be a standardized method for determining postoperative pedicle screw accuracy and that it should be based on CT imaging. This study aimed to obtain and analyze the opinions on this topic of spine surgeons based in Canada and to develop a new scoring system intended to standardize decisions for the corrective surgery of misplaced pedicle screws.

Most surgeons use imaging for pedicle screw position assessment both intraoperatively and postoperatively. Our results showed that the majority of the spine surgeons used X-rays (97%) and CT (97%) for assessing the pedicle screw position postoperatively. The survey also demon-

Table 1. New scoring system based on the survey results

Location	Based on imaging (axial cut)				Corresponding symptoms	
	>6 mm breach	4–6 mm breach	2–4 mm breach	<2 mm breach		
Medial	4	3	2	1	New radicular pain	4
Inferior	2	2	1	0	New weakness	4
Lateral	2	2	1	0	New sensory loss	1
Superior	1	1	0	0	No symptoms	0
Anterior	1	1	0	0		

Add imaging score+symptoms score: a score of 6 or more warrants pedicle screw repositioning.

strated that the majority of surgeons (56%) assessed accuracy based on axial cuts. It can be assumed that a standard of practice is to use CT to assess postoperative screw positions, as shown in our previous review [4] and the present survey. CT offer the ability to visualize the bony anatomy of the vertebrae and to assess in all directions whether a screw is malpositioned, with lower artifact levels than MRI [6]. **Therefore, our recommended scoring system includes a category of scores based on the location and size of the breach observed on axial CT cuts.**

This study also showed that clinical presentation is crucial for determining the management of aberrant screw placement. It demonstrated that a patient with symptoms and a concordant breach on imaging was considered more worrisome than a larger breach for which the patient was completely asymptomatic. This was highlighted in the results that showed a lower probability of re-operation (5%–60%, depending on the size, level, and position of the breach) for patients with a breach on imaging but no clinical symptoms. In contrast, new radicular pain and weakness with a proven breach on imaging resulted in the majority of surgeons (60%–100%, depending on the size, level, and location of the breach) considering re-operation for screw repositioning or removal. Not all symptoms resulted in a similar level of concern. Approximately 70%–90% of surgeons chose observation rather than re-operation when a new sensory loss was present with a proven breach of <2 mm on imaging. However, when there was pain or weakness, approximately 65% and 50% of the surgeons, respectively, opted for surgical treatment for medial and inferior breaches of up to 4 mm. Thus, new symptoms affected the surgeons' decision process with regard to pedicle screw revision for malposition. Collectively, radicular pain and weakness were considered more worrisome than a new sensory loss. Therefore, our proposed scoring system also includes a category for ranking and scoring corresponding symptoms. To the best of our knowledge, there has been no previously published scoring system based on a combination of both imaging and clinical symptoms to help decisions regarding when to re-operate for a misplaced screw.

The location of the breach also influenced the decision to operate on a patient with a misplaced pedicle screw. Our results demonstrated that medial breaches raised were the most concerning among the surgeons, followed by inferior, lateral, superior, and anterior breaches. Although our results did not show there was much concern

about anterior breaches, Park et al. [7] noted that besides visceral or vascular injury, proximal junction failure can more frequently occur, particularly in upper instrumented vertebrae with anterior breaches. The survey results were similar for both symptomatic and asymptomatic patients, although breaches with symptoms were generally of much greater concern to the surgeons. For example, a medial breach was more likely to be operated on than a similarly sized lateral breach. An inferior breach was the second most concerning breach; even when asymptomatic, almost 50% of the respondents chose to surgically correct inferior breaches of ≥ 2 mm at the thoracic level. In symptomatic patients, inferior breaches were the second source of concern after medial breaches, with approximately 20%–30% of the surgeons stating that they would re-operate on breaches of even <2 mm, depending on concomitant symptoms. Thus, our new scoring system considers both the location and degree of breach of pedicle screws.

A standardized grading system is required to allow a more objective method of identifying which pedicle screws can be deemed safe or unsafe. Such a system should include both three-dimensional criteria (particularly the location in which the breach occurs) and clinically relevant patient data. The lack of such a standardized grading system in the literature [4] makes it difficult to evaluate the pedicle screw position and determine the need for revision. The results of our survey demonstrated that the surgeons' opinions on certain clinical scenarios differed, but more than half of the surgeons who responded agreed on the same management for most cases. As highlighted by our survey results, a standardized grading system should consider both imaging and patient clinical data. Hence, a complete grading system should include (1) the degree of breach, as measured on imaging; (2) the location of the breach; and (3) the presence or absence of corresponding clinical symptoms. The system should be practical and should use systematic evaluations so that results are reproducible. In addition, completing the assessment in a timely fashion based on standard imaging (a CT scan axial cut, which allows for the best assessment of the most worrisome breaches, which were medial or inferior). This was highlighted by the surgeons' responses to our survey and is captured in the proposed new scoring system.

One limitation of this study was the relatively low response rate (31.5%), but this was comparable with the response rate in many previous survey-based studies of

specialists [8]. **Even with this response rate, it was obvious** that the clinical presentation of the patients following misplaced pedicles screws was an important factor in the management of the screw breaches. In future, we need to consider alternative approaches to engage more efficiently with surgeons and to improve the response rate. However, we are confident that we have addressed a limitation in the spine literature by developing a postoperative pedicle screw breach scoring system based on both clinical and radiological findings. It is also important to note that the patient's overall status, prognosis, underlying etiology (such as metastatic disease), and neurological status before surgery can all affect the decision for corrective surgery. Thus, even with a scoring system such as the one presented here, individual patient cases should be considered with the patient's overall clinical picture in mind.

Conclusions

We presented the survey results of 35 spine surgeons with the aim of improving the assessment of pedicle screw position and accuracy. We believe that there has previously not been an ideal unified classification system to help guide spine surgeons in the assessment of safe pedicle screw positioning. A recent systematic review showed that a grading system based on 2-mm increments on CT is a widely accepted system [4]. However, none of the current grading systems for evaluating pedicle screw breaches consider the direction of the breach and any accompanying clinical symptoms of the patients. Based on the study results, we suggest that spine surgeons should evaluate the degree and location of a breach, along with any corresponding clinical symptoms, to determine whether a screw warrants revision. We also proposed a preliminary scoring system to standardize the classification of pedicle screws and help surgeons decide which pedicle screws warrant corrective operation. This presents an economic

solution to the current lack of such guidelines and should help ensure patient welfare.

Conflict of Interest

No potential conflict of interest relevant to this article was reported.

References

1. Harrington PR, Dickson JH. Spinal instrumentation in the treatment of severe progressive spondylolisthesis. *Clin Orthop Relat Res* 1976;(117):157-63.
2. Harrington PR, Tullos HS. Reduction of severe spondylolisthesis in children. *South Med J* 1969;62:1-7.
3. Boos N, Webb JK. Pedicle screw fixation in spinal disorders: a European view. *Eur Spine J* 1997;6:2-18.
4. Aoude AA, Fortin M, Figueiredo R, Jarzem P, Ouellet J, Weber MH. Methods to determine pedicle screw placement accuracy in spine surgery: a systematic review. *Eur Spine J* 2015;24:990-1004.
5. Kim YJ, Lenke LG, Cheh G, Riew KD. Evaluation of pedicle screw placement in the deformed spine using intraoperative plain radiographs: a comparison with computerized tomography. *Spine (Phila Pa 1976)* 2005;30:2084-8.
6. Ebraheim NA, Savolaine ER, Stitgen SH, Jackson WT. Magnetic resonance imaging after pedicular screw fixation of the spine. *Clin Orthop Relat Res* 1992;279:133-7.
7. Park YS, Hyun SJ, Choi HY, Kim KJ, Jahng TA. Association between bicortical screw fixation at upper instrumented vertebra and risk for upper instrumented vertebra fracture. *J Neurosurg Spine* 2017;26:638-44.
8. Cunningham CT, Quan H, Hemmelgarn B, et al. Exploring physician specialist response rates to web-based surveys. *BMC Med Res Methodol* 2015;15:32.

Appendix 1. Survey questions

1. What imaging do you use intraoperatively to determine screw placement?
 - a. Fluoroscopy
 - b. intraoperative computed tomography (CT) scan
 - c. intraoperative magnetic resonance imaging (MRI)
 - d. Plain X-ray
 - e. Neuro-monitoring
 - f. None
 - g. Other (please specify)
2. Please indicate the postoperative imaging modality you use to assess pedicle screw accuracy. Please order your three mostly used modalities (order 1 to 5, one being the most frequently used modality and five the least frequently used)
 - a. X-ray
 - b. CT scan
 - c. CT myelogram
 - d. MRI
 - e. Other
3. Do you order postoperative CT-imaging for all cases? Yes or No
4. If No was answered for 3. The following was asked: Since you do not order postoperative CT imaging for all cases; would you order postoperative CT imaging for:
 - a. New weakness
 - b. New sensory change
 - c. Number of fused levels >4
 - d. Number of fused levels >7
 - e. intraoperative complications
 - f. Other (please specify)
5. Using imaging for accuracy of pedicle screw position what plane of imaging is most important postoperatively?
 - a. Axial
 - b. Coronal
 - c. Sagittal
 - d. All three
6. Please rank the following breaches in order of importance (1 being the most important and 5 the least)
 - a. Lateral of pedicle
 - b. Medial of pedicle
 - c. Anterior vertebral body
 - d. Superior vertebral body
 - e. Interior vertebral body
7. Do you consider that the region at which pedicle screw breach occurs to be relevant in deciding if a screw is safe or not? (Ex., A breach in the lumbar region should be considered differently than a breach in the thoracic region) Yes or No
8. The following questions were asked for both lumbar and thoracic regions if Yes was answered to question 7 or as follows if No was selected:
 - A. Given there is a medial breach on CT imaging, when would you take a patient back to the operating room to remove a screw (based on imaging alone with no clinical change in symptoms)?
 - a. 0–2 mm Breach
 - b. 2–4 mm Breach
 - c. 4–6 mm Breach
 - d. >6 mm Breach
 - e. Never
 - B. Given there is a lateral breach on CT imaging, when would you take a patient back to the operating room to remove a screw (based on imaging alone with no clinical change in symptoms)?
 - a. 0–2 mm Breach
 - b. 2–4 mm Breach
 - c. 4–6 mm Breach
 - d. >6 mm Breach
 - e. Never
 - C. Given there is an anterior breach on CT imaging, when would you take a patient back to the operating room to remove a screw (based on imaging alone with no clinical change in symptoms)?
 - a. 0–2 mm Breach
 - b. 2–4 mm Breach
 - c. 4–6 mm Breach
 - d. >6 mm Breach
 - e. Never
 - D. Given there is an inferior breach on CT imaging, when would you take a patient back to the operating room to remove a screw (based on imaging alone with no clinical change in symptoms)?
 - a. 0–2 mm Breach
 - b. 2–4 mm Breach
 - c. 4–6 mm Breach
 - d. >6 mm Breach
 - e. Never
 - E. Given there is a superior breach on CT imaging, when would you take a patient back to the operating room to remove a screw (based on imaging alone with no clinical change in symptoms)?
 - a. 0–2 mm Breach
 - b. 2–4 mm Breach
 - c. 4–6 mm Breach
 - d. >6 mm Breach
 - e. Never
 - F. Given there is a medial breach on CT imaging, when would you take a patient back to the operating room to remove a screw if the patient had corresponding new weakness (greater than 1 grade).
 - a. 0–2 mm Breach
 - b. 2–4 mm Breach
 - c. 4–6 mm Breach
 - d. >6 mm Breach
 - e. Never
 - G. Given there is a medial breach on CT imaging, when would you take a patient back to the operating room to remove a screw if the patient had corresponding new weakness (greater than 1 grade).
 - a. 0–2 mm Breach
 - b. 2–4 mm Breach
 - c. 4–6 mm Breach
 - d. >6 mm Breach
 - e. Never
 - H. Given there is a lateral breach on CT imaging, when would you take a patient back to the operating room to remove a screw if the patient had corresponding new weakness (greater than 1 grade).
 - a. 0–2 mm Breach
 - b. 2–4 mm Breach
 - c. 4–6 mm Breach
 - d. >6 mm Breach
 - e. Never

- I. Given there is an anterior breach on CT imaging, when would you take a patient back to the operating room to remove a screw if the patient had corresponding new weakness (greater than 1 grade).
- 0–2 mm Breach
 - 2–4 mm Breach
 - 4–6 mm Breach
 - >6 mm Breach
 - Never
- J. Given there is an inferior breach on CT imaging, when would you take a patient back to the operating room to remove a screw if the patient had corresponding new weakness (greater than 1 grade).
- 0–2 mm Breach
 - 2–4 mm Breach
 - 4–6 mm Breach
 - >6 mm Breach
 - Never
- K. Given there is a superior breach on CT imaging, when would you take a patient back to the operating room to remove a screw if the patient had corresponding new weakness (greater than 1 grade).
- 0–2 mm Breach
 - 2–4 mm Breach
 - 4–6 mm Breach
 - >6 mm Breach
 - Never
- L. Given there is a medial breach on CT imaging, when would you take a patient back to the operating room to remove a screw if the patient had corresponding new single dermatomal sensory loss?
- 0–2 mm Breach
 - 2–4 mm Breach
 - 4–6 mm Breach
 - >6 mm Breach
 - Never
- M. Given there is a lateral breach on CT imaging, when would you take a patient back to the operating room to remove a screw if the patient had corresponding new single dermatomal sensory loss?
- 0–2 mm Breach
 - 2–4 mm Breach
 - 4–6 mm Breach
 - >6 mm Breach
 - Never
- N. Given there is an anterior breach on CT imaging, when would you take a patient back to the operating room to remove a screw if the patient had corresponding new single dermatomal sensory loss?
- 0–2 mm Breach
 - 2–4 mm Breach
 - 4–6 mm Breach
 - >6 mm Breach
 - Never
- O. Given there is an inferior breach on CT imaging, when would you take a patient back to the operating room to remove a screw if the patient had corresponding new single dermatomal sensory loss?
- 0–2 mm Breach
 - 2–4 mm Breach
 - 4–6 mm Breach
 - >6 mm Breach
 - Never
- P. Given there is a superior breach on CT imaging, when would you take a patient back to the operating room to remove a screw if the patient had corresponding new single dermatomal sensory loss?
- 0–2 mm Breach
 - 2–4 mm Breach
 - 4–6 mm Breach
 - >6 mm Breach
 - Never
- Q. Given there is a medial breach on CT imaging, when would you take a patient back to the operating room to remove a screw if the patient had new corresponding radicular pain?
- 0–2 mm Breach
 - 2–4 mm Breach
 - 4–6 mm Breach
 - >6 mm Breach
 - Never
- R. Given there is a lateral breach on CT imaging, when would you take a patient back to the operating room to remove a screw if the patient had new corresponding radicular pain?
- 0–2 mm Breach
 - 2–4 mm Breach
 - 4–6 mm Breach
 - >6 mm Breach
 - Never
- S. Given there is an anterior breach on CT imaging, when would you take a patient back to the operating room to remove a screw if the patient had new corresponding radicular pain?
- 0–2 mm Breach
 - 2–4 mm Breach
 - 4–6 mm Breach
 - >6 mm Breach
 - Never
- T. Given there is an inferior breach on CT imaging, when would you take a patient back to the operating room to remove a screw if the patient had new corresponding radicular pain?
- 0–2 mm Breach
 - 2–4 mm Breach
 - 4–6 mm Breach
 - >6 mm Breach
 - Never
- U. Given there is a superior breach on CT imaging, when would you take a patient back to the operating room to remove a screw if the patient had new corresponding radicular pain?
- 0–2 mm Breach
 - 2–4 mm Breach
 - 4–6 mm Breach
 - >6 mm Breach
 - Never
9. If a patient has a new weakness (greater than 1 grade loss of power) with proven corresponding breach on CT imaging what would be your next step(s) (more than one answer is possible here)?
- Operate
 - Wait and see for <24 hr
 - Wait and see for >24 hr
 - Spinal injection (cortisone)
 - MRI
 - CT myelogram
 - Other (please specify)

10. If a patient has a new single dermatomal sensory loss with proven corresponding breach on CT imaging what would be your next step(s) (more than one answer is possible here)?
- Operate
 - Wait and see for <24 hr
 - Wait and see for >24 hr
 - Spinal injection (cortisone)
 - MRI
 - CT mylogram
 - Other (please specify)
11. If a patient has a new radicular pain with proven corresponding breach on CT imaging what would be your next step(s) (more than one answer is possible here)?
- Operate
 - Wait and see for <24 hr
 - Wait and see for >24 hr
 - Spinal injection (cortisone)
 - MRI
 - CT mylogram
 - Other (please specify)