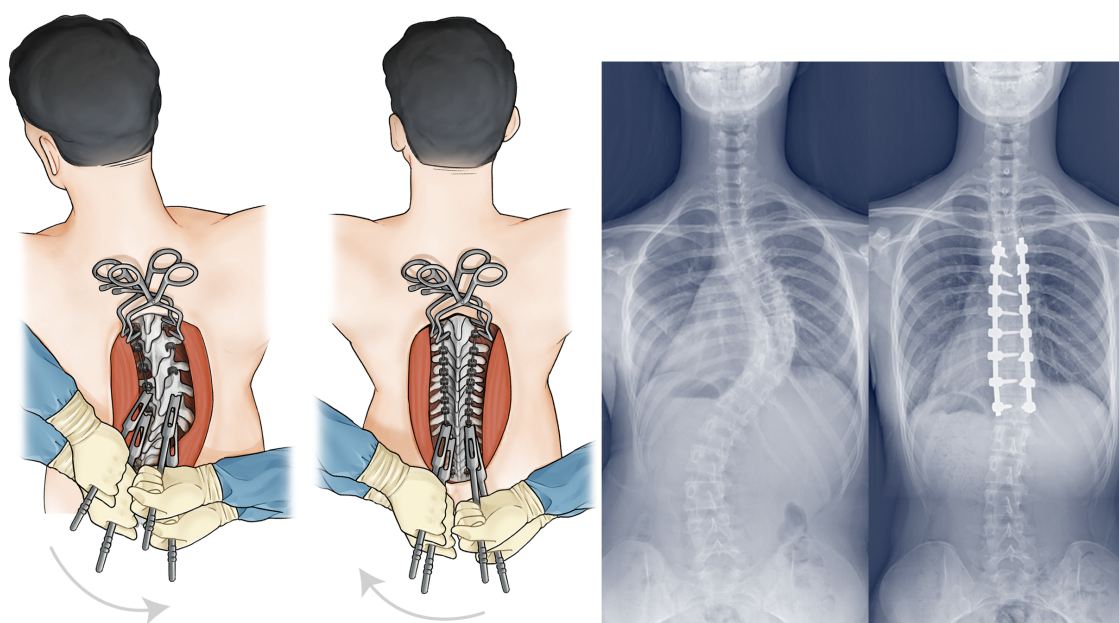


# ASIAN SPINE JOURNAL

Volume 17 · Number Supplement 1 · May 2023



*High-Density Pedicle Screw Construct with Direct Vertebral Derotation*

*Sam Yeol Chang et al. - Asian Spine J 2023;17(2):338-346*

**APSS 2023**

(APSS Annual Meeting 2023 with Live Operative Surgical Course)

**1-3 May 2023,**

**Melbourne Convention & Exhibition Centre (MCEC), Australia**



# ASIAN SPINE JOURNAL

www.asianspinejournal.org  
pISSN 1976-1902 · eISSN 1976-7846

Official Journal of the Asia Pacific Spine Society (APSS), Middle East Spine Society (MESS), Association of Spine Surgeons of India (ASSI), Taiwan Spine Society (TWSS), and Korean Society of Spine Surgery (KSSS), Chinese Spine Society of Medicine Education (CSSME)

## Aims & Scope

*Asian Spine Journal* (Asian Spine J), the official journal of the Asia Pacific Spine Society (APSS), Middle East Spine Society (MESS), Association of Spine Surgeons of India (ASSI), Taiwan Spine Society (TWSS), Chinese Spine Society of Medicine Education (CSSME), and Korean Society of Spine Surgery (KSSS), is an international peer-reviewed journal which publishes articles related to basic and clinical researches of all spine fields bimonthly in end of February, April, June, August, October, and December. *Asian Spine Journal* was founded in 2007.

The journal aims to promote communications among spine surgeons especially in Asian countries regarding spine problems and to provide Asian spine surgeons more opportunities to publish their works in international journal. All manuscripts should be creative, informative and useful for the diagnosis and treatment of spine problems. Manuscripts regarding disease and treatment which shows more characteristic features in Asian people would be preferable. Every researcher who has interested in the aims and scope of *Asian Spine Journal* is encouraged to submit the papers from all over the world.

## Copyright © 2023 Korean Society of Spine Surgery

Articles published in *Asian Spine Journal* are open-access, distributed under the terms of the Creative Commons Attribution Non-Commercial License (<http://creativecommons.org/licenses/by-nc/4.0/>), which permits unrestricted non-commercial use, distribution, and reproduction in any medium, provided the original work is properly cited.

Submitting an article to *Asian Spine Journal* implies that the authors confirm: that all authors read the article and approved of its

publication, that the article is original and has not been published before, that it is not under consideration for publication elsewhere, and that copyrights of all published materials, including figures, are owned by Korean Society of Spine Surgery.

## Subscription Information

- Korean Society of Spine Surgery will send *Asian Spine Journal* for free to some important individuals and institutions. The subscription fee will be charged only for those issues that were requested by written order. The subscription fee includes postal and handling charges.
- For individual subscribers, the annual subscription fee is 20,000 won (Korean) or 30 US dollars (International). The subscription fee for a single issue is 10,000 won (Korean) or 15 US dollars (International). For institutional subscribers, there will be no subscription fee until 2015.
- No. of circulation of paper journal:
  - Domestic (The Korean Medical Library Association, National Assembly Library, etc.) 730 copies,
  - Overseas (The Library; various regions in 18 countries) 90 copies.
- To subscribe to *Asian Spine Journal*, please contact the editorial office for detailed information ([spinepjb@catholic.ac.kr](mailto:spinepjb@catholic.ac.kr)).

## Electronic Edition

A free full-text service both in the XML and PDF formats is available at our home page (<http://www.asianspinejournal.com> or <http://www.asianspinejournal.org>). No registration or subscription is required for access to the electronic edition of *Asian Spine Journal*.

### ■ Executive Committee

Yung-Khee Chung, Jae-Yoon Chung, Chong-Suh Lee, Hak-Sun Kim, Jae Hwan Cho, Si-Young Park, Yong-Soo Choi, Arvind Jayaswal

### ■ Editorial Office

Correspondence for subscriptions, reprints, address changes, and advertisements should be sent to the address below:

Asian Spine Journal

Department of Orthopaedic Surgery, Asan Medical Center, University of Ulsan College of Medicine, Seoul, Korea,

88, Olympic-ro 43-gil, Songpa-gu, Seoul 05505, Korea

Tel: +82-2-3010-3549, Fax: +82-2-3010-8555, E-mail: [spinecjh@gmail.com](mailto:spinecjh@gmail.com)

### ■ Publisher Office

#### Korean Society of Spine Surgery

Department of Orthopaedic Surgery, Yonsei University College of Medicine, 50 Yonsei-ro, Seodaemun-gu, Seoul 03722, Korea

Tel: +82-2-831-3413, Fax: +82-2-831-3414, E-mail: [korspine@hanmail.net](mailto:korspine@hanmail.net)

### ■ Printing Office

Newest Medicine Company

Choisin B/D 27-11, Dongho-ro 24-gil, Jung-gu, Seoul 04617, Korea

Tel: +82-2-2263-4723, Fax: +82-2-2263-4726, E-mail: [newmedj115@gmail.com](mailto:newmedj115@gmail.com)

Asian Spine Journal is indexed/tracked/covered by PubMed, PubMed Central, KoreaMed, Synapse, KoMCI, CrossRef, Scopus, Google Scholar, and DOAJ.

## Editor-in-Chief

Hak-Sun Kim *Yonsei University, Orthopaedic Surgery, Korea*

## Editor-in-Chief Emeritus

Jae-Yoon Chung *Hyundae Hospital, Orthopaedic Surgery, Korea*

Chong-Suh Lee *Sungkyunkwan University, Orthopaedic Surgery, Korea*

## Deputy Editors

Jae Hwan Cho *Asan Medical Center, University of Ulsan, Orthopaedic Surgery, Korea*

Helton Luiz Aparecido Defino *University of São Paulo, Biomechanics, Brazil*

Ashish Diwan *St. George Hospital, Orthopaedic Surgery, Australia*

Mohamed Mohi Eldin *Cairo University, NeuroSurgery, Egypt*

Arvind Jayaswal *All India Institute Of Medical Sciences, Orthopaedic Surgery, India*

Han Jo Kim *Hospital for Special Surgery, Orthopaedic Surgery, USA*

Morio Matsumoto *Keio University, Orthopaedic Surgery, Japan*

S. Rajasekaran *Ganga Hospital, Orthopaedic Surgery, India*

Pierre Roussouly *Hospital of Massues, Orthopaedic Surgery, France*

Zhaomin Zheng *Sun Yat-Sen University, Orthopaedic Surgery, China*

## Publisher

Yong-Soo Choi *Kwangju Christian Hospital, Orthopaedic Surgery, Korea*

## Managing Editor

Sung Hoon Choi *Hanyang University, Orthopaedic Surgery, Korea*

## Public Relation Editor

Sam Yeol Chang *Seoul National University, Orthopaedic Surgery, Korea*

## Graphic Design Editor

Hae-Dong Jang *Soonchunhyang University, Orthopaedic Surgery, Korea*

## Ethics Editor

Sun Huh *Parasitology, Hallym University, Korea*

## Manuscript Editor

Hyun Joo Kim *InfoLumi, Korea*

## Editorial Board

Abdulaziz Al-Mutair *Alrazi Hospital, Orthopaedic Surgery, Kuwait*

Howard S An *Rush University, Orthopaedic Surgery, USA*

Mohd Hisam Muhamad Ariffin *National University of Malaysia, Orthopaedic Surgery, Malaysia*

Siddharth A. Badve *Hartsville Orthopedics and Sports Medicine, Orthopaedic Surgery, India*

Jong-Min Baik *Gachon University, Orthopaedic Surgery, Korea*

Aju Bosco *Tamil Nadu Govt. Multi Super Speciality Hospitals, Orthopaedic Surgery, India*

Rafael Bundoc *University of the Philippines, Orthopaedic Surgery, Philippines*

Rupinder Singh Chahal *Sir Ganga Ram Hospital, Orthopaedic Surgery, India*

Chris Yin Wei Chan *University of Malaya, Orthopaedic Surgery, Malaysia*

Ying Kei Chan *Canossa Hospital, Orthopaedic Surgery, Hong Kong*

Dong-Gune Chang *Inje University Orthopaedic Surgery, Korea*

Michael Chang *Sonoran Spine Research and Education Foundation, Orthopaedic Surgery, USA*

Jason Cheung *The Hong Kong University, Orthopaedic Surgery, Hong Kong*

Harvinder Singh Chhabra *Indian Spinal Injuries Centre, Orthopaedic Surgery, India*

Chee Kidd Chiu *University of Malaya, Orthopaedic Surgery, Malaysia*

Kyu-Jung Cho *Inha University, Orthopaedic Surgery, Korea*

Samuel Cho *The Mount Sinai Hospital, Orthopaedic Surgery, USA*

Woojin Cho *Albert Einstein College of Medicine, Orthopaedic Surgery, USA*

John Choi *The Avenue Hospital in Windsor, Orthopaedic Surgery, Australia*

Yong-Soo Choi *Kwangju Christian Hospital, Orthopaedic Surgery, Korea*

Bharat Dave *Stavya Spine Hospital & Research Institute, Orthopaedic Surgery, India*

Soundararajan Dilip *Ganga Hospital, Orthopaedic Surgery, India*

Abdel Hafiz Shehab Eldin *El-Sahel Teaching Hospital, Neurosurgery, Egypt*

David Essig *Northwell Health Orthopaedic Institute at Great Neck, Orthopaedic Surgery, USA*

Michael Faloon *Seton Hall University, Orthopaedic Surgery, USA*

Atul Goel *King Edward Memorial Hospital, Neurosurgery, India*

Yoon Ha *Yonsei University, Neurosurgery, Korea*

Yong Hai *Capital Medical University, Orthopaedic Surgery, China*

Mitchell Hansen *Lingard Private Hospital, Neurosurgery, Australia*

Jae-Young Hong *Korea University, Orthopaedic Surgery, Korea*

Seung-Jae Hyun *Seoul National University, Neurosurgery, Korea*

Jose Manuel Ignacio *University of the Philippines-Manila, Orthopedic Surgery, Philippines*

Soo-Bin Im *Soonchunhyang University, Neurosurgery, Korea*

Komang Irianto *Surabaya Medical University, Orthopaedic Surgery, Indonesia*

Yasuo Ito *Ise Red Cross Hospital, Orthopaedic Surgery, Japan*

Jose María Jimenez *Mexican Social Security Institute, Orthopaedic Surgery, Mexico*

Chang-Nam Kang *Hanyang University, Orthopaedic Surgery, Korea*

Rishi Kanna *Ganga Hospital, Orthopaedic Surgery, India*

# ASIAN SPINE JOURNAL

<b>Yoshiharu Kawaguchi</b>	<i>University of Toyama, Orthopaedic Surgery, Japan</i>	<b>Dae-Hyun Park</b>	<i>Inje University, Orthopaedic Surgery, Korea</i>
<b>Mamoru Kawakami</b>	<i>Wakayama Medical University Kihoku Hospital, Orthopaedic Surgery, Japan</i>	<b>Hyung-Youl Park</b>	<i>The Catholic University of Korea, Orthopaedic Surgery, Korea</i>
<b>Ankur Khandelwal</b>	<i>Sharda University School of Medical Sciences and Research, Anaesthesiology and Critical Care, India</i>	<b>Jin-Sung Park</b>	<i>Sungkyunkwan University, Orthopaedic Surgery, Korea</i>
<b>Kyung-Chung Kang</b>	<i>Kyung Hee University, Orthopaedic Surgery, Korea</i>	<b>Jong-Beom Park</b>	<i>The Catholic University of Korea, Orthopaedic Surgery, Korea</i>
<b>Chi Heon Kim</b>	<i>Seoul National University, Orthopaedic Surgery, Korea</i>	<b>Kun-Bo Park</b>	<i>Severance Children's Hospital, Pediatric Orthopaedics, Korea</i>
<b>Dae-Geun Kim</b>	<i>Soonchunhyang University, Orthopaedic Surgery, Korea</i>	<b>Sang-Min Park</b>	<i>Seoul National University, Orthopaedic Surgery, Korea</i>
<b>Ho-Joong Kim</b>	<i>Seoul National University, Orthopaedic Surgery, Korea</i>	<b>Sehan Park</b>	<i>Dongguk University, Orthopaedic surgery, Korea</i>
<b>Hyeun Sung Kim</b>	<i>Nanoori Hospital, Neurosurgery, Korea</i>	<b>Se-Jun Park</b>	<i>Sungkyunkwan University, Orthopaedic Surgery, Korea</i>
<b>Keung Nyun Kim</b>	<i>Yonsei University, Neurosurgery, Korea</i>	<b>Jiwon Park</b>	<i>Korea University, Orthopaedic Surgery, Korea</i>
<b>Sang Il Kim</b>	<i>The Catholic University of Korea, Orthopaedic Surgery, Korea</i>	<b>Odysseas Paxinos</b>	<i>Hellenic Air Force, Orthopaedic Surgery, Greece</i>
<b>Sang Jun Kim</b>	<i>Sungkyunkwan University, Rehabilitation, Korea</i>	<b>Rabindra L. Pradhan</b>	<i>Kathmandu Medical College, Orthopaedic Surgery, Nepal</i>
<b>Sung-Kyu Kim</b>	<i>Chonnam National University, Orthopaedic Surgery, Korea</i>	<b>Yong Qiu</b>	<i>Nanjing University Drum Tower Hospital, Orthopaedic Surgery, China</i>
<b>Sung-Soo Kim</b>	<i>Inje University, Orthopaedic Surgery, Korea</i>	<b>Moshiur Rahman</b>	<i>Holy Family Red Crescent Medical College, Neurosurgery, Bangladesh</i>
<b>Tae-Hwan Kim</b>	<i>Hallym University, Orthopaedic Surgery, Korea</i>	<b>Alejandro Reyes-Sánchez</b>	<i>National Institute of Rehabilitation, Spinal Surgery, Mexico</i>
<b>Yong-Chan Kim</b>	<i>Kyung Hee University, Orthopaedic Surgery, Korea</i>	<b>Kee-Won Rhyu</b>	<i>The Catholic University of Korea, Orthopaedic Surgery, Korea</i>
<b>Young-Yul Kim</b>	<i>The Catholic University of Korea, Orthopaedic Surgery, Korea</i>	<b>Yohan Robinson</b>	<i>Armed Forces Centre for Defense Medicine, Spine Surgery, Sweden</i>
<b>Arvind Kulkarni</b>	<i>Breach Candy Hospital, Orthopaedic Surgery, India</i>	<b>Daisuke Sakai</b>	<i>Tokai University, Orthopaedic Surgery, Japan</i>
<b>Naresh Kumar</b>	<i>National University of Singapore, Orthopaedic Surgery, Singapore</i>	<b>Salman Sharif</b>	<i>Liaquat National Hospital and Medical College, Neurosurgery, Pakistan</i>
<b>Mun Keong Kwan</b>	<i>University of Malaya, Orthopaedic Surgery, Malaysia</i>	<b>Sang Yun Seok</b>	<i>Eulji University, Orthopaedic Surgery, Korea</i>
<b>Ji-Won Kwon</b>	<i>National Health Insurance Service Ilsan Hospital, Orthopedic surgery, Korea</i>	<b>Ajoy Shetty</b>	<i>Ganga Hospital, Orthopaedic Surgery, India</i>
<b>Aron Lazary</b>	<i>Semmelweis University, Department of Spine Surgery, Hungary</i>	<b>Anuj Singla</b>	<i>University of Virginia, Orthopaedic Surgery, USA</i>
<b>Byung Ho Lee</b>	<i>Yonsei University, Orthopaedic Surgery, Korea</i>	<b>K S Sivananthan</b>	<i>Fatimah Hospital, Orthopaedic Surgery, Malaysia</i>
<b>Hyung Rae Lee</b>	<i>Uijeongbu Eulji Medical Center, Orthopaedic Surgery, Korea</i>	<b>Gbolabo Sokunbi</b>	<i>St. Luke's University, Orthopaedic Surgery, USA</i>
<b>Gun Woo Lee</b>	<i>Youngnam University, Orthopaedic Surgery, Korea</i>	<b>Kwang-Sup Song</b>	<i>Chung-Ang University, Orthopaedic Surgery, Korea</i>
<b>Jae-Chul Lee</b>	<i>Soonchunhyang University, Orthopaedic Surgery, Korea</i>	<b>Masatoshi Sumi</b>	<i>Kobe Rosai Hospital, Orthopaedic Surgery, Japan</i>
<b>Jeongik Lee</b>	<i>Chung-Ang University, Orthopaedic Surgery, Korea</i>	<b>Yu Sun</b>	<i>Peiking University Third Hospital, Orthopaedic Surgery, China</i>
<b>Jung Hwan Lee</b>	<i>Namdarun Rehabilitation Clinic, Korea</i>	<b>Sahyun Sung</b>	<i>Ewha Womans University Seoul Hospital, Orthopaedic Surgery, Korea</i>
<b>Jung-Kil Lee</b>	<i>Chonnam National University, Neurosurgery, Korea</i>	<b>Toshiyuki Takahashi</b>	<i>Fujieda Heisei Memorial Hospital, Neurosurgery, Japan</i>
<b>Seung Hwan Lee</b>	<i>Master Yonsei Orthopaedic Clinic, Korea</i>	<b>Gamaliel Tan</b>	<i>Ng Teng Fong General Hospital, Orthopaedic Surgery, Singapore</i>
<b>Soo-Bin Lee</b>	<i>Catholic Kwandong University Int'l St.Mary's Hospital, Orthopaedic Surgery, Korea</i>	<b>Nobuhiro Tanaka</b>	<i>Hiroshima University, Orthopaedic Surgery, Japan</i>
<b>Ka Kin Li</b>	<i>The Hong Kong University, Orthopaedic Surgery, Hong Kong</i>	<b>Rushama Tandon</b>	<i>Northern Railway Central Hospital, Orthopaedic Surgery, India</i>
<b>Kang Taek Lim</b>	<i>Good Doctor Teun Teun Hospital, Neurosurgery, Korea</i>	<b>Warayos Trathitephun</b>	<i>Chulabhorn hospital, Orthopedic surgery, Thailand</i>
<b>Gabriel Liu</b>	<i>National University of Singapore, Orthopaedic Surgery, Singapore</i>	<b>Nishu Tyagi</b>	<i>Indian Spinal Injuries Centre, Rehabilitation and Telehealth, India</i>
<b>Keith DK Luk</b>	<i>The Hong Kong University, Orthopaedic Surgery, Hong Kong</i>	<b>Shih-Tien Wang</b>	<i>National Yang Ming University, Orthopaedic Surgery, Taiwan</i>
<b>Hisanori Mihara</b>	<i>South Yokohama Mutual Aid Hospital, Orthopaedic Surgery, Japan</i>	<b>Hee Kit Wong</b>	<i>National University of Singapore, Orthopaedic Surgery, Singapore</i>
<b>Raghava Dutt Mulukutla</b>	<i>Udai Omni Hospital, Orthopaedic Surgery, India</i>	<b>Hiroshi Yamada</b>	<i>Wakayama Medical University, Orthopaedic Surgery, Japan</i>
<b>Abhay Nene</b>	<i>Hinduja Hospital, Orthopaedic Surgery, India</i>	<b>Wai-Mun Yue</b>	<i>Gleneagles Hospital, Orthopaedic Surgery, Singapore</i>
<b>Zairin Noor</b>	<i>Lambung Mangkurat University, Orthopaedic Surgery, Indonesia</i>	<b>Yasutsugu Yukawa</b>	<i>Wakayama Medical University, Orthopaedic Surgery, Japan</i>
<b>Ahmad Ozair</b>	<i>King George's Medical University, India</i>	<b>Hao Zhang</b>	<i>Chinese PLA General Hospital, Orthopaedic Surgery, China</i>
<b>Orso Lorenzo Osti</b>	<i>University of Adelaide, Orthopaedic Surgery, Australia</i>	<b>Zezhang Zhu</b>	<i>Nanjing University Drum Tower Hospital, Orthopaedic Surgery, China</i>
<b>Hiroshi Ozawa</b>	<i>Tohoku Medical and Pharmaceutical University, Orthopaedic Surgery, Japan</i>	<b>Mehmet Zileli</b>	<i>Ege University, Neurosurgery, Turkey</i>



---

## Abstracts for Medal Papers Basic Science Papers

---

- |                           |   |   |
|---------------------------|---|---|
| <b>Basic Science-243</b>  | Dural Repair: Efficacy Assessment of Different Techniques: A Cadaveric Study Comparing the Naked Eyes and Surgical Loupes<br>Roongrath Chitragran   | 1 |
| <b>Basic Science-483</b>  | The Electromyographic Discrepancy of Paravertebral Muscles Predicts an Early Curve Progression of Untreated Adolescent Idiopathic Scoliosis<br>Jason Pui Yin Cheung                           | 2 |
| <b>Basic Science-641</b>  | Analysis of the Cement Distribution Pattern and Other Risk Factors That Affect the Incidence of Recompresion Fractures of Vertebral Bodies after Vertebroplasty or Kyphoplasty<br>Minkyu Shin | 2 |
| <b>Basic Science-891</b>  | Core Planar Cell Polarity Genes VANGL1 and VANGL2 in Predisposition to Congenital Scoliosis<br>Jason Pui Yin Cheung   | 3 |
| <b>Basic Science-1630</b> | Molecular Interactions between Intervertebral Disc Host Proteins and Putative Pathogenic Effector Proteins in Degenerate Discs: A Predictive Insilico Analysis<br>Shanmuganathan Rajasekaran  | 4 |

---

## Abstracts for Medal Papers Clinical Award Papers

---

- |                            |  |    |
|----------------------------|--|----|
| <b>Clinical Award-314</b>  | Computer-Assisted Diagnosis with Artificial Neural Networks for Odontoid Fracture Detection<br>Wongthawat Liawrungrueang   | 5  |
| <b>Clinical Award-434</b>  | Conservative Treatment of Atlantoaxial Rotatory Fixation<br>Yusuke Oshita  | 5  |
| <b>Clinical Award-463</b>  | Long-term Outcomes of Vertebral Body Sliding Osteotomy for the Treatment of Cervical Myelopathy: A Minimum of 5-Year Follow-up<br>Sung Tan Cho   | 6  |
| <b>Clinical Award-528</b>  | Establishing a Relationship Using Computed Tomography between Facet Distraction and Clinical Outcomes after Anterior Cervical Discectomy and Fusion<br>Jooyoung Lee  | 7  |
| <b>Clinical Award-822</b>  | Anterior Column Realignment through Open Preposterior Release-Anterior-Posterior Fusion versus Hybrid Minimally Invasive Anterior-Posterior Fusion for Dynamic Sagittal Imbalance of the Spine<br>Joonghyun Ahn                          | 8  |
| <b>Clinical Award-984</b>  | The Criteria of Severe Dynamic Sagittal Imbalance in Adult Spinal Deformity and Its Importance<br>Sung Min Kim   | 9  |
| <b>Clinical Award-1137</b> | Mechanical Complications and Global Alignment and Proportion Score after Limited Long-Segment Fusion for De Novo Adult Spinal Deformity: Comparison of Lateral Lumbar Interbody Fusion and Three-Column Osteotomies<br>Hiroshi Moridaira | 10 |

- Clinical Award-1194** Atlas Osteosynthesis Screw Placement Using the Intersection between Lateral Mass and Inferomedial Edge of the Atlas Posterior Arch: Human Cadaveric Study **10**  
Torphong Bunmaprasert
- Clinical Award-1329** Is Anterior-Only Approach a Reliable Surgical Strategy in Ankylosing Spondylitis Patients with Cervical Spine Fractures **11**  
Ajoy Prasad Shetty
- Clinical Award-1339** Curve Flexibility Assessment in Adolescent Idiopathic Scoliosis with Major Main Thoracic Curve: Comparison and Correlation between Physician-Supervised Supine Side Bending Radiographs versus Supine Computed Tomography Scan **12**  
Josephine Rebecca Chandren
- Clinical Award-1345** Reducing Surgical Site Infections after Spine Surgery: The Optimal Amount of Normal Saline for Intra-Wound Irrigation **12**  
Shih-Tien Wang
- Clinical Award-1422** Subcrestal Iliac Screw Technique as an Alternative for Spinopelvic Fixation Technique: A Cohort Study of 73 Patients with a Modified Low Profile, Free Hand Technique for Insertion of Subcrestal Iliac Screw **13**  
Glenys Poon
- Clinical Award-1637** The 'Disc-EndPlate-Bone-Marrow Complex' Classification: A Paradigm Shift in Our Understanding of the Modic Vertebral Endplate Changes **14**  
Shanmuganathan Rajasekaran
- Clinical Award-1651** Efficacy of Vacuum-Assisted Closure in Postoperative Deep Spinal Infections: A Retrospective Analysis of 31 Patients with Spinal Instrumentation **15**  
Shanmuganathan Rajasekaran
- Clinical Award-1769** The Infection Control and Spinal Balance in Patients Receiving Percutaneous Endoscopic Debridement and Drainage for Infectious Discitis: A Retrospective Case Analysis **15**  
Hao-Wen Chen
- 

## Course Abstracts for Free

---

- Abstracts Free-028** Effectiveness of Sublaminar Mersilene Tape-Augmented Pedicle Screws Fixation for Osteoporotic Vertebral Compression Fracture: Low-Cost Modality **16**  
Ghanshyam Kakadiya
- Abstracts Free-033** Burden of Cervical Spinal Injury in India: The Untold Story **17**  
Deepak Agrawal
- Abstracts Free-181** Remodeling of Facet Joint after Posterior Endoscopic Cervical Foraminotomy: Computer Tomographic Facet Dimension Analysis and Clinical Evaluation with Minimum 1-Year Follow-up **17**  
Pang Hung Wu
- Abstracts Free-293** Sarcopenia in Paraspinal Muscle as a Risk Factor of Proximal Junctional Kyphosis and Proximal Junctional Failure after Adult Spinal Deformity Surgery **18**  
Jin Seong Park



# ASIAN SPINE JOURNAL

www.asianspinejournal.org

pISSN 1976-1902 · eISSN 1976-7846

Volume 17 · Number Supplement 1 · May 2023

---

- Abstracts Free-363** Effects of Teriparatide Alone versus Percutaneous Vertebroplasty on Pain Control and Radiographic Outcomes after Osteoporotic Vertebral Compression Fracture: A Matched Cohort Study **18**  
Po-An Chen
- Abstracts Free-364** Comparison of Proximal and Distal Junctional Failures after Long Fusion Arthrodesis Stopping at L5: Incidences and Risk Factors **19**  
Sang-Il Kim
- Abstracts Free-366** Clinical and Radiographic Outcomes of Late-Onset Cage Subsidence after Lateral Lumbar Interbody Fusion **20**  
Sang-Il Kim
- Abstracts Free-377** Functional Recovery Priorities and Community Rehabilitation Service Preferences of Spinal Cord Injury Individuals and Caregivers of Chinese Ethnicity and Cultural Background **20**  
Paul Koljonen
- Abstracts Free-414** Change in Physical and Mental Well-Being between the Short- and Mid-Term Periods after Cervical Surgery for Myelopathy: A Retrospective Cohort Study with Minimum 5-Year Follow-up **21**  
Koji Tamai
- Abstracts Free-421** Risk Factors for Conversion to Open Spinal Surgery after Percutaneous Epidural Neuroplasty **21**  
Hyung-Youl Park
- Abstracts Free-422** Effect of Lumbar Spinal Stenosis on Treatment of Osteoporosis: Comparison of Three Oral Bisphosphonate Therapies **22**  
Hyung-Youl Park
- Abstracts Free-479** Surgical Complications and Incomplete Canal Widening of the Vertebral Body Sliding Osteotomy to Treat Cervical Myelopathy **22**  
Sung Tan Cho
- Abstracts Free-482** Curve Overcorrection Predicts Coronal Imbalance in Selective Thoracic Fusion in Adolescent Idiopathic Scoliosis **23**  
Jason Pui Yin Cheung
- Abstracts Free-485** The Relationship between Compliance of Physiotherapeutic Scoliosis-Specific Exercises and Curve Regression with Mild to Moderate Adolescent Idiopathic Scoliosis **24**  
Jason Pui Yin Cheung
- Abstracts Free-486** Directed versus Non-directed Standing Postures in Adolescent Idiopathic Scoliosis: Its Impact on Curve Magnitude, Alignment, and Clinical Decision Making **25**  
Jason Pui Yin Cheung
- Abstracts Free-487** Randomized Controlled Trial Comparing Immediate versus Gradual Brace Weaning for Adolescent Idiopathic Scoliosis **26**  
Jason Pui Yin Cheung
- Abstracts Free-491** Male Patients with Longer Disease Duration of Axial Spondyloarthritis Have Less Severe Disc Degeneration **27**  
Jason Pui Yin Cheung
- Abstracts Free-501** The Triangular Osteosynthesis for Traumatic Spinopelvic Instability: A Consecutive Series **28**  
Luong Minh Quang
- Abstracts Free-503** The Analysis of Treatment Failure Candidate after Preoperative Radiotherapy for Metastatic Spinal Tumor **29**  
Sang Yun Seok

- Abstracts Free-507** Comparison between the Bone Union Rates Using Auto-Iliac Bone and Bone Morphogenetic Protein without Auto Bone in a Posterior Atlantoaxial Fusion Procedure: Results from a Minimum 1-Year Follow-up **29**  
Sang Yun Seok
- Abstracts Free-533** Radiographic Analysis of Early Changes in Upper Adjacent Segments after Fusion Surgery: Oblique Lumbar Interbody Fusion versus Posterior Lumbar Interbody Fusion **30**  
Joo Young Lee
- Abstracts Free-553** Minimally Invasive Spine Surgery: Techniques, Technologies, and Indications for Thoracolumbar Spine Fracture **32**  
Sarwar Jahan
- Abstracts Free-591** Feasibility of Lateral Mass Screw Insertion in the Risky Triad of C1: Comparison of the Over the Arch Technique to the Conventional Techniques **33**  
Hyung Rae Lee
- Abstracts Free-593** Predictive Factors for the Aggravation of Cervical Alignment after Posterior Cervical Foraminotomy **33**  
Hyung Rae Lee
- Abstracts Free-618** Retrospective Comparative Study of Anterior Cervical Decompression and Fusion and Muscle-Preserving Selective Laminectomy in Patients with Degenerative Cervical Myelopathy **35**  
Kazuya Kitamura
- Abstracts Free-638** Predictive Equations for Cervical Lordosis and T1 Slope of Young Adult Population without Any Neck Symptoms: Analysis of 171 Radiographs **35**  
Shankar Acharya
- Abstracts Free-873** High Grade Spondylolisthesis: Reduction versus in Situ Fusion for Adult **36**  
Mohammad Mahbubur Rahman Khan
- Abstracts Free-899** A Comparison between Cortical Bone Trajectory Screws and Traditional Pedicle Screws in Patients with Single-Level Lumbar Degenerative Spondylolisthesis: 5-Year Results **36**  
Sungryul Choi
- Abstracts Free-985** Surgical Strategy-Oriented Classification for the Patients with Severe Dynamic Sagittal Imbalance **37**  
Sung Min Kim
- Abstracts Free-1011** Do Intraoperative Neurophysiological Changes Predict Functional Outcomes Following Decompressive Surgery for Cervical Myeloradiculopathy? A Prospective Study **38**  
Keyur Akbari
- Abstracts Free-1036** Epidemiological Characteristics and Factors of Early Mortality for Traumatic Cervical Spinal Cord Injury with Radiographic Abnormality: A Multicenter Nationwide Cohort Study **38**  
Kyota Kitagawa
- Abstracts Free-1060** A Risk Quantification Reference Table for Progressed Adolescent Idiopathic Scoliosis Surgery: An Exact Case Matched Outcomes Analysis **39**  
Jun-Hao Tan
- Abstracts Free-1069** Efficacy, Safety, and Reliability of Single Posterior Approach for Unstable Thoracolumbar Burst Fracture Treated with Anterior Reconstruction and Posterior Instrumentation **39**  
Sharif Ahmed Jonayed

<b>Abstracts Free-1086</b>	Correlations between Age, Pain Intensity, Disability, and Tactile Acuity in Patients with Chronic Low Back Pain Kangyong Zheng	40
<b>Abstracts Free-1117</b>	Can We Predict the Outcome after Direct Repair for Lumbar Pars Defect Ganesan Sudhir	41
<b>Abstracts Free-1126</b>	Standalone Cage Versus Anchored Cage for Anterior Cervical Discectomy and Fusion: A Comparative Analysis of Clinical and Radiological Outcomes Ujjwal Kanti Debnath	41
<b>Abstracts Free-1187</b>	Central Sensitization Is a Significant Risk Factor for the Chronic Low Back Pain Hiroshi Hashizume	42
<b>Abstracts Free-1201</b>	Multicenter Validation of Using the Distal Radius and Ulna Classification to Predict Scoliosis Progression: APSS Scoliosis Focus Group Study Hideyuki Arima	42
<b>Abstracts Free-1203</b>	A Comparative Factor Analysis and New Magnetic Resonance Imaging Scoring System for Differentiating Pyogenic versus Tuberculous Spondylodiscitis Patchara Pornsapanakorn	43
<b>Abstracts Free-1212</b>	Non-surgical Management of Flexion Distraction Type of Spinal Column Injuries, Institutional Preview Shamim Ahmad Bhat	44
<b>Abstracts Free-1223</b>	The Alternation of Junctional Levels after Decompression and Alignment Correction for Cervical Kyphotic Deformity-Induced Multilevel Cervical Myelopathy: A Retrospective Case Analysis Hao-Wen Chen	44
<b>Abstracts Free-1279</b>	Comparison of Surgical Outcomes between three-Column Osteotomy and Anterior-Posterior Fusion for Osteoporotic Vertebral Fracture Shinji Takahashi	45
<b>Abstracts Free-1284</b>	Predictors of Neurological Outcome of Acute Traumatic Central Cord Syndrome: Outcome of a Treatment Algorithm Verma Vishal	45
<b>Abstracts Free-1287</b>	Comparison of Three Different Instrumentation Constructs in a Prospective Cohort of Thoracolumbar Burst Fractures: Does Interbody Fusion Offers Any Advantage over Fractured Level Instrumentatio Bhaskar Sarkar	46
<b>Abstracts Free-1293</b>	The Surgical Results of Onstage of Laminoplasty and Anterior Cervical Fusion for the Patients with Multilevel Cervical Spondylotic Myelopathy: Postoperative 8-Year Follow-up Wen-Tien Wu	47
<b>Abstracts Free-1306</b>	The Impact on Spinal Deformity Progression among Pediatric Patients with SMA Treated with Nusinersen Kenny Yat Hong Kwan	48
<b>Abstracts Free-1314</b>	How Paraspinal Atrophy Affects Pain and Function in Degenerative Spinal Conditions? An Analytical Study on Degenerative Disc Disease without Instability and in Spondylolisthesis Sudarshan Pramod	48
<b>Abstracts Free-1342</b>	Fusion Block Tilt following Corrective Surgery in Lenke 5 Adolescent Idiopathic Scoliosis Weng Hong Chung	49

- Abstracts Free-1343** Validation of the Predictive Formula for Optimal Upper Instrumented Vertebra Tilt Angle (Based on Preoperative Erect Radiograph) in Adolescent Idiopathic Scoliosis: A Comparison with the Calculated Optimal Upper Instrumented Vertebra Tilt Angle Derived from the Supervised Supine Side Bending Films **49**  
Weng Hong Chung
- Abstracts Free-1347** Comparison of Perioperative Outcomes among Adolescent Idiopathic Scoliosis Patients Operated by a Dedicated Spine Team Approach: Were There Any Differences between the First, Second, and the Last Case? **50**  
Sin Ying Lee
- Abstracts Free-1349** A Dedicated Spine Team Approach Optimized the Efficiency of Operating Theatre Utilization While Maintaining a Standard Patient Care in Adolescent Idiopathic Scoliosis Surgery **51**  
Sin Ying Lee
- Abstracts Free-1356** Hip-Spine Syndrome: Which First and Which Last Longer? **52**  
Shih-Tien Wang
- Abstracts Free-1390** Perception of Spinal Deformity among Patients with Adolescent Idiopathic Scoliosis **53**  
Matthew Song Peng Ng
- Abstracts Free-1405** Assessment of Biomechanical Advantages in Combined Anterior-Posterior Cervical Spine Surgery by Radiologic Outcomes: Pedicle Screw over Lateral Mass Screw **54**  
Sang-Ho Kim
- Abstracts Free-1408** Difference of Postoperative Radiologic Change on Sacro-Iliac joint by Multi-factors in Adolescent Idiopathic Scoliosis **54**  
Sang-Ho Kim
- Abstracts Free-1420** Comparison of the Assessment of Sanders Skeletal Maturity Using Single Low Radiation Dose EOS Spine Hand Radiography and Conventional Hand Radiography **55**  
Glenys Poon
- Abstracts Free-1446** Erector Spinae Atrophy/Fatty Infiltration Is a Risk Factor for the Development of Adult Spinal Deformity: Results of a 6-Year Followup of a Large Cohort of Residents **55**  
Keiji Nagata
- Abstracts Free-1578** Total *En-Bloc* Spondylectomy versus Stereotactic Ablative Body Radiotherapy in Patients with Single Spinal Metastasis **56**  
Dong-Ho Kang
- Abstracts Free-1647** The Risk of Injury to the Internal Carotid Artery during C1 Lateral Mass Screw Fixation **57**  
Ryo Kitagawa
- Abstracts Free-1663** What Makes Them Stay? A Study on Effects of Socioeconomic Indicators on Length of Stay and Postoperative Rehabilitation Following Minimally Invasive Transforaminal Lumbar Interbody Fusion **58**  
Ramkumar Mohan
- Abstracts Free-1673** The Surgical Management for Thoracic and Lumbar Spinal Tuberculosis: The One-Stage Surgery Combined Anterior and Posterior Approaches in Lateral Position of the Patient **59**  
Thanh Vo
- Abstracts Free-1818** Treatment of Chronic Spinal Cord Injury: Is There Any Hope? **60**  
Muhammad Jawad Saleem

- 
- Abstracts Free-1823** Paradoxical Worsening on Imaging in the Early Treatment Course of Tuberculous Spondylodiscitis: Should It Be a Concern? **61**  
J. Naresh-Babu
- Abstracts Free-1896** The Role of Single-Photon Emission Computed Tomography/Computed Tomography in Analyzing the Radiographic Prevalence of Asymptomatic Degenerative Spondylosis in a Consecutive Cohort of Patients Presenting with Cancer **61**  
Atharv Patankar

---

## Abstracts for Medal Papers E-Poster Papers

---

- E-Posters Award-030** Predictors of Cerebrospinal Fluid Leak Following Dural Repair in Spinal Intradural Surgery: Surgical Indications and Dural Repair Techniques **62**  
Lei Jiang
- E-Posters Award-178** Factors Affecting the Prognosis of Recovery of Motor Power and Ambulatory Function after Surgery for Metastatic Epidural Spinal Cord Compression **63**  
Sehan Park
- E-Posters Award-256** A Comparative Factor Analysis of Spinal Infection in Adults: Pyogenic versus Tuberculous Spondylodiscitis **64**  
Patchara Pornsopanakorn
- E-Posters Award-652** Antiplatelet Therapy Does Not Prolong Length of Stay Following Anterior Cervical Discectomy and Fusion **64**  
Beatrice Tan
- E-Posters Award-719** Morphological Evaluation of the Lumbar Curve in Adolescent Idiopathic Scoliosis Lenke Type 1 **65**  
Yuichi Shimizu
- E-Posters Award-801** Can Thoracic Inlet Angle Be Used as a Substitute for T1 Slope? **66**  
Kenta Takakura
- E-Posters Award-827** An Analysis of 49 Cases with Pedicle Fractures of the C2 Axis: Is Surgery Necessary? **67**  
Sung Kyu Kim
- E-Posters Award-1112** Comparative Analysis between Supine Manual Traction Radiographs with Bending Radiographs in Adolescent Idiopathic Scoliosis **67**  
Subramaniam Macherla Haribabu
- E-Posters Award-1182** Comparative Study of Anterior and Posterior Combined Surgery with Lateral Lumbar Interbody Fusion versus Vertebral Body Replacement for Osteoporotic Vertebral Burst Fractures **68**  
Kazuo Doi
- E-Posters Award-1733** Single-Level Endoscopic Transforaminal Lumbar Interbody Fusion Achieves Similar 1-Year Clinical and Radiological Outcomes Compared to Conventional Minimally Invasive Transforaminal Lumbar Interbody Fusion with Reduced Surgery Duration, Blood Loss, and Length of Hospital Stay **69**  
David Shaoen Sim

## Abstracts for E-Posters

- |                      |   |    |
|----------------------|---|----|
| <b>E-Posters-154</b> | Extensive Thoracic and Lumbar Spine Actinomycosis in an Immunocompetent Patient Causing Paraparesis: A Case Report<br>Sagar Kishor Kokate   | 70 |
| <b>E-Posters-168</b> | Etiologies of Early Reoperation after Unilateral Biportal Endoscopic Spine Surgery<br>Hanjin Jang   | 70 |
| <b>E-Posters-253</b> | Association Factor for Surgical Site Infection in Spine Instrumentation Surgery<br>Shinji Tanishima   | 71 |
| <b>E-Posters-268</b> | Long-term Outcome of Surgery for Ossification of the Posterior Longitudinal Ligament<br>Yoshiharu Kawaguchi   | 71 |
| <b>E-Posters-271</b> | Comparison of Percutaneous Endoscopic Surgery to Treat Infectious Spondylodiscitis with or without Spinal Epidural Abscess: A Retrospective Study and Literature Reviews<br>Chiayu Lin                                  | 72 |
| <b>E-Posters-290</b> | Characteristics of L1 Slope in Thoracolumbar Sagittal Parameters of Degenerative Spondylosis<br>Yongsoo Choi  | 73 |
| <b>E-Posters-315</b> | Clinical Outcome of Intra-Articular Lumbar Facet Joint Steroid Injection in Patients with Lumbar Facet Joints Arthropathy<br>Li Loong Loh   | 73 |
| <b>E-Posters-334</b> | The Feasibility and Efficacy of Computer-Assisted Screw Inserting Planning in the Surgical Treatment for Severe Spinal Deformity: A Prospective Study<br>Yong Hai   | 74 |
| <b>E-Posters-338</b> | Halo-Pelvic Traction Combine with Staged Posterior Correction for Severe Rigid Kyphoscoliosis of More Than 140 Degrees<br>Yong Hai  | 75 |
| <b>E-Posters-363</b> | Effects of Teriparatide Alone versus Percutaneous Vertebroplasty on Pain Control and Radiographic Outcomes after Osteoporotic Vertebral Compression Fracture: A Matched Cohort Study<br>Po-An Chen                      | 75 |
| <b>E-Posters-370</b> | Concomitant Atlantoaxial and Atlanto-Occipital Rotatory Dislocation in Children: Radiological Features, Diagnostic Pitfalls, and Long-term Outcome<br>Paul Koljonen   | 76 |
| <b>E-Posters-373</b> | Knowledge Gaps in Biophysical Changes after Powered Robotic Exoskeleton Walking by Individuals with Spinal Cord Injury: A Scoping Review<br>Paul Koljonen   | 76 |
| <b>E-Posters-374</b> | Length of Cervical Stenosis, Admission American Spinal Cord Injury Association Motor Scores, and Brain and Spinal Injury Center Scores Are Predictors of Recovery Rate Following Central Cord Syndrome<br>Paul Koljonen | 77 |

- E-Posters-385** Outcome Analysis of Anterior-Only Fixation for Three-Column Injury of the Sub-Axial Cervical Spine without Neurologic Deficit: Series of 16 Cases with Minimum 1-Year Follow-up **78**  
Bhaskar Sarkar
- E-Posters-392** Spinopelvic Sagittal Parameters and Persistent Symptom after Transforaminal Lumbar Interbody Fusion in Lumbar Degenerative Disc Disease **78**  
Ghanshyam Kakadiya
- E-Posters-426** Should Pedicle Subtraction Osteotomy Be Always Needed for Iatrogenic Flat Back Syndrome?: Comparison between Lateral Lumbar Interbody Fusion and Pedicle Subtraction Osteotomy **79**  
Hyung-Youl Park
- E-Posters-428** The Important Perioperative Predictor for Survival Rate Following Surgical Treatment for Metastatic Spine **80**  
Sung Tan Cho
- E-Posters-457** Movement of the Sacroiliac Joint: A Cadaver Study **81**  
Dai-Soon Kwak
- E-Posters-475** Anterior Retropharyngeal Approach to the Upper Cervical Spine: A Corridor Familiar to the Spine Surgeon **82**  
Yuvaraja Murugan
- E-Posters-481** Biomechanical Analysis of Long-Segment Posterior Pedicle Screw Fixation (+One Fracture Vertebrae) versus Short-Segment Posterior Pedicle Screw Fixation (+One Fracture Vertebrae) for Unstable Burst Fractures in Thoracolumbar Junction in the National Institute of Traumatology and Orthopaedics Rehabilitation: Our Experience in COVID-19 Pandemic Time **82**  
Dibakar Sarkar
- E-Posters-489** Why Are Some Intervertebral Discs More Prone to Degeneration? Insights into Isolated Thoracic 'Dysgeneration' **83**  
Jason Pui Yin Cheung
- E-Posters-490** Impact on Patient-Perceived Quality of Life between Chronic Non-specific Low Back Pain and Axial Spondyloarthritis: Propensity-Matched Comparison **83**  
Jason Pui Yin Cheung
- E-Posters-496** Separation Surgery Followed by Stereotactic Ablative Radiotherapy for Metastatic Epidural Spinal Cord Compression: A Systematic Review and Meta-Analysis for Local Progression Rate **84**  
Jason Pui Yin Cheung
- E-Posters-505** Atrophy of the Posterior Cricarytenoid Muscle as an Indicator of a Recurrent Laryngeal Nerve Injury History Before Revision Anterior Cervical Surgery **85**  
Sang Yun Seok
- E-Posters-529** Efficacy and Safety of Oblique Posterior Endplate Resection for Wider Decompression (Trumpet-Shaped Decompression) during Anterior Cervical Discectomy and Fusion **85**  
Sehan Park
- E-Posters-543** Surgical Management of Adult High-Grade Spondylolisthesis: How I do It **86**  
Md Kamrul Ahsan
- E-Posters-570** The Surgical Management for Subaxial Instability by Posterior Correction Fixation in Using the Cervical Pedicle Screw Method-New Method at Can Tho Central General Hospital **86**  
Huynh Thong Em

# ASIAN SPINE JOURNAL

www.asianspinejournal.org

pISSN 1976-1902 · eISSN 1976-7846

Volume 17 · Number Supplement 1 · May 2023

<b>E-Posters-573</b>	Difficulty in Head Control and Horizontal Gaze Caused by Cervical Spinal Imbalance after Neuromuscular Scoliosis Correction Surgery: Chin-To-Sky Deformity Dong-Ho Kang	<b>87</b>
<b>E-Posters-598</b>	Surgery of Complex Pediatric Spinal Deformity: Where Intraoperative Neurodeficit Is an Issue Anowarul Islam	<b>88</b>
<b>E-Posters-603</b>	Effect of Osteoporosis on the Clinical and Radiological Outcomes Following One-Level Anterior Cervical Discectomy and Fusion with Plating Chul Gie Hong	<b>89</b>
<b>E-Posters-637</b>	Evaluation of Radiation Exposure during Minimally Invasive Spine Surgery: How High Is the Exposure Dose? A Cadaveric Study Kazuta Yamashita	<b>89</b>
<b>E-Posters-730</b>	How Helpful Is the Halo Gravity Traction in Severe Spinal Deformity Patients: A Systematic Review and Meta-analysis Jianqiang Wang	<b>90</b>
<b>E-Posters-747</b>	Diagnostic Accuracy of Motor Evoked Potentials to Detect Neurological Deficit during Scoliosis Correction: A Case Series in Bangladesh Shah Alam	<b>91</b>
<b>E-Posters-748</b>	Risk Factors of Early Revision Surgery for Adjacent Segment Disease in Comparison with Late Revision Surgery after Lumbar Fusion Surgery Jeong-Seok Kim	<b>91</b>
<b>E-Posters-753</b>	Clinical and Radiological Findings of Foraminal Disc Herniation Jong-Won Kim	<b>92</b>
<b>E-Posters-760</b>	Hinged Roof Reconstruction of Anterior Iliac Crest after Harvesting Bicortical Strut Graft for Anterior Cervical Fusion Myoung Yeol Shin	<b>93</b>
<b>E-Posters-771</b>	Relationships between Clinical Status and Gait Parameters in Ankylosing Spondylitis Tae Sik Goh	<b>93</b>
<b>E-Posters-780</b>	Primary Spinal Tumors Treated in a Tertiary Hospital in Nepal: Case Series Rohit Pokharel	<b>94</b>
<b>E-Posters-820</b>	Clinical Results of Primary Sacral Tumors Hitoshi Tonomura	<b>94</b>
<b>E-Posters-823</b>	Analysis of Risk Factors Associated with Proximal Junctional Kyphosis Following Long-Instrumented Fusion from L1 to Sacrum Joonghyun Ahn	<b>95</b>
<b>E-Posters-826</b>	Anterior Cervical Debridement and Fusion for Cervical Pyogenic Spondylodiscitis: Is Use of Anterior Cervical Plating Possible? Sung Kyu Kim	<b>96</b>
<b>E-Posters-938</b>	Incidence and Risk Factors of Central Venous Catheter-Related Thrombosis after Scoliosis Correction Surgery Zhipeng Tu	<b>96</b>



# ASIAN SPINE JOURNAL

www.asianspinejournal.org

pISSN 1976-1902 · eISSN 1976-7846

Volume 17 · Number Supplement 1 · May 2023

<b>E-Posters-953</b>	Trends And Strategies of Proximal Junctional Failure after Spinal Reconstruction Surgery for Adult Spinal Deformity in Our Institution Shinya Nakagawa	97
<b>E-Posters-954</b>	Influence of Pelvic Parameter on Postoperative Spinal Alignment in Adolescent Idiopathic Scoliosis Lenke Type 5 Patient Takahiro Kitagawa	98
<b>E-Posters-970</b>	Postoperative Progression of Thoracic Kyphosis at the Fusion Level Can Influence the Surgical Outcome after Posterior Decompression and Fusion for Patients with Thoracic Ossification of the Longitudinal Ligament Hiroshi Takahashi	98
<b>E-Posters-988</b>	Finite Element Analysis of Three Kinds of Pedicle Screw Designs Bin Ye	99
<b>E-Posters-991</b>	Benefit of the 360-Degree Stabilization in Oncological Spine Cases: A Matched Pair Analysis Maximilian-Niklas Bonk	99
<b>E-Posters-997</b>	Long-term Clinical and Radiographical Results of Posterior Instrumentation Surgery for Pediatric Patient with Atlantoaxial Dislocation Kota Watanabe	100
<b>E-Posters-1050</b>	15-Year Survivorship Analysis of an Interspinous Device in Surgery for Single-Level Lumbar Disc Herniation Jong-Beom Park	100
<b>E-Posters-1057</b>	Resurgence of Role of Computed Tomography Myelogram in the Era of Magnetic Resonance Imaging for Surgical Decision Making of Lumbar Degenerative Disc Disorder Keyur Akbari	101
<b>E-Posters-1066</b>	Efficacy, Safety, and Reliability of Surgery on the Lumbar Spine under General versus Spinal Anesthesia: An Analysis of 64 Cases Sharif Ahmed Jonayed	101
<b>E-Posters-1067</b>	Single Stage Posterior Vertebral Column Resection for the Correction of Rigid and Severe Kyphotic Deformity: An Analysis of 22 Cases Sharif Ahmed Jonayed	102
<b>E-Posters-1068</b>	Efficacy, Safety, and Reliability of Using Single Anterior Approach for Subaxial Cervical Spine Dislocation Sharif Ahmed Jonayed	103
<b>E-Posters-1070</b>	Efficacy, Safety, and Reliability of High versus Low Dosages form of Tranexamic Acid Used in Adolescent Idiopathic Scoliosis Surgery Sharif Ahmed Jonayed	103
<b>E-Posters-1071</b>	Spinal Giant Cell Tumor with Paraparesis: A Case Report with an Overview of Current Treatment Modality Sharif Ahmed Jonayed	104
<b>E-Posters-1075</b>	The Machine-Vision Image-Guided Surgery System Reduces Fluoroscopy Time, Ionizing Radiation, and Intraoperative Blood Loss in Posterior Spinal Fusions for Scoliosis TKevin Lim	104
<b>E-Posters-1090</b>	Vertebral Artery Injury Min-Woo Kim	105

---

<b>E-Posters-1096</b>	Prevalence, Risk Factors, and Complications of Blood Transfusion in Lumbar Spinal Fusion Surgery: A Nationwide Population-Based Study Taewook Kang	<b>106</b>
<b>E-Posters-1100</b>	Single Position Prone Oblique Lateral Interbody Fusion: Technique Review and Early Lessons Mun Chun Lai	<b>106</b>
<b>E-Posters-1119</b>	Fusion Rate with Stand-Alone Mini-open Lateral-Anterior Lumbar Interbody Fusion Jiaming Cui	<b>107</b>
<b>E-Posters-1190</b>	Efficacy of Lateral-Anterior Lumbar Interbody Fusion Combined with Second-Stage Posterior Fixation versus One-Stage Posterior Spinal Canal Decompression and Internal Fixation Fusion in the Treatment of Degenerative Lumbar Scoliosis Jiaming Cui	<b>107</b>
<b>E-Posters-1200</b>	Factors Affecting Time from Admission to Surgery for Thoracolumbar AO Type A Fractures Yong Yao Tan	<b>108</b>
<b>E-Posters-1255</b>	Usefulness of Expandable Cage in Transforaminal Lumbar Interbody Fusion Gen Mori	<b>109</b>
<b>E-Posters-1281</b>	Clinical Outcomes of Ultrasound Guided Transforaminal Root Block in Cervical Spondylotic Radiculopathy due to Osteophyte Chang Su Kim	<b>109</b>
<b>E-Posters-1283</b>	Burden of Cervical Spinal Injury in India: The Untold Story Chang Su Kim	<b>110</b>
<b>E-Posters-1288</b>	Preoperative Compression Ratio of the Spinal Cord Using Quantitative Magnetic Resonance Imaging in the Surgically Treated Degenerative Cervical Spondylotic Myelopathy Ronald Tangente	<b>111</b>
<b>E-Posters-1289</b>	Accuracy and Safety of a Pedicle Screw Using the Freehand Technique in Minimally Invasive Scoliosis Surgery Yunjin Nam	<b>111</b>
<b>E-Posters-1300</b>	Clinical Characteristics of Culture-Positive Pyogenic Vertebral Osteomyelitis Akihiro Kakuta	<b>112</b>
<b>E-Posters-1308</b>	Preoperative Pain Sensitivity Predicts Postoperative Pain Severity and Analgesics Requirement in Lumbar Fusion Surgery: A Prospective Observational Study Ajoy Prasad Shetty	<b>113</b>
<b>E-Posters-1310</b>	A Survival Probability Tool Based on 10,537 Patients with Spinal Metastases in Hong Kong Using a Machine Learning Based Model Kenny Yat Hong Kwan	<b>113</b>
<b>E-Posters-1335</b>	A Case of Dural Injury Caused by the Drainage Tube after Lumbar Spinal Stenosis Surgery Shinji Tanishima	<b>114</b>
<b>E-Posters-1338</b>	Boomerang-Shaped Spinal Cord Compression and the C-Sign: Risk Factors for Complications following the Posterior Approach for Ossification of the Posterior Longitudinal Ligament in the Cervical Spine Jun-Hao Tan	<b>114</b>

# ASIAN SPINE JOURNAL

www.asianspinejournal.org

pISSN 1976-1902 · eISSN 1976-7846

Volume 17 · Number Supplement 1 · May 2023

- E-Posters-1363** Hirayama's Disease: Does Surgery Help? **115**  
Anindya Basu
- E-Posters-1375** Modified "Lift-up" Laminoplasty: A Novel Surgical Technique for Long-Segment Epidural/Intradural Tuberculoma: A Case Series **116**  
Anindya Basu
- E-Posters-1427** Deformity Angular Ratio and Its Correlation with Complications Rate **116**  
Muhammad Hamid
- E-Posters-1527** Ultra-Long Construct Navigated Minimally Invasive Spine Surgery Is Safe for Extensive Spinal Metastasis Patients **117**  
Panya Luksanapruksa
- E-Posters-1530** Postoperative Outcomes of Subaxial Cervical Spine Metastasis: Comparison among the Anterior, Posterior, and Combined Approaches **117**  
Sirichai Wilartratsami
- E-Posters-1554** Transforaminal Lumbar Interbody Fusion: A Two-Year Disability Outcomes Study **118**  
Gaurav Dhakal
- E-Posters-1605** Prediction of Cervical Spondylosis Classification Using Deep Learning with Convolutional Neural Network **118**  
Hiroyuki Tachi
- E-Posters-1615** Therapeutic Use of Platelet-Rich Plasma in Orthopedic and Spine Disorders: Our Experiences **119**  
Shahidul Islam
- E-Posters-1646** Analysis of Critical Mid-Sagittal Lumbar Canal Diameter and Its Clinical Significance in 1,491 Multiracial Asian Population **119**  
Chongyan Wang
- E-Posters-1666** Reduction of Radiation Exposure to Zero during Selective Lumbar Nerve Block **120**  
Ryo Kitagawa
- E-Posters-1682** The Comparative Morphology of Posterior Longitudinal Ligament Ossification in Asian and Caucasian Populations **121**  
Alex Quok An Teo
- E-Posters-1698** Morphological Analysis for Safe Placements of Guide Pin Integrated Percutaneous Pedicle Screws Only with Antero-posterior Fluoroscopy **121**  
Ryo Kitagawa
- E-Posters-1717** Is Three-Dimensional Navigation Decreasing the Learning Curve for Thoraco-Lumbar-Sacral Pedicle Screw Insertion? Comparative Study of Accuracy between Chief Spine Consultant and Spine Fellows under His Study **122**  
Shreenidhi Kulkarni
- E-Posters-1720** Biplanar Expandable Cages for Transforaminal Lumbar Interbody Fusion Is Safe and Achieves Good 1-Year Clinical and Radiological Outcomes in an Asian Population **123**  
David Shaoen Sim
- E-Posters-1728** An Indigenously Developed Versatile Halopelvic Ilizarov Distraction Assembly for Correction of Spine Deformities **123**  
Muhammad Saad Ilyas

# ASIAN SPINE JOURNAL

www.asianspinejournal.org

pISSN 1976-1902 · eISSN 1976-7846

Volume 17 · Number Supplement 1 · May 2023

---

- E-Posters-1739** Useful Axial Reformatting of Magnetic Resonance Myelography Based on Balanced Steady-State Free Precession **124**  
Hiroki Iwai
- E-Posters-1741** Single Step Percutaneous Pedicle Screw System Is Safe, Effective and Has Good 1-Year Outcome in an Asian Population **125**  
David Shaoen Sim
- E-Posters-1849** Identification and Validation of Self-Screening Tests for Endemic Cervical Fluorosis **125**  
J. Naresh-Babu
- E-Posters-1873** Analysis of Patients with Delayed Diagnosis of Pyogenic Spondylitis **126**  
Junya Tsukisaka
- E-Posters-1882** Assessment of Outcomes of Spine Surgery in Indian Patients Involved in High-End Contact Sports **127**  
Priyank Patel
- E-Posters-1925** Assessment of Posterior Ligamentous Complex Injury by Computed Tomography and Magnetic Resonance Imaging Scan in AO Type-A Fractures of the Thoracolumbar Spine on Radiographs **127**  
Manish Chadha

## APSS Annual Meeting 2023 with Live Operative Course in Coimbatore

### Abstracts for Medal Papers Basic Science Papers

243

#### Dural Repair: Efficacy Assessment of Different Techniques: A Cadaveric Study Comparing the Naked Eyes and Surgical Loupes

Roongrath Chitragran

*Phramongkutklao Hospital and College of Medicine, Bangkok, Thailand*

**Introduction:** Watertight dural repair is crucial to achieve successful dural tear sutures. Microscopic or surgical loupes are recommended to use to magnify and assist repairing the dura. However, many spine surgeons repair dural tears under the naked eye. The efficacy of repairing dural tears by the naked eye compared with microscopic or surgical loupes has never been studied.

**Purpose:** This study aimed to compare the efficacy of dural repairing techniques using the naked eye or surgical loupes.

**Methods:** A cadaveric experimental study was conducted. Four fresh human cadaveric specimens were used to harvest the spinal cord. Dural tear and cerebrospinal fluid (CSF) leakage were simulated with a water pressure control system (Arthrex AR-6475 arthroscopic pump). We compared surgical repair using the naked eye and surgical loupes. Surgical closure was achieved using Prolene 6-0 and Durepair. A total of 32 experimental dural tears were subdivided to four groups. The four groups were Prolene 6-0 with the naked eye (n=8), Prolene 6-0 with surgical loupe (n=8), Durepair with the naked eye (n=8), and Durepair with surgical loupe (n=8). The total time used for

sutures and post suture CSF water leakage pressure were recorded and compared among the subgroups.

**Results:** Our results showed that surgical loupe assisted dural closure and sutures were significantly faster than the naked eye in both Prolene 6-0 (surgical loupe,  $4.87 \pm 0.19$  minutes; naked eye,  $7.18 \pm 0.36$  minutes;  $p < 0.001$ ) and Durepair groups (surgical loupe,  $9.84 \pm 0.21$  minutes; naked eye,  $13.27 \pm 0.42$  minutes;  $p < 0.001$ ). CSF leakage pressure in the surgical loupe groups were higher than in the naked eye groups in both Prolene 6-0 (surgical loupe,  $100.00 \pm 5.35$  mm Hg; naked eye,  $96.88 \pm 7.99$  mm Hg;  $p = 0.373$ ) and Durepair (surgical loupe,  $96.88 \pm 4.58$  mm Hg; naked eye,  $95.63 \pm 4.17$  mm Hg;  $p = 0.577$ ) but without significant difference. Prolene 6-0 was significantly faster to use for sutures than Durepair in both sutures by the naked eye and surgical loupe assisted ( $p < 0.001$ ). Prolene 6-0 showed a higher leakage pressure than Durepair in both the naked eye and surgical loupe assisted sutures but without significant difference (naked eye,  $p = 0.701$ ; surgical loupe,  $p = 0.230$ ).

**Conclusions:** Repairing a dural tear without using surgical loupes consumed more time and did not achieve similar maximum leak pressure compared with using surgical loupes. However, no statistically significant difference was observed in terms of CSF leakage pressure. Durepair consumed more time than Prolene 6-0 while leakage pressure was similar. We recommended the use of surgical loupes when performing dural repair. Durepair is suitable to repair larger dural defects that cannot be closed using a simple suture technique.

483

## The Electromyographic Discrepancy of Paravertebral Muscles Predicts an Early Curve Progression of Untreated Adolescent Idiopathic Scoliosis

Jason Pui Yin Cheung

Department of Orthopaedics and Traumatology, The University of Hong Kong, Hong Kong

**Introduction:** A higher electromyographic (EMG) activity is observed on the convexity of a scoliotic curve. This differs from non-scoliosis population and has been implicated as a causative factor in the progression of adolescent idiopathic scoliosis (AIS).

**Purpose:** To explore the relationship between EMG discrepancy of paravertebral muscles and scoliosis progression of untreated AIS, how vertebral morphology and EMG discrepancy evolve during scoliosis progression, and to identify the difference of EMG activities between scoliosis and non-scoliosis participants in upright sitting and doing voluntary back-extension, respectively.

**Methods:** A total of 534 adolescents were consecutively recruited; 267 girls with Cobb angles  $\geq 10^\circ$  (scoliosis cohort) and 267 girls with  $< 10^\circ$  (non-scoliosis cohort) undertook EMG measurements at their first presentation. Radiographic and EMG reassessments were done at study initiation and the 7-month follow-up. Tele questionnaire was collected biweekly to record participants' sport intensity and to net the participants who encountered treatment during follow-up. An early scoliosis progression (progression cohort) was defined as an increase of Cobb angles  $\geq 6^\circ$  of the major curves at the 7-month whereas non-progression (non-progression cohort) was identified a change  $< 6^\circ$ . The root mean square of the EMG (rms-EMG) signal of paravertebral muscles was collected with participants in upright sitting and doing voluntary back-extension in prone lying. A rms-EMG ratio ( $\text{rms-EMG ratio} = \frac{\text{rms-EMG of convexity}}{\text{rms-EMG of concavity}}$ ) at the upper end vertebrae/apical vertebral (AV)/lower end vertebrae (LEV) of the major curve was calculated for statistical analysis and represented the EMG discrepancy of paravertebral muscles.

**Results:** A higher rms-EMG ratio at AV (sitting: 95% confidence interval [CI], 0.49–0.57;  $p < 0.01$ ; back-extension: 95% CI, 0.29–0.37;  $p < 0.01$ ) and LEV (sitting: 95% CI, 0.21–0.27;  $p < 0.01$ ; back-extension: 95% CI, 0.14–0.19;

$p < 0.01$ ) levels was noted in participants with scoliosis ( $n = 267$ ; age,  $12.5 \pm 1.7$  years; initial Cobb angle,  $26.4^\circ \pm 8.7^\circ$ ) compared to non-scoliosis controls ( $n = 267$ ; age,  $12.5 \pm 1.6$  years; initial Cobb angle,  $6.7^\circ \pm 1.1^\circ$ ) at baseline. Seventy-eight girls with AIS (28.8% of scoliosis cohort) showed scoliosis progression of the major curve (an increase of Cobb angle at the 6-month,  $6.6^\circ \pm 0.9^\circ$ ) at the 7-month. A significant higher rms-EMG ratio at the AV and LEV levels was noted in the progression cohort at either baseline (AV [sitting:  $p < 0.01$ ; back-extension:  $p < 0.01$ ], LEV [sitting:  $p < 0.001$ ; back-extension:  $p < 0.01$ ]) or 6-month (AV [sitting:  $p < 0.01$ ; back-extension:  $p < 0.01$ ], LEV [sitting:  $p < 0.01$ ; back-extension:  $p < 0.01$ ]). A rms-EMG ratio  $\geq 1.7$  at the AV level while doing voluntary back-extension was a risk factor for an early scoliosis progression at the 7-month.

**Conclusions:** In addition to skeletal immaturity, the rms-EMG ratio  $\geq 1.7$  at the AV level of paravertebral muscles, captured with voluntary back-extension in prone lying, was related with an early scoliosis progression after 7 months without treatment. The EMG discrepancy of paravertebral muscles at the AV and LEV was observed in the scoliosis population regardless of testing posture. A consistently higher EMG discrepancy, detected with back-extension at the AV level, was presented with radiographic changes in three dimensions of the major curve after 7 months without treatment.

641

## Analysis of the Cement Distribution Pattern and Other Risk Factors That Affect the Incidence of Recompression Fractures of Vertebral Bodies after Vertebroplasty or Kyphoplasty

Minkyu Shin

Department of Orthopaedic Surgery, Gachon University Gil Medical Center, Incheon, South Korea

**Introduction:** With the increasing incidence of recompression fractures after vertebroplasty or kyphoplasty, this study analyzed the risk factors that affect the occurrence of recompression vertebral fractures, such as cement distribution, existence of avascular necrosis (Kummell's disease), type of procedures, bone mineral density, sex, and age.

**Methods:** Two hundred and thirty-eight patients who

underwent vertebroplasty or kyphoplasty at the author's clinic from 2005 to 2015 were enrolled in this study. The patients were divided into four groups according to the distribution of injected cement. The patients were classified as type 1 and type 2 when injected cement was contacted only to the upper or lower endplate of the body respectively. They were classified as type 3 when both the upper and lower endplates were contacted by injected cement. When neither the upper nor the lower endplate was contacted, the patients were called type 4. This study statistically evaluated the effects of the risk factors, including the cement distribution on the incidence of recompression vertebral fracture after vertebroplasty or kyphoplasty.

**Results:** There were 59 cases (24.8%) of recompression fracture after vertebroplasty or kyphoplasty, among the 238 cases. According to the analysis, the recompression of the vertebral body after vertebroplasty or kyphoplasty occurred more often when the compression fracture was accompanied by osteonecrosis at the body ( $p < 0.05$ ). The patients who had injected cement distributed at both upper and lower plate simultaneously (type 3) had a lower incidence of recompression fracture of the vertebral body after vertebroplasty or kyphoplasty ( $p = 0.008$ ). In addition, the kyphoplasty group had a lower incidence of recompression after the procedure than vertebroplasty group ( $p = 0.02$ ).

**Conclusions:** Careful attention should be given to these patients with osteonecrosis at the compression fracture level through a preoperative evaluation. In addition, if the injected cement does not contact both the upper and lower endplates, careful observation is required during the follow-up period based on the high incidence of vertebral recompression fractures proven through this study. Further technical and biomechanical research and efforts will be needed to make the cement contact both endplates.

891

## Core Planar Cell Polarity Genes VANGL1 and VANGL2 in Predisposition to Congenital Scoliosis

Jason Pui Yin Cheung

*Department of Orthopaedics and Traumatology, The University of Hong Kong, Hong Kong*

**Introduction:** Impaired somitogenesis leads to congenital

vertebral malformations (CVMs), which clinically manifest as congenital scoliosis (CS). Wnt/ $\beta$ -catenin signaling is central to somitogenesis, whereas the role of Wnt/planar cell polarity (Wnt/PCP) signaling in somitogenesis remains unclear. In vertebrates, PCP controls many fundamental cellular and developmental processes such as collective cell movement and convergent extension (CE), which coordinate the elongation and narrowing of the anterior-posterior (AP) body axis. Disruption of PCP signaling causes severe defects in humans and mice, the most common of which are neural tube defects that range from spina bifida in humans to craniorachischisis in mice. Vangl1 and Vangl2, the vertebrate homologs of *Drosophila* Vang, are two highly conserved four-pass transmembrane core proteins dedicated to PCP signaling that are required for a variety of embryonic developmental processes.

**Purpose:** To analyze a multi-center and multi-ethnic cohort of CS patients and identify any deleterious VANGL1 and VANGL2 variants. To confirm variants' pathogenicity by in vitro and in vivo functional analyses in cultured cells, zebrafish, and genetically modified mouse models.

**Methods:** Patients with VANGL1 or VANGL2 variants were identified from multicenter and multiethnic CS cohorts from mainland China (708 cases), Hong Kong Special Administrative Region of China (67 cases), Japan (one case), and the United States (six cases). Whole-exome sequencing was performed. Sanger sequencing was performed to confirm candidate variants. Immunoblotting and immunofluorescence was performed with staining of the endoplasmic reticulum and with quantification of the intramembrane/total signal. The AB zebrafish strain was used for microinjection. Zebrafish embryos were injected with VANGL2-morpholino and raised until 2 days post-fertilization. Vangl1 and Vangl2 knock-in mouse strains were created and micro-computed tomography analyses were performed.

**Results:** Nine VANGL1 and eight VANGL2 rare nonsynonymous missense variants were identified. The VANGL1 p.E281G and VANGL2 p.L226F were deemed likely to be gene-disrupting. Deletion of two core PCP components, Vangl1 and Vangl2, leads to defective somitogenesis and spinal malformation that mimics the conditions of human CVMs. By analyzing exome sequencing data from multi-center and multi-ethnic CS patients, we identified a number of rare variants of VANGL1 and VANGL2. VANGL variants accumulated intracellularly with strong co-localization with the endoplasmic reticulum. Wild-

type VANGL localized on the plasma membrane. We observed loss-of-function and dominant-negative effects among these variant alleles. CE movement defects and shortened AP body axis was observed in zebrafish (Fig. 1). The failure of mutant VANGL messenger RNA to restore CE defects in zebrafish models confirmed the variants' pathogenicity. Moreover, *Vangl1* knock-in (p.R258H) mice exhibited vertebral malformations in a *Vangl2* dose-dependent manner (Fig. 2).

**Conclusions:** Our studies revealed new critical roles for PCP signaling in somitogenesis and predisposition to CVMs. *Vangl1* and *Vangl2* were highly expressed in developing somites, and *Vangl* mutant mice exhibited multiple spine and rib anomalies including hemivertebrae, which is the most common cause of CS. We addressed the *in vivo* functional significance of the most deleterious variants in both zebrafish and mouse models. In a *Vangl2* dose-dependent manner, *Vangl1*-R258H knock-in mice developed caudal hemivertebrae or asymmetric vertebrae, mimicking the spinal anomalies in human patients.




Fig. 1. Comparing wildtype (left) with VANGL2 variant (middle). More severe phenotype with both VANGL2 and VANGL1 variant (right).

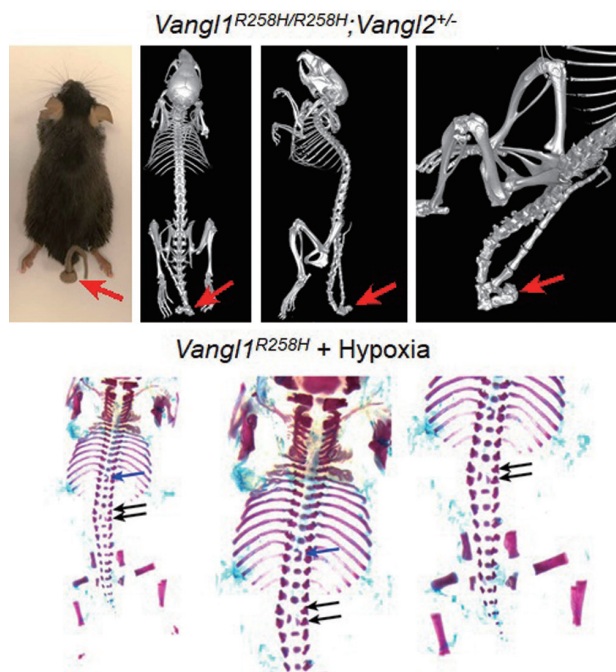


Fig. 2. Knock-in mouse model with looptail, hemivertebrae, and asymmetrical vertebral malformations (arrows).

## 1630

### Molecular Interactions between Intervertebral Disc Host Proteins and Putative Pathogenic Effector Proteins in Degenerate Discs: A Predictive Insilico Analysis

Shanmuganathan Rajasekaran

Ganga Hospital, Coimbatore, India

**Introduction:** Sub-clinical infection has been hypothesized to play a role in etiopathogenesis disc disorders. Earlier reports have provided definite evidence of the prevalence of host-defense responses within the intervertebral disc, which serves as the proof-of-evidence for infection-mediated inflammatory mechanisms. In order to understand the rewiring of host metabolism, interactions between effector proteins (secretory proteins of the microbial consortia) and host proteins were studied.

**Methods:** Proteome data of 36 nucleus pulposus (NP) tissues were considered for the study under three groups: 11 healthy NP tissues from brain-dead voluntary organ donors (normal disc group [ND]) and 25 degenerated diseased group (DD)—17 in Modic and eight in non-Modic condition, respectively. The proteome raw data were mapped with the bacterial and human proteome database to identify the host and bacterial proteins. Human proteins were manually curated based on literature evidence to identify the pathogen recognition receptor (PRR) proteins. Similarly, bacterial proteins were screened for the presence of effector proteins by mapping with the bacterial T3 secretory system library. Insilico-predictive analysis of molecular interactions between host proteins and putative pathogenic bacterial proteins was done to understand the host-pathogen regulatory mechanisms.

**Results:** Of 8,746 identified human proteins, 23 were manually curated as PRRs. Following stringent statistical parameters (25% sample prevalence and  $\geq 5$  peptide-spectrum matches), only six proteins such as C-type lectin domain family 3 member A (CLEC3A), C-type lectin domain family 11 member A (CLEC11A), C-type lectin domain family 2 member D (CLEC2D), interferon-inducible protein (AIM2), fibronectin (FN1), and vitronectin (VTN) were selected for the interaction study. To validate the host-pathogen interactions, molecular interaction analysis was performed between host PRRs and bacterial T3 secretory effector proteins. As a result, thermodynamically



stable interaction prevails between the bacterial effector proteins with chosen five PRRs except for AIM2. While no bacterial T3 secretory effector proteins were detected in ND group, 49 bacterial proteins (38: DD-Modic, 11: DD-non-Modic) were identified in DD group. Six effector proteins, such as adenosine triphosphate synthase subunit beta, elongation factor Tu 1, elongation factor Tu 2, elongation factor G, major outer membrane lipoprotein Lpp, and outer membrane protein A, were selected after mapping against the T3 secretory system library.

**Conclusions:** Host PRR proteins such as CLEC3A, CLEC2D, CLEC11A, FN1, and VTN interacted with the bacterial secretory proteins such as 30S ribosomal protein S4 and uridine diphosphate-glucose 6-dehydrogenase. Observed bacterial proteins indicate the bacterial presence in degenerate disc tissues, and observed PRR and its interactions indicate a possible host-microbiome interaction within NP tissues.

---

## Abstracts for Medal Papers Clinical Award Papers

---

314

### Computer-Assisted Diagnosis with Artificial Neural Networks for Odontoid Fracture Detection

Wongthawat Liawrungrueang

*Department of Orthopaedics, School of Medicine, University of Phayao, Phayao, Thailand*

**Introduction:** Artificial neural networks (ANNs) are computing systems inspired by the biological neural networks that constitute human brains. Computer-assisted diagnosis with ANNs from radiographic X-ray imaging was increasingly popular in the fields of medical image processing. Odontoid fracture is a common fracture of the axis and accounts for 10%–15% of all cervical fractures. A literature review on computer-assisted diagnosis with ANNs was not previously reported. This study proposes the ANNs for the detection of odontoid fracture by the Konstanz Information Miner (KNIME) analytics platform to offer a technique for computer-assisted diagnosis from

radiographic X-ray imaging.

**Methods:** This study obtained 432 open-mouth (odontoid) radiographic views of cervical spine X-ray images for dataset repositories to develop an ANNs model base on a convolutional neural network theory. All of the images contained diagnostic information, including normal radiographic images (n=216) and fracture images of the acute odontoid fracture (n=216). The model would classify whether the patient was an odontoid fracture or not. Seventy percent of the images were training data sets used for model training, and thirty percent were used for testing. KNIME's graphic user interface-based programming enabled class label annotation, data preprocessing, model training, and performance evaluation.

**Results:** All radiographic X-ray imaging was reported under the graphic user interface program by KNIME. The ANNs model has performed 50 epochs of training. Performance model evaluation for detecting odontoid process fracture by the sensitivity (recall), specificity (predictive value) f-measure, and prediction error were all 100.0%, 95.4%, 97.77%, and 2.3%, respectively. The model's accuracy was equal to 97% of the area under the receiver operating characteristic curve for the diagnosis of odontoid process fractures.

**Conclusions:** ANNs models with the KNIME analytics platform were successfully utilized for computer-assisted diagnosis of odontoid fractures using radiographic X-ray images. This approach can assist the radiologist in the screening or assist in the detection and diagnosis of acute fractures.

434

### Conservative Treatment of Atlantoaxial Rotatory Fixation

Yusuke Oshita

*Showa University Northern Yokohama Hospital, Yokohama, Japan*

**Introduction:** Although atlantoaxial rotatory fixation (AARF) is typically treated conservatively, the optimal timing for inpatient treatment has not been established.

**Purpose:** This retrospective study aims to investigate the course of AARF treatment.

**Methods:** We conducted a retrospective review of patients with AARF who were treated at Showa University Northern Yokohama Hospital between April 2011 and March

2021. One patient with third-party actions at the point of injury was excluded because the timing of pain disappearance could not be determined. We collected data regarding age, gender, Fielding classification, treatment duration, treatment method, and outcomes.

**Results:** We included 136 patients (65 boys and 71 girls; average age, 5.6 years [range, 1–13 years]) with AARF. The courses of 109 patients (80.1%) were monitored to the point of cure, whereas 22 patients (16.2%) discontinued treatment, and 5 (3.7%) were referred to other hospitals. The cause of onset was not attributed to any known cause in 51 patients (37.5%), whereas the cause of onset was minor trauma in 32 (23.5%) and during treatment for inflammatory diseases, such as colds, Kawasaki disease, mumps, or quinsy, in 53 patients (39.0%). All patients had Fielding classifications of 1 and 2. The duration of the symptom started to consult our clinic was 0 days in 47 (34.6%); 1 day in 29 (21.3%), 2–7 days in 33 (24.3%), and 8–14 days in 15 (11.0%) patients. The longest duration of symptoms was 44 days after onset without any treatment. The median length of treatment was 9 days (interquartile range, 5–25 days). Fifty-nine patients (43.4%) were treated with collar fixation, 47 (34.6%) with only bed rest, 27 (19.9%) with Glisson's traction, 2 (1.5%) with bed rest upon hospitalization, and 1 (0.7%) patient needs remodeling therapy wearing with collar orthosis after Glisson's traction. Bed rest was indicated for all patients at the time of the initial visit to the outpatient clinic. Those with symptoms continuing for 1–2 weeks after onset or with extreme pain were hospitalized. During the study period, no patient required reduction or surgical treatment with general anesthesia.

**Conclusions:** The use of Glisson's traction and remodeling therapy was successful in 100% of the patients treated. Approximately 80% of patients improved after only collar fixation or directed bed rest. Therefore, we could not confirm the appropriate time for conducting traction was appropriate. Moreover, the study did not include patients with Fielding classifications 3 and 4. Therefore, these cases will need further examination.

463

## Long-term Outcomes of Vertebral Body Sliding Osteotomy for the Treatment of Cervical Myelopathy: A Minimum of 5-Year Follow-up

Sung Tan Cho

*Department of Orthopaedic Surgery, Ilsan Paik Hospital, Goyang, South Korea*

**Introduction:** Vertebral body sliding osteotomy (VBSO) is an anterior decompression and fusion technique involving the anterior vertebral body translation along with ossification of the posterior longitudinal ligament or spondylotic lesion causing cord compression. VBSO has been reported to result in fewer complications, better lordosis restoration, and faster bone union than corpectomy. However, previous studies demonstrated the outcomes of VBSO with  $\geq 2$  years of follow-up, but its long-term outcome was not reported. Maintaining the advantages of VBSO in the early postoperative period during the long-term follow-up remained unclear. Therefore, this study aimed to (1) demonstrate the long-term outcomes of VBSO with a minimum of 5-year follow-up and (2) compare the results with other anterior reconstruction techniques including anterior cervical discectomy fusion (ACDF) and anterior cervical corpectomy fusion (ACCF).

**Methods:** A total of 128 patients, who underwent VBSO, ACDF, or ACCF for cervical myelopathy treatment and were followed up for  $>5$  years, were retrospectively reviewed. Fusion, subsidence, C0–2 lordosis, C2–7 lordosis, segmental lordosis, C2–7 sagittal vertical axis, surgical complications, neck pain Visual Analog Scale (VAS), Neck Disability Index (NDI), and Japanese Orthopedic Association (JOA) score were assessed. Statistical comparisons between the VBSO, ACDF, and ACCF groups were made.

**Results:** The VBSO, ACDF, and ACCF groups included 38 (29.7%), 62 (48.4%), and 28 (21.8%) patients, respectively. No cases experienced dural tear, postoperative neurologic deterioration, infection, and graft dislodgement, and no patient required revision operation during the follow-up in the VBSO group. The VBSO revision rate (0/38 [0%]) was significantly less than that of ACDF (8/62 [12.9%],  $p=0.023$ ) or ACCF (5/28 [17.9%],  $p=0.011$ ). VBSO demonstrated a higher fusion rate at 6-month and 1-year follow-up, but the fusion rate at 5 years (97.4%)

was not significantly different compared to ACDF (85.5%,  $p=0.054$ ) and ACCF (85.7%,  $p=0.077$ ). Segmental lordosis at the 5-year follow-up was significantly higher in the VBSO group ( $16.1\pm 7.6$ ) than the ACDF ( $p=0.002$ ) or ACCF ( $p<0.001$ ) groups. Furthermore, C2–7 lordosis at the 5-year follow-up was significantly higher in the VBSO group compared to the ACCF group ( $p=0.017$ ). Neck pain VAS, NDI, JOA score, and JOA recovery rate did not show significant intergroup differences during the postoperative 5-year period.

**Conclusions:** No cases required revision operation in VBSO during a 5-year follow-up, which demonstrated significant results compared to ACDF or ACCF. VBSO reached stable construct earlier than other techniques, as demonstrated with a higher 6-month and 1-year fusion rate, which would have enhanced the long-term safety and decreased the need for reoperation. Furthermore, VBSO showed a greater capacity to restore lordosis than ACDF or ACCF since it preserves the vertebral body and includes multiple lordotic shape interbody spacer insertion, which was maintained during the long-term follow-up. Therefore, VBSO demonstrated advantages over ACDF or ACCF regarding revision rate and lordosis restoration in long-term follow-up and is considered a safe anterior reconstruction technique for cervical myelopathy treatment.

528

## Establishing a Relationship Using Computed Tomography between Facet Distraction and Clinical Outcomes after Anterior Cervical Discectomy and Fusion

Jooyoung Lee

*Department of Orthopaedic Surgery, Asan Medical Center, Seoul, South Korea*

**Introduction:** Anterior cervical discectomy and fusion (ACDF), the gold standard treatment for radiculopathy and myelopathy, has the potential risk of inducing facet-mediated pain through over-distraction. However, the relationship between the clinical outcomes and facet distraction after ACDF remains unclear. Therefore, this study aimed to measure facet distraction using computed tomography (CT) and compare the results with clinical outcomes.

**Methods:** This was a retrospective cohort study. Patients

( $n=144$ ) who underwent a single-level ACDF were included. Each patient underwent plain radiography of the lateral cervical spine preoperatively, immediately, and 2 years post-surgery. CT was performed preoperatively, 3 days, and 1 year post-surgery. The inter-facet distance was measured at each time point, and changes in values from the preoperative distance were noted and used for the study. Patient-reported outcome measures were obtained preoperatively and at a 2-year follow-up. Receiver operating characteristic (ROC) curves were generated to derive the critical facet distraction point.

**Results:** The neck pain Visual Analog Scale score (VASn) showed a tendency to decrease during the follow-up period, and VASn at 3 weeks postoperatively ( $4.81\pm 2.11$ ) was the most severe. There was a significant positive correlation between facet distraction measured using CT 3 days postoperatively and VASn 3 weeks postoperatively (Spearman's correlation coefficient:  $0.703$ ,  $p<0.001$ ) (Fig. 1). Facet distraction measured using radiography showed less correlation with VASn at all time points than CT. An ROC curve analysis showed that the cut-off value of  $\Delta$  facet distraction was 1.8 mm for VASn  $\geq 4$  (area under the curve= $0.901$ , sensitivity= $87\%$ , specificity= $81\%$ ) (Fig. 2). Based on the cut-off value of  $\Delta$  facet distraction of 1.8 mm, the patients were divided into group C (control group;  $\Delta$  facet distraction  $<1.8$  mm,  $n=69$ ) and group O (over-distraction group;  $\Delta$  facet distraction  $\geq 1.8$  mm,  $n=75$ ). Group O showed significantly worse clinical outcomes than group C, including neck and arm pain VAS scores at all time points until the final 2-year follow-up (Table 1).

**Conclusions:** The change value of facet distraction measured using CT rather than plain radiography correlated better with neck pain, and over-distraction contributed to adverse long-term outcomes, including neck and arm pain after ACDF. Additionally, an over-distraction of  $\geq 1.8$  mm may cause radiculopathy of adjacent segments along with facet-mediated axial pain; therefore, cage height should be carefully determined to avoid over-distraction during ACDF.

**Table 1.** Comparison of clinical outcomes between groups O and C

	Group C ( $\Delta$ facet distraction $<1.8$ mm)	Group O ( $\Delta$ facet distraction $\geq 1.8$ mm)	<i>p</i> -value
<b>VASn</b>			
3w	2.41 $\pm$ 1.14	5.03 $\pm$ 2.01	$<0.001^*$
6w	1.29 $\pm$ 1.28	3.40 $\pm$ 2.01	$<0.001^*$
3m	2.49 $\pm$ 2.07	4.69 $\pm$ 2.42	$<0.001^*$
6m	1.84 $\pm$ 1.49	3.08 $\pm$ 1.54	$<0.001^*$
1y	1.00 $\pm$ 1.49	2.15 $\pm$ 1.59	$<0.001^*$
2y	0.62 $\pm$ 0.78	1.01 $\pm$ 0.85	0.005*
<b>VASa</b>			
3w	3.29 $\pm$ 1.93	4.23 $\pm$ 1.91	0.002*
6w	2.78 $\pm$ 1.58	3.52 $\pm$ 1.83	0.011*
3m	2.61 $\pm$ 1.80	4.11 $\pm$ 2.43	$<0.001^*$
6m	2.14 $\pm$ 2.11	2.96 $\pm$ 2.33	0.036*
1y	1.61 $\pm$ 1.59	3.37 $\pm$ 2.10	$<0.001^*$
2y	0.91 $\pm$ 0.80	1.48 $\pm$ 0.87	$<0.001^*$

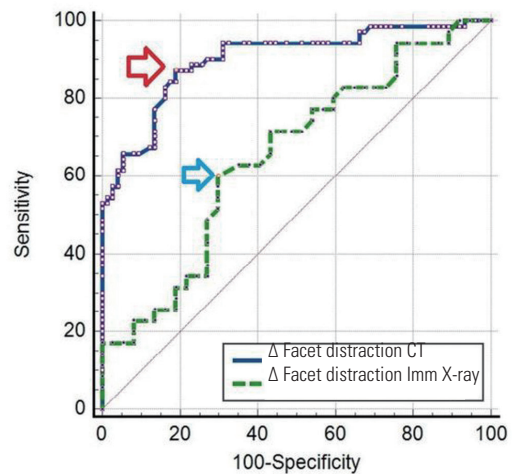
Values are presented as mean $\pm$ standard deviation.

O, over-distraction; C, control; VASn, Visual Analog Scale score of neck pain; VASa, Visual Analog Scale score of arm pain; w, weeks after surgery; m, months after surgery; y, year after surgery.

\* $p < 0.05$  (by Mann-Whitney *U* test).

		VASn 3 w	VASn 6 w	VASn 3 m	VASn 6 m	VASn 1 y	VASn 2 y
$\Delta$ Facet Dis. 3d CT	Correlation coefficient	0.703	0.596	0.507	0.442	0.322	0.201
	<i>p</i> -vale	$<0.001^*$	$<0.001^*$	$<0.001^*$	$<0.001^*$	$<0.001^*$	0.01*
$\Delta$ Facet Dis. Imm X-ray	Correlation coefficient	0.275	0.307	0.237	0.141	0.172	0.195
	<i>p</i> -vale	$<0.001^*$	$<0.001^*$	$<0.003^*$	0.110	0.054	0.029*
$\Delta$ Facet Dis. 3m X-ray	Correlation coefficient	0.225	0.341	0.145	0.131	0.024	0.023
	<i>p</i> -vale	0.004*	$<0.001^*$	0.112	0.120	0.464	0.452
$\Delta$ Facet Dis. 6m X-ray	Correlation coefficient	0.257	0.418	0.125	0.140	0.120	0.152
	<i>p</i> -vale	0.003*	$<0.001^*$	0.191	0.110	0.137	0.107

**Fig. 1.** Results of correlation between the Visual Analog Scale score of neck pain (VASn) and  $\Delta$  facet distraction measured using computed tomography and radiography after anterior cervical discectomy and fusion. Spearman's correlation coefficient rank: green (high), purple (moderate), blue (low), and yellow (low). Dis., distraction; Imm, immediately after surgery; d, days after surgery; w, weeks after surgery; m, months after surgery; y, year after surgery. \* $p < 0.05$ .



**Fig. 2.** Receiver operating characteristic curve analysis for the cut-off value of  $\Delta$  facet distraction measured using plain radiography and computed tomography (CT) after anterior cervical discectomy and fusion for a neck pain Visual Analog Scale score  $\geq 4$ . The cut-off value (red arrow) for  $\Delta$  facet distraction measured using CT was 1.8 mm, area under the curve (AUC) was 0.901, and the sensitivity and specificity were 87.14 and 81.08, respectively. Additionally, the cut-off value (blue arrow) for  $\Delta$  facet distraction measured immediately after surgery (Imm) using plain radiography was 2.56 mm, AUC was 0.654, and the sensitivity and specificity were 60.00 and 70.27, respectively.

## 822

### Anterior Column Realignment through Open Preposterous Release-Anterior-Posterior Fusion versus Hybrid Minimally Invasive Anterior-Posterior Fusion for Dynamic Sagittal Imbalance of the Spine

Joonghyun Ahn

Department of Orthopaedic Surgery, Bucheon St. Mary's Hospital, Bucheon, South Korea

**Introduction:** Recently, advanced sagittal correction of adult spinal deformity (ASD) has been introduced, such as pre-posterior release-anterior-posterior instrumentation (PAP) as a combined approach (anterior column realignment, ACR) and hybrid technique anterior-posterior surgery (AP) using minimal approach (lateral lumbar interbody fusion, LLIF) with open posterior instrumentation. ACR through PAP has conventionally invasive approaches, which have a limited utility for severe spectrum of sagittal plane deformity. However, PAP is an extensive surgery and is associated with a large amount of intraoperative blood loss and significant complication rates. To our knowledge, few comparative studies have been conducted between these two surgical procedures for ASDs.

**Purpose:** The purpose of this study was to investigate the

clinical and radiological outcomes after ACR through PAP and hybrid AP using minimally invasive LLIF.

**Methods:** Patients diagnosed with dynamic sagittal imbalance (DSI) between May 2012 and July 2019 were included in this study. The inclusion criteria were (1) age >65 years at the index surgery; (2) DSI without major coronal imbalance; and (3) patients who underwent ACR with proximal fusion level to T10 and distal to the sacropelvis using bilateral iliac screws, or minimally invasive LLIF with insertion of three or more cages from L1–L5, and/or posterior lumbar interbody fusion or anterior lumbar interbody fusion for L5–S1. Patients with (1) incomplete data and radiographs or (2) less than 2 years' postoperative follow-up were excluded. Clinical outcomes and radiological parameters were evaluated and compared between the groups.

**Results:** A total of 91 patients who underwent long fusions from T10 to the sacropelvis were enrolled and divided into two groups: AP and PAP. AP was performed in 26 and PAP in 65 patients. Preoperatively, Visual Analog Scale (VAS) and Oswestry Disability Index (ODI) scores were similar between the two groups ( $p>0.05$ ). However, the VAS for back pain was higher in the PAP group than that in the AP group at the final follow-up. The ODI score at the final was similar in both groups. The preoperative lumbar lordosis (LL) was  $7.3^{\circ}\pm 22.8^{\circ}$  in the AP and  $-10.4^{\circ}\pm 24.6^{\circ}$  in the PAP group ( $p=0.002$ ). The postoperative LL was  $38.0^{\circ}\pm 9.1^{\circ}$  in the AP and  $52.5^{\circ}\pm 12.5^{\circ}$  in the PAP group ( $p<0.001$ ). The preoperative pelvic incidence (PI)–LL was  $43.8^{\circ}\pm 24.2^{\circ}$  in the AP and  $67.5^{\circ}\pm 26.2^{\circ}$  in the PAP group ( $p<0.001$ ). Postoperatively, the PI–LL was  $13.1^{\circ}\pm 11.3^{\circ}$  in the AP and  $4.6^{\circ}\pm 14.0^{\circ}$  in the PAP group ( $p=0.009$ ). Proximal junctional failures developed in five patients (19.2%) in the AP group and 17 patients (26.2%) in the PAP group ( $p>0.05$ ). However, rod fracture developed in one patient in the AP group and 16 patients in the PAP group, with statistical significance ( $p=0.034$ ). Twelve patients (18.5%) underwent reoperation in the PAP group and four patients (15.4%) in the AP group.

**Conclusions:** Although PAP provides a more powerful correction for severe sagittal malalignment than AP procedures, PAP results in more mechanical complications requiring reoperations. Thus, this study does not suggest that one treatment is superior to the other.

984

## The Criteria of Severe Dynamic Sagittal Imbalance in Adult Spinal Deformity and Its Importance

Sung Min Kim

*Department of Orthopaedic Surgery, Kyung Hee University Hospital at Gangdong, Seoul, South Korea*

**Introduction:** There is no study about the evaluation for severity of dynamic sagittal imbalance (DSI) of adult spinal deformity (ASD) patients.

**Purpose:** To analyze characteristics of patients with “severe” DSI in ASD and establish a criterion for them.

**Methods:** One hundred two ASD patients with the sagittal imbalance and four cardinal signs of lumbar degenerative kyphosis were retrospectively analyzed. All patients underwent spine surgery for deformity correction and were divided into three groups according to a diagnostic criterion. The criterion was based on Oswestry Disability Index scores and dynamic feature ( $\Delta$  timewalk: time until C7 sagittal vertical axis (C7SVA) reaches 20 cm or more after starting walking) of sagittal imbalance. The quality and quantity of paravertebral back muscles were analyzed and compared by using T2-weighted axial images in the Picture Archiving and Communication System viewing software. We performed statistically time-dependent spinopelvic sagittal parameters analysis in the full-standing lateral radiographs. The lumbar flexibility of patients was also analyzed based on dynamic (flexion and extension) lateral lumbar radiographs: rigid, less than  $10^{\circ}$ ; not rigid,  $10^{\circ}$  or more.

**Results:** Under the diagnostic criteria, 102 patients could be classified into three groups: mild ( $\Delta$  timewalk  $\geq 3$  minutes, 35 patients), moderate (3 minutes  $>$   $\Delta$  timewalk  $\geq 30$  seconds, 38 patients), and severe (30 seconds  $>$   $\Delta$  timewalk, 29 patients). There was significantly higher signal intensity ( $533.4\pm 237.5$ ,  $p<0.001$ ) and a larger area of fat infiltration ( $35.2\pm 5.4$ ,  $p<0.001$ ) in the back muscles of the severe group than in those of the mild group ( $223.8\pm 67.6$ ,  $22.9\pm 11.9$ ) and moderate group ( $294.4\pm 214.7$ ,  $21.6\pm 10.6$ ). Also, the analysis of lumbar flexibility revealed significantly lower value in severe group than in mild and moderate groups. Severe group had significantly larger lumbar kyphosis (LL,  $26.1^{\circ}\pm 22.7^{\circ}$ ;  $p<0.05$ ), higher pelvic incidence (PI,  $60.4^{\circ}\pm 10.7^{\circ}$ ;  $p<0.05$ ) and PI–LL ( $86.5^{\circ}\pm 26.6^{\circ}$ ,  $p<0.05$ )

than mild group ( $5.2^{\circ}\pm 16.3^{\circ}$ ,  $52.9\pm 13.2^{\circ}$ ,  $58.7^{\circ}\pm 18.8^{\circ}$ ) and moderate group ( $13.7^{\circ}\pm 28.6^{\circ}$ ,  $53.5\pm 12.4^{\circ}$ ,  $66.6^{\circ}\pm 13.4^{\circ}$ ). PI-LL was statistically significant with the area under the curve=0.810 (95% confidence interval, 0.666–0.954) when the baseline was set at  $75.3^{\circ}$ . The severe group showed more perioperative complications, less immediate postoperative correction of LL, and loss of sagittal balance achieved by immediate postoperative than other groups.

**Conclusions:** We suggest a criterion of severe DSI in ASD. First, C7SVA becomes greater than 20 cm within 30 seconds after walking or standing. And second, rigid lumbar curve less than  $10^{\circ}$  in dynamic lateral radiographs. And third, PI-LL mismatch is more than  $75.3^{\circ}$ .

## 1137

### Mechanical Complications and Global Alignment and Proportion Score after Limited Long-Segment Fusion for De Novo Adult Spinal Deformity: Comparison of Lateral Lumbar Interbody Fusion and Three-Column Osteotomies

Hiroshi Moridaira

*Dokkyo Medical University, Mibu, Japan*

**Introduction:** Subtypes of de novo adult spinal deformity (ASD) in which lumbar kyphosis is the main deformity and there is no kyphoscoliosis of the thoracolumbar spine can be corrected by limited long-segment fusion. Many surgeons have avoided that stopping proximally in the upper lumbar spine would lead to a high percentage of proximal junctional kyphosis and/or failure because of the concentration of stress on these segments. The purpose of this study was to evaluate the global alignment and proportion (GAP) score and mechanical complications after limited long-segment fusion for this subtype of ASD and to compare lateral lumbar interbody fusion (LIF) and the 3-column osteotomies (3CO).

**Methods:** This was a single-center study of 50 patients (average age, 66.5 years) who underwent limited long-segment fusion (average, 4.8 levels) with a minimum 2 years of follow-up for ASD. The exclusion criteria were T10–L2 kyphosis  $>20^{\circ}$  and scoliotic deformity with an upper end vertebra above T12. LIF group included 38 patients, and 3CO group included 12 patients. GAP score was calculated using parameters from early postoperative

radiograph. Proximal and distal junctional kyphosis and/or failure and implant-related complications were considered mechanical complications. GAP scores and mechanical complications were compared between the two groups.

**Results:** In LIF group, patients were grouped according to the GAP score: 4 (10.5%) as proportioned, 11 (28.9%) as moderately disproportioned, and 23 (60.5%) as severely disproportioned. After a mean 4.5 years of follow-up, 19 patients (50%) experienced mechanical complications and 10 (26.3%) underwent mechanical revision. In 3CO group, patients were grouped: 6 (50%) as proportioned, 4 (33.3%) as moderately disproportioned, and 2 (16.7%) as severely disproportioned. After a mean 7.1 years of follow-up, two patients (16.7%) experienced mechanical complications and 1 (8.3%) underwent mechanical revision. The area under curve for the GAP score predicting mechanical complications was 0.81. The differences were statistically significant in GAP scores (7.4 vs. 3.8,  $p=0.0024$ ) and mechanical complications (50% vs. 17%,  $p=0.041$ ) between the two groups (LIF vs. 3CO).

**Conclusions:** In terms of limited long-segment fusion preserving mobile intervertebral segments for subtypes of ASD, the GAP score can predict mechanical complications, the use of 3CO (posterior closing wedge osteotomy) to create lumbar lordosis can produce and maintain sufficient global alignment. LIF (open wedge correction) was reported a safe and effective approach in managing ASD, whereas limited long-segment fusion with LIF for ASD may affect the development of mechanical complications and still have limitations.

## 1194

### Atlas Osteosynthesis Screw Placement Using the Intersection between Lateral Mass and Inferomedial Edge of the Atlas Posterior Arch: Human Cadaveric Study

Torphong Bunmaprasert

*Chiang Mai University, Chiang Mai, Thailand*

**Introduction:** Atlas (C1) fracture is commonly treated conservatively. However, unstable atlas fracture with or without associated ligamentous injuries may require surgical fixation. Osteosynthesis in displaced atlas fracture is difficult to identify the proper entry point and trajectory to insert the lateral mass screw fixation. The aim is to

compare the atlas lateral mass screw placement using the intersection between the lateral mass and inferomedial edge of the posterior arch, as an isolated medial reference, between screw trajectory 0° and 15° angulation while performing atlas osteosynthesis screw fixation.

**Methods:** Twenty-four atlas in fresh human cadavers were prepared for inserting the 4.0-mm lateral mass screws. They were divided into two groups: group 1 (screws inserted at 3 mm lateral to the reference entry point with trajectory 0° angulation) and group 2 (those inserted with trajectory 15° angulation). Computed tomography scan was performed before and after inserting atlas lateral mass screws for evaluating atlas anatomy and screw breach grading.

**Results:** All parameters between group 1 and group 2 were found statistically different: bilateral intraosseous screw lengths (17.92±1.47 mm vs. 20.71±2.4 mm), bilateral screw length (29.92±1.72 mm vs. 33.13±1.78 mm), left screw medial angulation (x°) (0.67°±0.78° vs. 14.17°±3.51°), right screw medial angulation (y°) (0.83°±1.03° vs. 14.25°±2.53°), and bilateral screw medial angulation (0.75°±0.9° vs. 14.21°±2.99°). Only bilateral lateral mass screw superior angulation (z°) (22.21°±5.32° vs. 22.75°±7.94°) was not difference. Twenty-two screws (91.67%) using the 0° medial angulation and nineteen screws (79.17%) using the 15° medial angulation had no cortical violation (grade 0). However, two screws (8.33%) with 0° medial angulation and five screws (20.83%) with 15° medial angulation had breach less than 2 mm (grade 1) without screw pullout. There was no screw breach distance between 2–4 mm (grade 2) or breach distance more than 4 mm (grade 3).

**Conclusions:** Using 3-mm lateral to an intersection between the lateral mass and inferomedial border of the atlas posterior arch can be used to be an easily-identifiable constant entry point to insert the lateral mass screw with trajectory 0° and 15° medial angulation in atlas fracture osteosynthesis.

1329

## Is Anterior-Only Approach a Reliable Surgical Strategy in Ankylosing Spondylitis Patients with Cervical Spine Fractures

Ajoy Prasad Shetty

Ganga Medical Centre and Hospital, Coimbatore, India

**Introduction:** Current literature has established better outcomes following surgical management of cervical spine fractures in patients with ankylosing spondylitis. The literature favors combined anterior and posterior as well as posterior approaches over the anterior approach; however, it lacks an objective criterion to decide on the surgical approach. The study aims to determine the injury patterns in patients of ankylosing spondylitis with a cervical spine injury, identify, define, and analyze the determinants for the stratifying surgical approach, evaluate the outcome, and postulate a management strategy.

**Methods:** This is a retrospective study of patients with ankylosing spondylitis who underwent surgery for cervical spine injury having a minimum follow-up of 2 years. The patients' demographic profile, neurological status, neurological recovery, and fracture pattern including translation and angulation, fracture classification, surgical duration, blood loss, and postoperative complications were recorded, and a comparative analysis of these factors between anterior, posterior, and combined surgical approaches was performed.

**Results:** Forty-three males were included in the study with a mean age of 57 years. Forty-nine percent underwent anterior only, 16% posterior only, and 35% underwent combined anterior and posterior stabilization. Mean operative time was found to be significantly lower in anterior only (81.4 minutes,  $p<0.05$ ), and posterior only (124 minutes,  $p<0.05$ ) approaches as compared to combined antero-posterior approaches (266.6 minutes). The mean blood loss was significantly lower in the anterior only (87.5 mL,  $p<0.05$ ) as compared to posterior only (714.7 mL) and the combined antero-posterior (912.7 mL) approaches. The mean translation and angulation in the patients who underwent anterior only, posterior only, and combined was 1.8 mm and 4.8°; 1.7 mm and 5.7°; and 3.7 mm and 7.7°, respectively. There was a statistically significant difference in the translation in the patients who underwent anterior and posterior alone ( $p<0.05$ ) compared to patients who

underwent the combined approach.

**Conclusions:** Our study provides insights into the management of cervical spine fractures in patients with ankylosing spondylitis. Our results, contrary to most literature, show that all the patients who underwent anterior approach had complete fracture healing and neurological recovery similar to patients who underwent posterior as well as combined approaches due to careful patient selection. Combined approach is the most preferred surgical technique; however, undisplaced fractures or fractures with a displacement  $\leq 2$  mm are amenable to successful outcomes following anterior-only procedures in the absence of concomitant injuries. Posterior surgeries are reserved for patients with similar fracture characteristics with injury in the cervico-thoracic region requiring instrumentation extending to the proximal thoracic spine as well as in patients having concomitant thoracic or thoracolumbar injuries requiring stabilization.

1339

### Curve Flexibility Assessment in Adolescent Idiopathic Scoliosis with Major Main Thoracic Curve: Comparison and Correlation between Physician-Supervised Supine Side Bending Radiographs versus Supine Computed Tomography Scan

Josephine Rebecca Chandren

*Department of Orthopaedic Surgery (NOCERAL), Faculty of Medicine, Universiti Malaya, Kuala Lumpur, Malaysia*

**Introduction:** Previous studies reported good flexibility correlation between side bending radiographs (non-physician supervised) and supine radiographs. However, there were none that compared curve flexibility between physician-supervised supine side-bending (PSSB) radiographs and supine imaging. Supine Cobb angle measurements for adolescent idiopathic scoliosis (AIS) patients can be obtained from available preoperative supine computed tomography (CT) scans.

**Purpose:** To compare and correlate the Cobb angle and flexibility assessments between PSSB and supine CT scans.

**Methods:** AIS patients with major main thoracic curves who underwent posterior spinal fusion between 2012 and 2021 were reviewed. Patients who had preoperative anteroposterior standing radiographs, PSSB radiographs,

and supine CT scans were recruited. Data collected/calculated were demographic data, Cobb angles, curve flexibility, side bending correction index (SBCI), and supine correction index (SCI).

**Results:** A total of 203 patients with mean age  $16.1 \pm 4.5$  years were included. The mean preoperative standing anteroposterior Cobb angle was  $75.6^\circ \pm 21.8^\circ$ . The mean Cobb angle was significantly smaller for PSSB ( $39.6^\circ \pm 22.9^\circ$ ) compared to supine CT ( $58.7^\circ \pm 20.2^\circ$ ) ( $p < 0.001$ ). The mean flexibility rate was significantly larger for PSSB ( $50.2\% \pm 18.2\%$ ) compared to supine CT scan ( $22.6\% \pm 10.8\%$ ) ( $p < 0.001$ ). The mean SBCI ( $1.4 \pm 1.0$ ) was significantly lower compared to SCI ( $3.5 \pm 4.0$ ) ( $p < 0.001$ ). Based on the Pearson correlation analysis, there were strong correlation for main thoracic Cobb angles between standing and PSSB ( $r = 0.867$ ,  $p < 0.001$ ); standing and supine CT ( $r = 0.899$ ,  $p < 0.001$ ); and PSSB and supine CT ( $r = 0.899$ ,  $p < 0.001$ ). There was moderate correlation for flexibility between PSSB and supine CT ( $r = 0.528$ ,  $p < 0.001$ ). However, there were no significant correlation between SBCI and SCI.

**Conclusions:** Supine CT scan generally correlated with PSSB radiographs and can be used for preoperative curve flexibility assessment in AIS patients.

1345

### Reducing Surgical Site Infections after Spine Surgery: The Optimal Amount of Normal Saline for Intra-Wound Irrigation

Shih-Tien Wang

*Kinmen Hospital, Ministry of Health And Welfare, Jinhu, Taiwan*

**Introduction:** Surgical site infection (SSI) following lumbar surgery can increase healthcare costs and ruin the success achieved through an operation. Irrigation of wounds with saline solution is widely accepted globally and safe for nearly all kinds of the surgical site. However, wound irrigation is still not addressed as a means of decreasing the incidence of SSI in elective surgery. The role and the optimal amount of intra-operative wound saline irrigation in preventing SSI in clean spinal surgery remain unclear. We aim to demonstrate that insufficient intraoperative irrigation may be a risk factor for postoperative SSI. Additionally, we investigated the optimal amount of normal saline for irrigation to prevent postoperative SSI.



**Methods:** Patients who had degenerative lumbar spine disease and had received open spinal fusion surgeries with at least 12 months of follow-up were retrospectively included from January 2015 through April 2020. A total of 193 patients were enrolled in the standard protocol group (irrigation with 2,000 mL normal saline) compared with 251 patients in the enhanced protocol group (irrigation with >6,000 mL normal saline). Based on our protocolized departmental guidelines, all patients received the same preoperative preparation, standard surgical steps, and postoperative care plan. Patients' demographic and surgical parameters were recorded. The main outcome measures included superficial wound infection, deep infection, and overall infection. The fusion status was accessed based on the Bridwell grading system at the final follow-up. Self-reported and clinical outcome measures include Visual Analog Scale and Oswestry Disability Index.

**Results:** The incidence of overall SSI was 4.66% in the standard protocol group and 1.59% in the enhanced protocol group. The univariate analysis revealed a significant difference in diabetes mellitus, irrigation amount per hour during surgery but not in age, body mass index, smoking, operative duration, fusion level, and blood loss. We determined the optimal irrigation amount during surgery as 1,400 mL per hour based on the receiver operating characteristic curve. This was statistically significant ( $p=0.033$ ) with an odds ratio of 9.284 (95% confidence interval, 1.2–72.0). In the analysis of surgical factors, the infection group had a significantly lower irrigation amount during surgery.

**Conclusions:** We observed that diabetes and insufficient intraoperative irrigation were both risk factors for postoperative SSI following degenerative lumbar spine surgery. To reduce SSI in lumbar spine surgery, intra-wound irrigation with more than 1,400 mL/hr of normal saline was recommended.

1422

## Subcrestal Iliac Screw Technique as an Alternative for Spinopelvic Fixation Technique: A Cohort Study of 73 Patients with a Modified Low Profile, Free Hand Technique for Insertion of Subcrestal Iliac Screw

Glenys Poon

*National University Hospital Singapore, Singapore*

**Introduction:** Spinopelvic fixation with iliac screws has been shown to provide biomechanical advantages of a more stable fixation and has seen increased usage in adult spinal deformity corrections. We have previously described a novel technique of subcrestal iliac screw placement where the iliac screw is inserted at the medial wall of the iliac crest, underneath the crest, and above the subcrestal iliac joint. This modified entry point allowed for several advantages including a low-profile screw head, free hand fluoroscopy free insertion, and avoidance of subcrestal iliac joint violation. This study aims to report the clinical and radiological outcomes of our cohort of patients who underwent the insertion of subcrestal iliac screws.

**Methods:** This was a retrospective cohort study, conducted at a single university hospital. All consecutive patients who had undergone iliac screw fixations with the subcrestal iliac screw technique were included. Patient demographics, operative details, pre- and postoperative clinical scores, and the presence of any radiological or clinical complications pertaining to the iliac screws were recorded and analyzed.

**Results:** A total of 73 patients underwent subcrestal iliac screw insertion, with a mean follow-up of  $25.1 \pm 30.2$  months with a minimum follow-up time of 6 months. The mean age was 63 years with 31.5 % males; 62 of the patients underwent iliac screw fixation as part of corrective surgery for degenerative scoliosis, while seven underwent fixation for spinal metastasis, four for traumatic spinal fractures, and one underwent the procedure for neuromuscular scoliosis correction. The majority of procedures were performed open (64.4%). The most common diameter of subcrestal iliac screws used was 8.5 mm (32.4%), with a mean length of 83.3 mm. Postoperatively, there was a statistically significant improvement in Visual Analog

Scale (VAS) back and VAS leg pain. The mean VAS back was 5.7 and the mean VAS leg was 4.46, and the mean VAS back improved to 1.13 ( $p<0.01$ ) and VAS leg 0.60 ( $p<0.01$ ). And 86.3 % had a 2-point decrease in VAS back and/or absence of back pain and 87.5% had a 2-point decrease in VAS leg and/or absence of leg pain. Implant related complications seen included iliac screw breakage (2.73%), rod breakage (6.84%), rod screw detachment (2.73%), and painful implant prominence (4.1%) of patients. Other notable complications included surgical site infections (2.73%), sacral fractures (2.73%), and gluteal pain (5.4%). A total of three patients required revision surgery; 2 (4.1%) underwent a revision for iliac screw and/or rod breakage with significant back pain, and the last underwent a revision for proximal construct complications.

**Conclusions:** The subcrestal iliac screw technique is safe and effective. This technique avoids the use of side connectors, resulting in lower construct complexity and costs. Importantly, it reduces entry point-related complications associated with traditional iliac screws but retains the advantages of the low-profile S2-alar-iliac screw.

1637

## The 'Disc-EndPlate-Bone-Marrow Complex' Classification: A Paradigm Shift in Our Understanding of the Modic Vertebral Endplate Changes

Shanmuganathan Rajasekaran

Ganga Hospital, Coimbatore, India

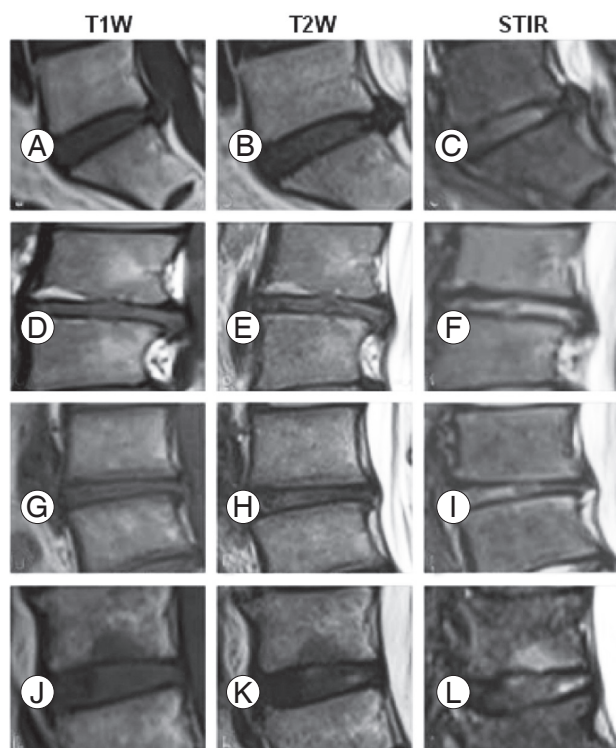
**Introduction:** With the current prominence and increased attention of the spine community on the end plate changes, it becomes important that we move forward and beyond the Modic change for accurate understanding. The disc, endplate (EP), and bone marrow region of the spine are a single anatomical and functional interdependent unit, but Modic classification (MC) is restricted to subchondral bone alone and uses only T1 and T2 sequences, which have poor reliability to differentiate fat from edema.

**Methods:** This was a retrospective analysis of prospectively collected clinico-radiological data performed with the approval of the institutional review board to study the EP changes and correlate them with clinical outcomes. A total of 445 consecutive patients who underwent whole

spine magnetic resonance imaging (MRI) for the distant brain, cervical, or thoracic spine injury formed the control group. And 1,085 consecutive patients presenting to the low back pain (LBP) clinic undergoing MRI formed the study group. All lumbar segments in the control and LBP groups were assessed for MC types. The same segments were also assessed with T1, T2, and short tau inversion recovery (STIR) images. A concept of "disc-endplate-bone-marrow" complex (DEBC) is proposed, and with the addition of STIR images, four activity stages were defined as type A (acute inflammation), type B (chronic persistence), type C (latent), and type D (inactive). A modifier H+ was added if there was a disc herniation. The classification was compared to MC and correlated to clinical outcomes.

**Results:** EPs ( $n=3,560$ ) of 445 controls and EPs ( $n=8,680$ ) in 1,085 patients with LBP were assessed; 560 EPs of MC-II and 22 EPs of MC-III were found to have edema in STIR or hyperintensity in discs needing reclassification to the previously undescribed type B of DEBC, which was found to be the most common (51.8%) (Fig. 1). The incidence between control and LBP of H+ (12% vs. 28.8%) and its co-occurrence with DEBC (3.5% vs. 23.3%) was significant ( $p<0.0001$ ). The odds of the patient requiring surgery was 0.66 in pure herniations without DEBC, compared to 2.6 with only DEBC, and the highest of 5.2 in patients having both DEBC and H+. Deep infection was 0.47% in non-DEBC, compared to 2.4% in patients with DEBC ( $p=0.002$ ), with maximum occurrence in type B.

**Conclusions:** The DEBC classification is a paradigm shift in our understanding of the so-called Modic EP changes by considering the DEBC as a whole. By the usage of STIR and the addition of disc intensity and EP erosions, 8.3% of patients in controls and 21.75% in the LBP group were reclassified to a previously undescribed "chronic persistence" (type B of DEBC) group, which had the highest incidence and influence for the need for surgery and infection. The addition of an H+ modifier was found to be critical as the co-existence of DEBC and H+ influenced treatment outcomes and the requirement for surgery and surgical infections. We believe that DEBC classification is an important advance in our understanding of the vertebral EP changes over the classical MC and will have a significant role in both clinical practice and research in disc diseases.



**Fig. 1.** Use of short tau inversion recovery (STIR) and disc hyperintensity in reclassifying Modic changes to disc-endplate-bone-marrow complex (DEBC) changes. (A–C) Non-Modic to DEBC type A due to STIR hyperintensity. (D–F) Modic 2 to DEBC type B due to disc hyperintensity. (G–I) Modic 3 to DEBC type B due to STIR and disc hyperintensity. (J–L) Modic 3 to DEBC type B due to STIR hyperintensity.

1651

## Efficacy of Vacuum-Assisted Closure in Postoperative Deep Spinal Infections: A Retrospective Analysis of 31 Patients with Spinal Instrumentation

Shanmuganathan Rajasekaran

Ganga Hospital, Coimbatore, India

**Introduction:** Surgical site infections following spinal surgery are potential detrimental complications that increase hospitalization and expenses, cause significant morbidity, and adversely affect the outcomes. Radical wound debridement, irrigation, and intravenous antibiotics are the conventional treatments for postoperative deep surgical site infection. Despite the best efforts, infections can persist. Our study aims to review the efficacy of the wound vacuum-assisted closure (VAC) system in treating deep surgical site infection after spine surgery with instrumen-

tation and exposed dura.

**Methods:** We retrospectively reviewed 31 patients who underwent VAC for postoperative spinal infections following spinal instrumentation between 2016–2020. The patient's demographic details and biochemical parameters were noted from the hospital information system, and imaging was analyzed by a picture archiving and communication system. Other pertinent information included bacterial culture reports and antibiotic sensitivity patterns, duration of VAC application, number of cycles of VAC application before final wound closure, complications, and infection recurrence were noted.

**Results:** There were 17 females and 14 males in the study population. There were 21 lumbar spine surgeries and five thoracic and five thoracolumbar spine surgeries. Following wound debridement, VAC was applied to all patients. A mean of 2.5 cycles of VAC application, each lasting 5–9 days, was applied before wound closure. Twenty-seven had positive bacterial cultures, and the rest were culture-negative. *Klebsiella* and *Pseudomonas* were the most prevalent organisms. One patient died due to an unrelated cause, and one patient with chronic viral hepatitis had increased blood loss following VAC. All the patients had good healing of wounds with a minimum follow-up of 12 months with no recurrence of infections. All patients except one had retained the implants.

**Conclusions:** The VAC system is a valuable tool in managing postoperative deep spinal infections. It allows for the retention of the instrumentation and eradication of infection. It is safe, reliable, and easy to use.

1769

## The Infection Control and Spinal Balance in Patients Receiving Percutaneous Endoscopic Debridement and Drainage for Infectious Discitis: A Retrospective Case Analysis

Hao-Wen Chen

Department of Orthopaedics, Hualien Tzu Chi Hospital, Hualien, Taiwan

**Introduction:** Thoracolumbar discitis could usually be treated non-operatively with antibiotics. However, rapid diagnosis and treatment are still essential to achieve infection control while preserving spinal stability and neurological function. Except for the gold standard, computed

tomography-guided biopsy and culture, percutaneous endoscopic decompression and drainage (PEDD) offered another unfolding technique for obtaining tissue while performing decompression for neurological symptoms. However, various diagnostic accuracy and the absence of research on subsequent spinal instability remain a controversial issue.

**Purpose:** To investigate the positive culture rate and impact on spinal instability in patients under PEDD for deteriorated discitis after initial antibiotic treatment.

**Methods:** From 2015 to 2018, 60 patients received PEDD for their deterioration of hemodynamic or neurologic status secondary to infectious discitis. After culture sampling, debridement, and drainage, the antibiotics were continued till the resolution of symptoms or normalization of the inflammatory biomarkers, erythrocyte sedimentation rate, and C-reactive protein. Besides, Visual Analog Scale, Oswestry Disability Index, and modified Macnab's criteria were evaluated preoperatively, 1 week, 4 weeks, 6 months, and 12 months postoperatively, representing the effectiveness of symptom relief. The positive culture rate was recorded as the diagnostic accuracy while the change of radiographic parameters was measured to evaluate the impact on the stability of the affected levels or global spine.

**Results:** Ninety-one percent of cases achieved symptom relief immediately postoperatively and 85% got infection controlled within 1 week postoperatively. There was 45% of cases found stably motion-preserved while 29% of cases got infected level fused at the last follow-up.

**Conclusions:** The favorable outcomes guaranteed the effectiveness of PEDD. Despite the significant local kyphotic change over the infectious level since 6 months postoperatively, sagittal vertical axis remained at a similar level representing the compensatory mechanism of the global spine. However, there is still 14% received instrumented fusion over lesion levels within 1 year after PEDD. Thus, whether concomitant fusion or not is still an issue of controversy and warrants further larger study to determine. Despite the technique demands, the minimally invasive nature, effectiveness on infection control, and symptom relief made PEDD an optimal strategy for certain patients who could not sustain traditional open debridement for discitis. Although no significant instability was found within 1 year postoperatively, the gradual local kyphotic change may warrant further study to identify the need for concomitant fusion.

## Course Abstracts for Free

028

### Effectiveness of Sublaminar Mersilene Tape-Augmented Pedicle Screws Fixation for Osteoporotic Vertebral Compression Fracture: Low-Cost Modality

Ghanshyam Kakadiya

*Topiwala National Medical college & BYL Nair Hospital, India*

**Introduction.** Gradually kyphosis and collapse are a natural history of osteoporotic vertebral compression fractures (OVCF). The principle of OVCF is fixing instability, providing anterior support, and decompression. The osteoporotic spine has weak and rarified trabeculae in the cancellous bone and pedicles, which offer little resistance against screw pull-out. The sublaminar implant relies on the lamina for holds which is the strongest part of vertebrae. The study's purpose was to assess the safety and efficacy of sublaminar mersilene tape-augmented pedicle screws fixation as a novel and low-cost modality for OVCFs instrumentation fixation.

**Methods:** A retrospective study of 40 consecutive patients of the OVCFs. All patients were operated on with open decompression, pedicle screw fixation, and sublaminar mersilene tape-augmentation. Preoperative and postoperative clinical (Visual Analog Scale [VAS], modified Oswestry Disability Index [M-ODI], neurologic deficit, revision surgeries, and infection) and radiological (axial collapse, fracture union, implant failure/back out) parameters were compared to describe the utility of sublaminar mersilene tape-augmented pedicle screws for OVCFs treatment.

**Results:** Complete neurological improvement was noted in 38 patients and two patients had Frankel Grade D neurology. The mean VAS was significantly improved from preoperative  $8.98 \pm 0.60$  to  $2.76 \pm 0.54$ , and M-ODI from  $80.10 \pm 6.90$  to  $15.30 \pm 6.90$  at the final follow-up. The mean local kyphosis angle was improved from  $23.20^\circ \pm 5.90^\circ$  preoperative to  $5.30^\circ \pm 3.9^\circ$  postoperatively and  $3.30^\circ \pm 2.50^\circ$  loss of correction at final follow-up. There was no pseudoarthrosis and implant failure noted. No iatrogenic dural or nerve injury.

**Conclusions:** Sublaminar mersilene tape-augmentation re-

lies on the lamina for its hold, which is the strongest part of an osteoporotic vertebra. Sublaminar mersilene tape-augmented pedicle screws fixation is a novel and low-cost modality for OVCFs. It provides significant improvement in clinical and radiological outcomes. This technique is an easy learning curve, user-friendly and safe, which makes this a viable alternative option for OVCFs fixation.

033

## Burden of Cervical Spinal Injury in India: The Untold Story

Deepak Agrawal

*All India Institute of Medical Sciences, India*

**Introduction:** Cervical spinal injuries are the most severe of all spinal cord injuries. And high cervical spine injuries may require lifelong ventilatory support leading to a huge burden to the healthcare system as well as society.

**Purpose:** To assess the magnitude as well as the epidemiology of cervical spine injuries in a tertiary care center in India over 1 year.

**Methods:** A retrospective study was conducted at Jai Prakash Narayan Apex Trauma Center, All India Institute of Medical Sciences, New Delhi over the period from 1 January 2019 to 31 December 2019. All patients with C-spine injuries getting admitted to the Neurosurgery department were enrolled in this study. Patients' clinical, radiological, and surgical details were evaluated. Telephonic follow-up was done for all patients after a minimum period of 12 months from injury.

**Results:** A total of 166 patients were treated for a C-spine injury in the study period. Of these, 141 were males and 25 were females (mean age: male, 34 years and female, 35 years). The mean interval for presentation in the emergency department (from injury) was 7.20 hours. Seventy-seven patients had complete spinal cord injury (SCI) (American Spinal Cord Injury Association [ASIA] grade A), 56 had an incomplete injury (ASIA B–D), and 33 were ASIA E. The cause of injury in 61.45% of cases (n=102) was a fall from height, 38% (n=63) were road traffic injuries, and one case was due to assault. And 61 (36%) patients required intubation and ventilation. Follow-up was available in 37 patients (22%) at a mean of 24 months. And 27% (n=15) of incomplete SCI patients and 11.5% (n=9) of complete SCI had improvement in ASIA grade at the last follow-up. The

overall mortality was 29% (n=48). Of these, 45 patients died in hospital and three died after discharge.

**Conclusions:** This is one of the largest series from a single center over 1 year and shows the enormity of the problem and the high mortality associated with such injuries.

181

## Remodeling of Facet Joint after Posterior Endoscopic Cervical Foraminotomy: Computer Tomographic Facet Dimension Analysis and Clinical Evaluation with Minimum 1-Year Follow-up

Pang Hung Wu

*Ng Teng Fong General Hospital, Singapore*

**Introduction:** There is limited literature on the medium-term of 2 years clinical and radiological facet dimensions outcomes in posterior cervical endoscopic decompression surgery in patients for cervical disc herniations and foraminal pathologies.

**Methods:** A retrospective comparative cohort study of 45 patients who underwent one level posterior endoscopic cervical foraminotomy (PECF) for degenerative cervical spinal conditions was evaluated. Basic demographics, preoperative, postoperative 1 week, 3 months and final follow-up of patients' clinical outcomes, Visual Analog Scale (VAS) pain score, Neck Disability Index (NDI), Japanese Orthopaedic Association score, MacNab's criteria, computer tomographic evaluation of three-dimensional (3D) computed tomography (CT) reconstruction coronal cut cervical resection area, sagittal cut foraminal cranio-caudal length, ventro-dorsal length, and axial cut ventro-dorsal length was evaluated.

**Results:** The mean follow-up for PECF is 17.24 months (range, 6–45 months). There are four complications (8.8%) in PECF. The mean operative time was 59.2 minutes (range, 40–80 minutes). The mean 3D coronal cut area was measured as 1,047.2 and 604.7 at postoperative day 1 and the final CT scan was done postoperative 1 year. In the final 1-year CT scan compared to the postoperative day 1 scan, there were statistically significant changes in (1) remodeling of the coronal 3D reconstructed area with a mean increment in bony area of  $442.6 \pm 248 \text{ mm}^2$ ; (2) sagittal CT cut foraminal cranio-caudal length was  $4.45 \pm 2.32 \text{ mm}$ ,  $2.06 \pm 2.38 \text{ mm}$  at postoperative day 1 and final,

respectively; (3) sagittal CT cut foraminal ventro-dorsal length was  $3.92 \pm 1.91$  mm,  $3.49 \pm 1.80$  mm at postoperative day 1 and final, respectively; (4) axial CT cut foraminal ventro-dorsal length was  $4.24 \pm 1.72$  mm,  $3.27 \pm 1.57$  mm at postoperative day 1 and final, respectively; and (5) axial CT cut foraminal mediolateral length was  $6.5 \pm 2.56$  mm,  $3.26 \pm 1.93$  mm at postoperative day 1 and final, respectively ( $p < 0.05$ ). PECD had better and statistically significant improvement at final follow-up for VAS ( $6.13 \pm 1.59$ ), NDI ( $52.44 \pm 12.79$ ), and motor power improvement ( $0.56 \pm 0.81$ ), respectively ( $p < 0.05$ ). Both cohorts had 100% good to excellent outcomes in MacNab criteria.

**Conclusions:** Despite remodeling in the facet joint with bony ingrowth and partial reformation of facet joint after PECD at final follow-up, there are continued improved clinical outcomes at final follow-up in 1–2 years after decompression.

## 293

### Sarcopenia in Paraspinal Muscle as a Risk Factor of Proximal Junctional Kyphosis and Proximal Junctional Failure after Adult Spinal Deformity Surgery

Jin Seong Park

*Department of Orthopaedic Surgery, Inha University Hospital, Incheon, South Korea*

**Introduction:** A number of risk factors have been reported to be associated with proximal junctional kyphosis (PJK) and proximal junctional failure (PJF) after long-instrumented fusion for adult spinal deformity. Adult spinal deformities are often accompanied by back muscle atrophy.

**Purpose:** The aim of this study was to identify the risk factors of PJK and PJF, including paraspinal muscle atrophy, and to compare the risk factors of the PJK and PJF.

**Methods:** Eighty-four consecutive patients who underwent a long-instrumented fusion for adult spinal deformities with a minimum follow-up of 2 years were included in the study. Patient, surgical, and radiographic factors were evaluated. Muscle volumes were measured using muscle/vertebra ratios of the multifidus (MF), erector spinae (ES), and psoas (PS) muscles, and muscle functions were assessed using a degree of fat infiltration at the L4–5 level.

**Results:** PJK occurred in 13 patients and PJF in 12. The combined PJK/PJF group consisted of 25 patients, and

the control group consisted of 59 patients without PJK or PJF. The mean durations to onset in PJK and PJF patients were 15.7 months and 1.7 months, respectively. No surgical or radiographic risk factors of PJK or PJF were significant by multivariate analysis. Comparisons of paraspinal muscle atrophy between the control group and PJK, PJF, or combined PJK/PJF groups revealed MF, ES, and PS had smaller volumes in the PJK/PJF group than in the control group. ES atrophy and fat infiltration were more severe in the PJF group than in the PJK group.

**Conclusions:** This study shows that PJF developed much earlier than PJK after surgery. Paraspinal muscle atrophy and fat infiltration in the lower lumbar region were identified as significant risk factors for PJK and PJF, especially PJF. The possibility of PJK and PJF development should be considered when planning long-level fusion in patients with paraspinal muscle atrophy.

## 363

### Effects of Teriparatide Alone versus Percutaneous Vertebroplasty on Pain Control and Radiographic Outcomes after Osteoporotic Vertebral Compression Fracture: A Matched Cohort Study

Po-An Chen

*Department of Orthopaedic Surgery, Chang Gung Memorial Hospital, Taiwan*

**Introduction:** Vertebroplasty has become common for osteoporotic vertebral compression fracture (OVCF) because of fast relief of pain and improvement of the quality of life. However, complications including refracture or subsequent spine fracture may be expected. Treatment with teriparatide (TPD) has been applied to enhance fracture healing. However, the efficacy of TPD on acute OVCF is not clear. The aim of this study was to investigate the efficacy of 3-month TPD and compare this treatment with vertebroplasty in terms of clinical and radiographic outcomes.

**Methods:** This is a retrospective matched cohort study. Patients who received conservative treatment with a back brace, analgesic agents, and at least 3-month TPD treatment (20 mcg/daily, subcutaneous) for OVCF with at least 1-year follow-up were included. Each enrolled TPD case was matched with two vertebroplasty cases using age and gender. Thirty TPD cases and 60 vertebroplasty cases

were enrolled. Patient-reported pain scores, Numeric Pain Rating Scale, were obtained at diagnosis and 1, 3, and 6 months after diagnosis. Radiographic parameters including middle body height, posterior body height, wedge angle, and kyphotic angle were measured at diagnosis and 6 months after diagnosis. Non-union fractures and subsequent vertebral fractures were evaluated at 6 months after OVCF was diagnosed.

**Results:** TPD treatment showed inferior pain relief to the vertebroplasty group at 1 month but it did not show the difference at 3 and 6 months after diagnosis. In TPD cases, progression of vertebral body collapse was noted in terms of middle body height and wedge angle at the final follow-up but only wedge angle reached statistical significance ( $p=0.00$ ). Instead, both middle body height ( $p=0.00$ ) and wedge angle ( $p=0.00$ ) increased significantly after the operation in the vertebroplasty group. Four TPD patients were diagnosed with fracture non-union (4/30, 13.3%) but only one patient received vertebroplasty due to persistent back pain. Subsequent vertebral fracture within 6 months was significantly higher in the vertebroplasty group (12/60, 20%) than in the TPD group (1/30, 3.3%).

**Conclusions:** In acute OVCF, 3-month TPD treatment alone showed comparable pain improvement and less subsequent spine fracture than vertebroplasty. Thus, this study suggested that 3-month TPD treatment could be a treatment option for OVCF.

364

## Comparison of Proximal and Distal Junctional Failures after Long Fusion Arthrodesis Stopping at L5: Incidences and Risk Factors

Sang-Il Kim

Department of Orthopaedic Surgery, Seoul St. Mary's Hospital, College of Medicine, The Catholic University of Korea, Seoul, South Korea

**Introduction:** Proper selection of fusion levels in adult spinal deformity (ASD) surgery is important not only to obtain the sagittal and coronal balance, but also to prevent progression of deformity and junctional problems. Junctional failures after long fusion stopping at L5 can present at both proximal and distal ends.

**Purpose:** To investigate the incidence and risk factors of proximal and distal junctional failures after long lumbar instrumented fusion stopping at L5 for ASD.

**Methods:** Sixty-three patients who underwent long fusion surgery stopping at L5 and had a minimum follow-up of 2 years were reviewed retrospectively. Proximal and distal junctional failures (PJF and DJF) were defined as newly developed back pain and/or radiculopathy with corresponding radiographic failures. The incidence and risk factors of each junctional failures were analyzed using a log rank test and the Cox proportional hazards model.

**Results:** Twelve men and 51 women were included in our study. The mean age was  $68.5\pm 7.0$  years and the mean follow-up period was  $84.5\pm 45.3$  months. PJF and DJF occurred in 17 patients (27%) and 16 patients (25.4%), respectively. PJF and DJF developed at a median of 32.1 months and 13.3 months, respectively; however, the difference was insignificant. Three patients presented both PJF and DJF, and in all three patients DJF proceeded PJF. The risk factors for PJF included less body mass index (BMI), higher preoperative lumbar lordosis (LL), and higher postoperative sagittal vertical axis (SVA) (hazard ratio [HR], 0.570, 1.055, 1.040, respectively). For DJF, higher preoperative SVA was an independent risk factor (HR, 1.010) (Table 1).

**Conclusions:** In our ASD patients who underwent long fusion surgery stopping at L5, PJF and DJF occurred in 17 patients (27%) and 16 patients (25.4%), respectively. PJF and DJF developed at a median of 32.1 months and 13.3 months, respectively. Whereas less BMI, higher preoperative LL, and higher postoperative SVA were risk factors for PJF, higher preoperative SVA was an independent risk factor for DJF.

**Table 1.** Risk factor analysis for junctional failures

Variable	Univariate analysis $p$ -value	Multivariate analysis	
		HR (95% CI)	$p$ -value
Proximal junctional failure			
Body mass index ( $\text{kg}/\text{m}^2$ )	0.002	0.570 (0.414–0.783)	0.001
Preoperative LL ( $^\circ$ )	0.121	1.055 (1.011–1.102)	0.013
Preoperative TK ( $^\circ$ )	0.024		
Postoperative TK ( $^\circ$ )	0.077		
Postoperative SVA (cm)	0.032	1.040 (1.017–1.063)	0.001
Distal junctional failure			
Preoperative SS ( $^\circ$ )	0.130		
Preoperative LL ( $^\circ$ )	0.021		
Preoperative PI–LL ( $^\circ$ )	0.030		
Preoperative SVA (cm)	0.026	1.010 (1.001–1.019)	0.026
Postoperative LL ( $^\circ$ )	0.022		
Postoperative PI–LL ( $^\circ$ )	0.106		

HR, hazard ratio; CI, confidence interval; LL, lumbar lordosis; TK, thoracic kyphosis; SVA, sagittal vertical axis; SS, sacral slope; PI, pelvic incidence.

366

## Clinical and Radiographic Outcomes of Late-Onset Cage Subsidence after Lateral Lumbar Interbody Fusion

Sang-Il Kim

Department of Orthopaedic Surgery, Seoul St. Mary's Hospital, College of Medicine, The Catholic University of Korea, Seoul, South Korea

**Introduction:** Lateral lumbar interbody fusion (LLIF) can restore disc height and perform indirect decompression of neural elements. However, cage subsidence may lead to clinical problems, including loss of disc height correction, altered spinal alignment, recurrent pain, and vertebral body fracture. The factors leading to subsidence after LLIF are poorly understood.

**Purpose:** The purpose of this study was to evaluate clinical and radiographic outcomes according to the subsidence in a case series with LLIF.

**Methods:** A retrospective review of consecutive patients who underwent LLIF between 2012 and 2017 was performed. Patients with a follow-up period of less than 1-year were excluded. Subsidence was defined as cage sinking of more than 2 mm from the bony endplate compared to the immediate postoperative status. The timing of cage subsidence was investigated. Clinical (using Visual Analog Scale [VAS] and Oswestry Disability Index [ODI]) and radiographic outcomes (sagittal parameters) were investigated. The relationships between cage subsidence, intraoperative endplate injury (IOEI), and fusion rate were analyzed.

**Results:** A total of 166 patients were eligible for this study. They underwent LLIF at a total of 331 levels and their mean follow-up period was  $54.5 \pm 23.3$  months. The subsidence rate per level was 37.5% (124/331). In patients with IOEI, subsidence occurred more frequently compared to those without IOEI (48.5% vs. 34.6%,  $p=0.034$ ). VAS and ODI at the final follow-up were not different between patients with or without the subsidence. Although a segmental sagittal angle was smaller at the level with subsidence, lumbar lordosis was not different between patients with or without subsidence at the final follow-up. The fusion rate at postoperative 1 year was not different. Reoperation was not needed except for one patient with a coronal split vertebral body fracture followed by IOEI and progressive subsidence.

**Conclusions:** The prevalence of subsidence after LLIF was quite high (37.5%) in our series. However, clinical and radiographic outcomes after subsidence were not unfavorable. Patients with intraoperative endplate injury were likely to show late-onset subsidence, however, the fusion rate was not affected. Late-onset subsidence did not seem clinically significant.

377

## Functional Recovery Priorities and Community Rehabilitation Service Preferences of Spinal Cord Injury Individuals and Caregivers of Chinese Ethnicity and Cultural Background

Paul Koljonen

The University of Hong Kong, Hong Kong

**Introduction:** Spinal cord injury (SCI) causes significant and permanent disability affecting motor, sensory, and autonomic functions. We conducted a survey on the priorities of functional recovery and preferences for community rehabilitation services in a cohort of Chinese individuals with SCI as well as primary caregivers. The study also investigated their views on advanced technology and research.

**Methods:** An online platform with a self-administered questionnaire was used to collect the opinions of clients that received services from an SCI follow-up clinic, a self-help association, or a non-government organization from 1 September to 31 December 2021.

**Results:** A total of 87 subjects (74 individuals with SCI: 48 tetraplegic, 26 paraplegic, and 13 caregivers) responded to the survey. Recovery of arm/hand function was given the highest priority among tetraplegics, followed by upper trunk/body strength and balance, and bladder/bowel function. The sexual function had a significantly lower ranking than all priority areas except normal sensation ( $p<0.05$ ). Paraplegics viewed bladder/bowel function as the most important area of functional recovery, followed by walking movement, upper trunk/body strength and balance, elimination of chronic pain, and regaining normal sensation. There was no statistically significant difference among the top priority areas ( $p>0.05$ ). In contrast to previous studies done in Western populations, the study revealed that sexual function was ranked as the lowest by all three groups of respondents (tetraplegics, paraplegics,



and caregivers). The majority of participants thought community rehabilitation services were inadequate. Most of the respondents were interested to try advanced technology which would facilitate their daily life and rehabilitation. About half of the individuals with SCI thought advances in technology and research could bring significant improvement in their quality of life in the coming 10 years.

**Conclusions:** This survey is the first study specifically looking into the recovery and rehabilitation priorities of a Chinese population of individuals with SCI. This is also the first study to also investigate the priorities of the primary caregivers of SCI individuals. The findings are useful as a reference for planning of future research and provision of rehabilitation services for the SCI community locally and in other parts of China.

414

## Change in Physical and Mental Well-Being between the Short- and Mid-Term Periods after Cervical Surgery for Myelopathy: A Retrospective Cohort Study with Minimum 5-Year Follow-up

Koji Tamai

*Osaka Metropolitan University, Osaka, Japan*

**Introduction:** The current study aimed to demonstrate the change in the mental and physical well-being of the patient with cervical spondylotic myelopathy (CSM) between short-term and mid-term follow-ups. Additionally, we aimed to determine the predictive factors at short-term follow-up for the deterioration of patient well-being after short-term observation.

**Methods:** This is a retrospective cohort study. Totally, 80 consecutive patients who underwent laminoplasty for CSM and followed up at least 5 years postoperatively were enrolled. The Short Form-36 Physical Component Summary (PCS) and Mental Component Summary (MCS) scores were considered as the parameters of physical and mental well-being. The “deterioration” of PCS and MCS was defined as a decrease of more than the minimum clinically important difference (4.0 points). Additionally, a multivariate logistic regression model was used to identify the predictive factors for deterioration after 2 years of surgery.

**Results:** The mental well-being of the patients who underwent surgery for CSM did not deteriorate after follow-up at 2 years postoperatively ( $p=0.912$ ). Meanwhile, physical well-being significantly declined between 2 and 5 years postoperatively ( $p=0.008$ ). In the regression model, the cervical Japanese Orthopaedic Association (cJOA) score at 2 years postoperatively was significantly associated with PCS deterioration after 2 years of follow-up, independent of age, sex, and PCS score at 2 years postoperatively ( $p=0.008$ ). In the receiver operating characteristic curve analysis, the optimal cutoff value was 13.0 (sensitivity, 86.8%; specificity, 56.1%). Therefore, patients with a cJOA score  $<13.0$  at 2 years postoperatively experienced a deterioration of PCS more frequently than patients with cJOA scores  $\geq 13$ .

**Conclusions:** The current results suggest that physicians continue follow-up for patients with a cJOA score  $<13$  for over 2 years. Furthermore, additional intervention may be planned for patients with a cJOA score  $<13$  at the short-term follow-up.

421

## Risk Factors for Conversion to Open Spinal Surgery after Percutaneous Epidural Neuroplasty

Hyung-Youl Park

*Department of Orthopaedic Surgery, Eunpyeong St. Mary's Hospital, College of Medicine, The Catholic University of Korea, Seoul, South Korea*

**Introduction:** Percutaneous epidural neuroplasty (PEN) is a minimally invasive therapy wherein a catheter is directly placed into different spine pathologies, and has reported to be safe and effective. However, prevalence and risk factors of conversion to open spinal surgery has not reported. Thus, the purpose of this study was to evaluate the risk factors for conversion to open surgery after PEN and suggest appropriate indication for PEN.

**Methods:** From 2019 to 2020, patients undergoing PEN for lumbar spinal stenosis or disc herniation on magnetic resonance imaging (MRI) were included in this study with a minimum 6-month follow-up and computed tomography (CT) scans to evaluate bony spur and hard disc. Radiologic parameters included the degree of central and foraminal stenosis on MRI, presence of spondylolisthesis,

hard pathology including facet joint calcification and hard disc on CT. Clinical outcomes included Numeric Rating Scale (NRS) for back pain and leg pain, and Oswestry Disability Index (ODI).

**Results:** Among the 63 patients, seven patients underwent open surgery within 6 months after PEN, and conversion to open spinal surgery was 11.1%. Mean time from PEN to open surgery was  $49.7 \pm 32.4$  days. Risk factors for conversion to open surgery were the grade of central stenosis, calcification of facet capsule or ligamentum flavum, and limited contrast spread within the canal (all  $p$ -value  $< 0.05$ ). Multivariate analysis revealed that independent risk factors were the calcification of facet capsule or ligamentum flavum (odds ratio [OR], 8.4; 95% confidence interval [CI], 0.85–83.4;  $p=0.045$ ) and intra-canal contrast spread (OR, 16.3; 95% CI, 2.3–114.9;  $p=0.005$ ). Regarding the clinical outcomes, NRS for back pain and leg pain and ODI at 1 month postoperatively were significantly greater in surgery group than non-surgery group despite similar preoperative values ( $3.1 \pm 2.0$  vs.  $7.2 \pm 3.9$  for back pain,  $3.0 \pm 1.9$  vs.  $9.0 \pm 1.7$  for leg pain,  $25.8 \pm 14.5$  vs.  $73.3 \pm 25.4$  for ODI; all  $p=0.000$ ).

**Conclusions:** Conversion to spinal surgery after PEN within 6 months was 11.1%. Calcified of facet capsule and ligamentum flavum and intra-canal contrast spread were the risk factors for conversion to open spinal surgery. Moreover, CT scans will be helpful for selection of patients having indication for PEN.

422

## Effect of Lumbar Spinal Stenosis on Treatment of Osteoporosis: Comparison of Three Oral Bisphosphonate Therapies

Hyung-Youl Park

*Department of Orthopaedic Surgery, Eunpyeong St. Mary's Hospital, College of Medicine, The Catholic University of Korea, Seoul, South Korea*

**Introduction:** Many studies have shown that lumbar spinal stenosis (LSS) causes various neurological symptoms and reduces the patient's daily activity, which can negatively affect bone mineral density (BMD) in patients with osteoporosis. The objective of this study was to investigate the effect of LSS on BMD in patients treated with three different oral bisphosphonates (ibandronate, alendronate,

risedronate) for newly diagnosed osteoporosis.

**Methods:** We retrospectively reviewed 1,521 consecutive patients treated with osteoporosis. Among them, 346 patients treated with oral bisphosphonates for 3 years were included in this study. Group I included 178 patients with osteoporosis alone, and group II included 168 patients with both osteoporosis and symptomatic LSS. We compared annual BMD and BMD improvements for 3 years between the two groups. Moreover, the therapeutic efficacies of three oral bisphosphonates in each group were also evaluated.

**Results:** The mean BMDs were similar in both groups at the initial and 1-year follow-up. However, the mean BMDs at 2- and 3-year follow-up were significantly higher in the group I than those in the group II. Annual and total changes of BMD were significantly higher in group I compared to group II ( $p < 0.05$  for all). In the group I, BMD change at 1-year and total changes were significantly higher in ibandronate and alendronate than in risedronate (0.34 vs. 0.34 vs. 0.16,  $p=0.002$  for BMD change at 1-year; 0.59 vs. 0.62 vs. 0.35,  $p=0.003$  for total change). In the group II, total change of BMD for 3-year was significantly greater in ibandronate than in risedronate (0.36 vs. 0.13,  $p=0.018$  at post-hoc test), while ibandronate and alendronate significantly increased BMD than risedronate at 1-year (0.23 vs. 0.24 vs. 0.07,  $p=0.017$ ).

**Conclusions:** This study revealed that symptomatic LSS may interfere with BMD improvement in the treatment of osteoporosis. Among the bisphosphonates, ibandronate was more effective in improving BMD than risedronate in patients with symptomatic LSS. Further trials are needed to validate these results.

479

## Surgical Complications and Incomplete Canal Widening of the Vertebral Body Sliding Osteotomy to Treat Cervical Myelopathy

Sung Tan Cho

*Department of Orthopaedic Surgery, Inje University Ilsan Paik Hospital, Goyang, South Korea*

**Introduction:** Vertebral body sliding osteotomy (VBSO) is a surgical technique that involves the anterior translation of the vertebral body with compressive lesions such as os-

sification of the posterior longitudinal ligament (OPLL), disc, or spurs. Fewer complications, improved lordosis restoration, and faster bone union with VBSO than corpectomy have been reported. However, data on the surgical complications of VBSO are lacking. Furthermore, VBSO achieves cord decompression through canal widening instead of complete removal of compressive lesions; thus, understanding the incidence and risk factors associated with incomplete canal widening is important. We, therefore, conducted this study to describe the incidence of VBSO-associated surgical complications and evaluate the incidence and risk factors of incomplete canal widening.

**Methods:** Patients who underwent VBSO to treat cervical myelopathy and were followed up for more than 2 years were retrospectively reviewed. C2–C7 cervical lordosis, C2–C7 sagittal vertical axis, and canal occupying ratio (COR) were measured. Patient-reported outcome measures including neck pain visual analog scale, neck disability index, Japanese Orthopaedic Association (JOA) scores, and surgical complications were recorded. Patients with preoperative COR <50% and COR ≥50% were compared. Logistic regression analysis was performed to identify factors associated with incomplete canal widening (postoperative COR >20%).

**Results:** Among the 109 patients, 60 (55.0%) were included in the COR <50% group and 49 patients (45.0%) in the COR ≥50% group. The most frequent complication was mild dysphagia (7.3%). Dural tears were observed in two patients (1.8%); one occurred during posterior longitudinal ligament resection and the other during foraminotomy. Two patients (1.8%) underwent reoperation due to radiculopathy from adjacent segment disease. Other complications are summarized in Table 1. Incomplete canal narrowing occurred in 21 patients (19.3%; postoperative COR, 24.8%±3.8%). Logistic regression analysis demonstrated that high preoperative COR was the only factor associated with incomplete narrowing (odds ratio, 1.063; 95% confidence interval, 1.008–1.122;  $p=0.024$ ). The amount of canal widening was significantly greater in the COR ≥50% group ( $p<0.001$ ); however, postoperative COR did not demonstrate a significant difference between the two groups ( $p=0.169$ ). The JOA recovery rate was significantly higher in the COR ≥50% group compared with the COR <50% group ( $p=0.005$ ).

**Conclusion:** Although VBSO aims to decrease the complication rate of corpectomy, it was not free of dural tears.

Special care would be required during ligament resection around OPLL masses. Incomplete canal widening occurred in 19.3% of patients, and high preoperative COR was the only risk factor for incomplete canal widening. However, greater canal widening occurred in the COR ≥50% group, leading to a higher JOA recovery rate; thus, high COR would not be a contraindication for VBSO. In conclusion, dural tears may still occur despite VBSO minimizing the need for OPLL lesion manipulation, so caution is warranted. Although high preoperative COR is a risk factor for incomplete canal widening, favorable clinical outcomes can be expected in patients with a COR ≥50%.

**Table 1.** Surgical complications

	Incidence (%)
Dural tear	2 (1.8)
Neurological deterioration	0
Infection	0
Reoperation	2 (1.8)
Graft dislodgement	0
Dysphagia	8 (7.3)
C5 palsy	5 (4.6)

482

## Curve Overcorrection Predicts Coronal Imbalance in Selective Thoracic Fusion in Adolescent Idiopathic Scoliosis

Jason Pui Yin Cheung

*Department of Orthopaedics and Traumatology, The University of Hong Kong, Hong Kong*

**Introduction:** Surgical treatment of adolescent idiopathic scoliosis (AIS) aims to correct deformity and maintain a balanced spine while minimizing the number of fused segments without risking deformity progression in the unfused spine. Selective fusion in Lenke type 1 curves is generally recommended but is associated with a risk of distal or proximal decompensation as well as a coronal imbalance. It is of interest to examine the frequency and cause of imbalance to optimize surgical results.

**Purpose:** To access the rate of coronal imbalance and identify possible reversible predictors of imbalance.

**Methods:** AIS patients with Lenke type 1 curve with A,

B, and C lumbar modifiers underwent selective thoracic fusion over a 20-year period. Radiographic variables were measured at the preoperative, immediate, and 2-year postoperative stages. From the standing whole spine posteroanterior radiograph, the following variables were measured: the tilt of the lower instrumented vertebra (LIV) and upper instrumented vertebra, major curve Cobb angle, apical translation of the main thoracic and lumbar curve, C7–central sacral vertical line deviation, trunk shift, radiographic shoulder height (RSH), fusion mass shift, fusion mass angle, and LIV disc angle. The curve fulcrum flexibility and fulcrum bending flexibility index (FBCI) were also studied. The coronal imbalance was defined as more than 2 cm of truncal shift or more than 2 cm list at the 2-year follow-up. The primary outcome was coronal imbalance at 2-year follow-up. Data were reported as proportions (%), mean±standard deviation, or median with range, and data distribution was assessed by histograms.

**Results:** A total of 301 patients were included in the study; 79% were lumbar modifier A, 11% were type B, and 10% were type C. A postoperative FBCI of more than 125% (third quartile) resulted in an odds ratio of 2.1 (95% confidence interval, 1.1–4.3) for coronal imbalance at 2 years ( $p=0.031$ ). At the 2-year follow-up, the mean FBCI was 102%±32% vs. 112%±30% ( $p=0.121$ ). And 189 patients (63%) showed coronal imbalance preoperatively; 78 patients were imbalanced at the postoperative stage. At the 2-year follow-up, 17/78 (21.8%) remained imbalanced. This imbalanced group showed lower preoperative flexibility (52%±15% vs. 65%±15%) and a higher postoperative FBCI (133%±32% vs. 118%±26%) ( $p=0.040$ ) compared to the 61 patients that corrected the imbalance. We saw no significant changes in fusion mass or LIV tilt. RSH changed from 16 mm in both groups at the postoperative stage to 11±7 mm vs. 7±6 mm in the balanced and imbalanced group at the 2-year follow-up ( $p=0.002$ ). Using a post-hoc test, we analyzed type B and C curves to assess which immediate postoperative variables were associated with truncal imbalance. The median FBCI was 109% (range, 46%–189%) in the balanced group and 133% (range, 105%–178%) in the unbalanced group ( $p=0.034$ ).

**Conclusions:** Coronal imbalance in type 1 AIS can be expected in 10% of cases. A decreased preoperative flexibility and an increase in FBCI are significantly associated with an increased rate of imbalance. Future studies may clarify whether the correction strategy should aim to “un-

der correct” less flexible curves or extend the fusion to address this issue.

---

**485**

## The Relationship between Compliance of Physiotherapeutic Scoliosis-Specific Exercises and Curve Regression with Mild to Moderate Adolescent Idiopathic Scoliosis

Jason Pui Yin Cheung

*Department of Orthopaedics and Traumatology, The University of Hong Kong, Hong Kong*

**Introduction:** Studies demonstrated the ability of physiotherapeutic scoliosis-specific exercises (PSSE) to lead to curve regression. It is crucial as such to determine the required exercise compliance (EC) to lead to regression. In addition, the effects of PSSE in causing vertebral morphology changes are unclear.

**Purpose:** To determine the requisite EC of PSSE for achieving curve regression; to analyze whether the apical translation (AT), apical wedging (AW), and apical rotation (AR) of the major curve improve with regression effect.

**Methods:** Between 2019 and 2021, a total of 763 patients undertook a 6-month PSSE treatment. This resulted in 426 compliant and 302 noncompliant patients remaining available for analysis. For compliant patients, 213 with curve regression and 213 age- and sex-matched with curve stabilization/deterioration at the 6 months were eligible for regression analysis to detect the relationship between EC and regression effect at the 6 months. Receiver operating characteristic curve analysis and Youden's index were applied to identify the threshold of EC leading to curve regression at the 6 months. The AT, AW, and AR of the major curve were compared before and after 6-month PSSE to investigate the radiographic parameters that improved with the regression effect.

**Results:** EC was correlated with regression effect (odds ratio, 19.9; 95% confidence interval, 11.3–35.0;  $p<0.001$ ) and the cutoff threshold of EC was 4.4 hr/wk for 6 months to realize such an effect. AT was improved by 47.6% with curve regression, in which 152 cases remained curve regression and no case progressed into the operative threshold at the 1.5 to 2 years.

**Conclusions:** A 6-month PSSE protocol of 4.4 hours per week was potentially leading to curve regression in treat-

ing mild to moderate scoliosis. An improvement in AT of the major curve was observed with the regression effect.

486

## Directed versus Non-directed Standing Postures in Adolescent Idiopathic Scoliosis: Its Impact on Curve Magnitude, Alignment, and Clinical Decision Making

Jason Pui Yin Cheung

Department of Orthopaedics and Traumatology, The University of Hong Kong, Hong Kong

**Introduction:** Proper positioning for radiographs is important to assess patients' usual functional posture in standing so that management strategies can be tailored to the standing alignment. To achieve better visibility of the sagittal alignment, it is recommended for example to have the patient standing upright with the arms slightly forward, elbows bent with fists on clavicles. Whether the natural posture of the patients affects coronal and sagittal radiological parameters remains unknown. Since patients acquire their relaxed posture during daily life rather than the directed position for spine radiographs, differences between non-directed posture and directed positioning may lead to Cobb angle and balance variations that warrant different treatment.

**Purpose:** To investigate the difference in major curve Cobb angle and alignment between directed and non-directed positionings during whole-body radiographs in adolescent idiopathic scoliosis (AIS) and to realize their clinical implication on treatment.

**Methods:** Patients with AIS presented for the first consultation at the tertiary scoliosis clinic were recruited and were asked to stand in two positions for their low-dose head-to-toe radiographs: non-directed, passive position; and directed position by a radiographer, confirming the chin, shoulder, and pelvis positions (Fig. 1). Radiological assessment included Cobb angle of major and minor curves, coronal balance (trunk shift, shoulder balance, pelvic obliquity, C7–central sacral vertical line deviation), sagittal balance and alignment, and spinopelvic parameters. Major curve Cobb angle difference  $>5^\circ$  between directed and non-directed positioning was considered clinically impactful, patients with or without such difference were compared. Over- or under-representation of

major curves  $25^\circ$  or  $40^\circ$  by non-directed positioning was examined for their relevance in clinical decision-making of bracing or surgery.

**Results:** A total of 198 patients (66.2% girls) were studied, with 22.2% experiencing major Cobb angle differences between positioning. Non-directed positioning presented with a smaller major Cobb angle than directed positioning (median difference,  $6.0^\circ$ ; upper and lower quartile,  $-7.8^\circ$  to  $5.8^\circ$ ). A major curve  $\geq 30^\circ$  was susceptible to Cobb angle difference between positioning. Patients with Cobb angle difference had changes in shoulder balance ( $p=0.007$ ), reduced sagittal vertical axis deviation ( $p=0.011$ ), increased lumbar lordosis ( $p=0.001$ ), and sacral slope ( $p<0.001$ ) when assuming directed position (Fig. 2). Non-directed positioning had 14.3% of major Cobb  $25^\circ$  under-represented and 9.9% over-representation, whereas 11.1% of  $>40^\circ$  curves were under-represented.

**Conclusions:** Strict adherence to radiographic standardized protocol is mandatory for reproducing spine radiographs reliable for curve assessment, as non-directed position demonstrates smaller Cobb angles. Postural variation may lead to an under-representation of the curve size relevant for bracing or surgical decision-making. Shoulder imbalance and pelvic obliquity relate to discrepancies in curve magnitude.

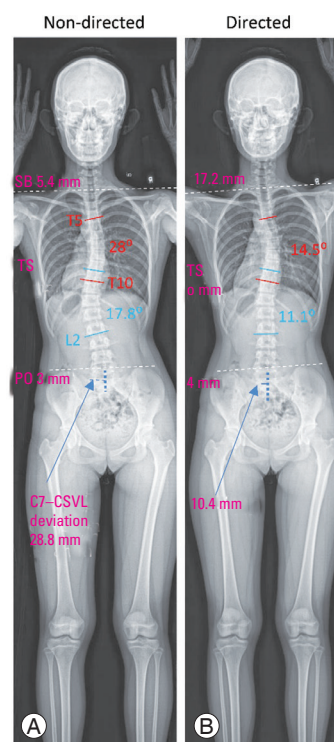


Fig. 1. Non-directed (A) and directed (B) positioning. CSVL, central sacral vertical line deviation; SB, sagittal balance; PO, pelvic obliquity; TS, trunk shift.

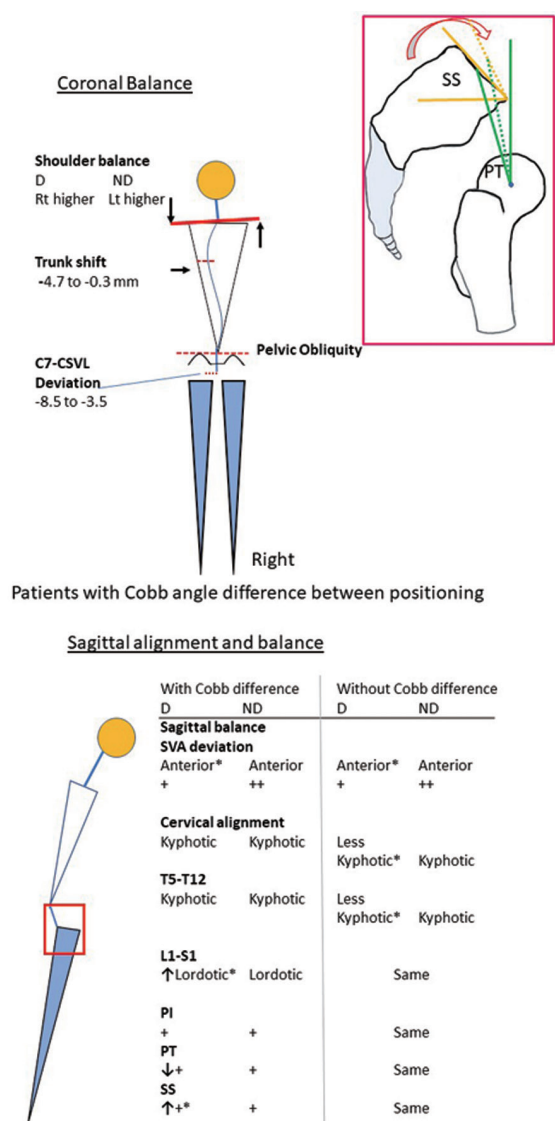


Fig. 2. Coronal and sagittal alignment differences in non-directed (ND) and directed (D) postures. CSVL, central sacral vertical line deviation; SVA, sagittal vertical axis; PI, pelvic incidence; PT, pelvic tilt; SS, sacral slope.

487

## Randomized Controlled Trial Comparing Immediate versus Gradual Brace Weaning for Adolescent Idiopathic Scoliosis

Jason Pui Yin Cheung

Department of Orthopaedics and Traumatology, The University of Hong Kong, Hong Kong

**Introduction:** For adolescent idiopathic scoliosis (AIS), bracing is the most common intervention for control-

ling curve progression and brace-wear is discontinued once the patient has reached the end of skeletal growth. However, it is unclear whether slow weaning with reduced hours of brace-wear or immediate brace removal results in better outcomes.

**Purpose:** To compare the degree of curve magnitude maintenance, truncal balance maintenance, and changes in health-related quality of life (HRQoL) between immediate and gradual brace weaning protocols via randomized controlled trial.

**Methods:** This prospective, open-labelled, randomized controlled trial included patients who underwent under-arm bracing and fulfilled brace weaning criteria of Risser stage  $\geq 4$ ,  $>2$  years post-menarche, and no bodily growth between 2 visits. Patients were randomly allocated into gradual weaning (brace-wear time shortened to night-wearing for 6 more months before complete weaning) and immediate brace removal. Assessment timepoints were post-weaning 6 months and 1 year. Patients were followed for at least 1-year post-weaning. Radiographic assessment included major and minor curve Cobb angles, truncal balance, and sagittal balance. The Scoliosis Research Society-22r (SRS-22r) questionnaire and the EuroQoL 5-Dimension 5-Level (EQ-5D-5L) were used for HRQoL assessment. Primary outcome was the change in Cobb angle from baseline to 6-month and 1-year follow-up. Secondary outcomes were the change in truncal balance, SRS-22r total score and EQ-5D utility score from baseline to follow-ups. Statistical analyses were performed according to intention-to-treat (ITT) and subordinately based on per-protocol (PP) principle. The PP analysis included all randomized patients in ITT who had no major protocol deviations. Primary analysis involved evaluating any differences in the Cobb angle change between baseline and follow-ups between the two protocols by independent sample *t*-tests.

**Results:** A total of 306 patients (82.4% girls) were consecutively recruited and randomized into gradual weaning ( $n=151$ ) and immediate weaning ( $n=155$ ) (Fig. 1). Gradual weaning patients had  $9.7 \pm 4.0$  hours night-time brace-wear. There were no intergroup differences ( $p > 0.05$ ) of patient demographics at baseline, including weaning major Cobb angle ( $30.4 \pm 8.3^\circ$  vs.  $29.1 \pm 8.6^\circ$  in PP,  $29.4 \pm 8.3^\circ$  vs.  $28.5 \pm 8.7^\circ$  in ITT). ITT and PP demonstrated similar intergroup comparison results. There were no differences of changes of major Cobb angle between gradual and immediate weaning at post-weaning 6 months and 1 year ( $2.0^\circ$

vs. 2.6°,  $p=0.285$ ). Changes of truncal shift, C7–central sacral vertical line and sagittal vertical axis deviation were of no difference between protocols (all at  $p>0.05$ ). Both groups experienced similar HRQoL changes, except gradual weaning having greater increase of Function domain score of SRS-22r by 0.11 ( $p=0.036$ ) at 1 year. No differences in curve progression were observed (gradual: 17.2% vs. immediate: 18.1%,  $p=0.846$ ). Similar curve regression rates occurred (gradual: 46/151 vs. immediate: 33/155,  $p=0.067$ ). Rebound at post-weaning 1 year was comparable (gradual: 24/151 vs. immediate: 17/155,  $p=0.206$ ) (Fig. 2). Those with/without rebound or progression in gradual weaning had similar hours of nocturnal brace-wear ( $8.7\pm 4.4$  vs.  $9.9\pm 3.9$ ,  $p=0.153$ ).

**Conclusions:** This randomized controlled trial indicates that gradual weaning and immediate weaning achieves similar brace outcomes in terms of curve magnitude maintenance and truncal balance, as well as patients’ HRQoL for the follow-up period since brace weaning. Thus, gradual weaning appears to have no obvious benefits over immediate weaning.

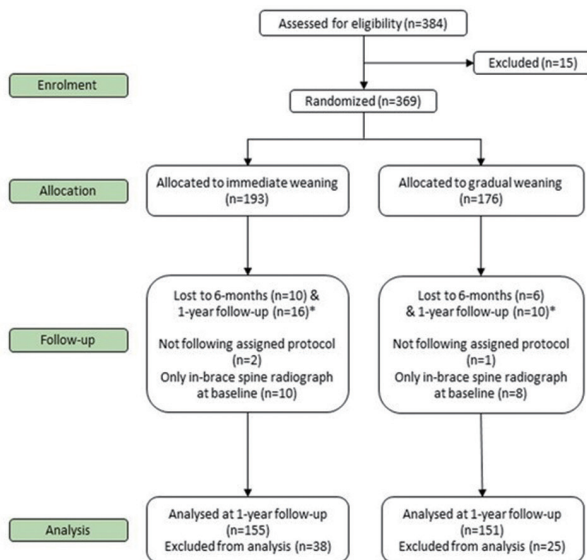


Fig. 1. Patient recruitment flowchart. a) Follow-up time-point occurred at coronavirus disease 2019 (COVID-19) pandemic.

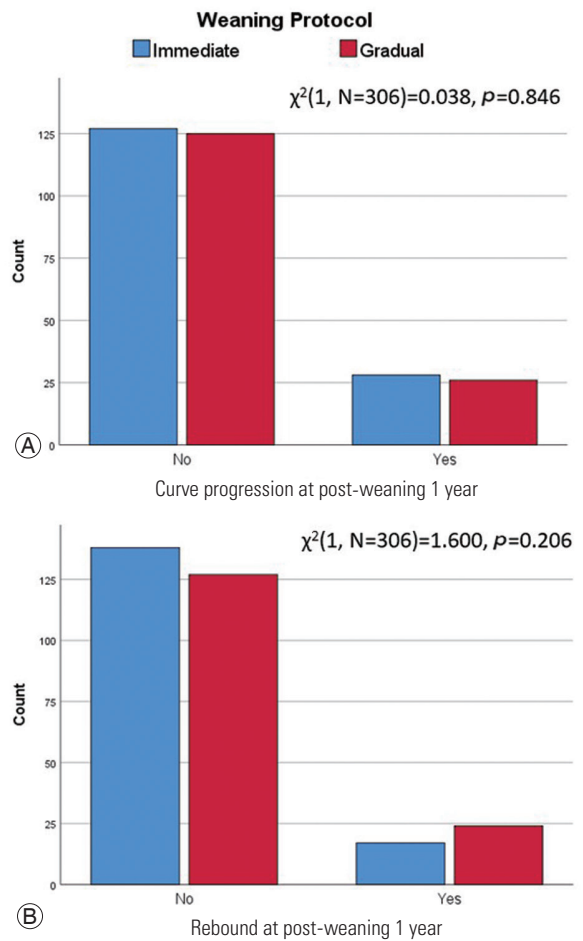


Fig. 2. Outcomes at 1-year post-weaning. (A) Curve progression at post-weaning 1 year. (B) Rebound at post-weaning 1 year.

491

**Male Patients with Longer Disease Duration of Axial Spondyloarthritis Have Less Severe Disc Degeneration**

Jason Pui Yin Cheung

Department of Orthopaedics and Traumatology, The University of Hong Kong, Hong Kong

**Introduction:** Low back pain is the leading cause of disability worldwide, age-related disc degeneration (DD) is highly prevalent in the population. Axial Spondyloarthritis (SpA) also causes backpain.

**Purpose:** To compare severity of DD in SpA patients versus the population, to determine the effect of Ankylosing Spondylitis Disease Activity Score-C-reactive protein (ASDAS-CRP), Spondyloarthritis Research Consortium of Canada spine score (SPARCC-spine), modified Stoke

Ankylosing Spondylitis Spine Score (mSASSS), and Bath Ankylosing Spondylitis Metrology Index (BASMI) on lumbar Pfirrmann score, and to assess demographic determinants for whole spine DD within SpA patients.

**Methods:** This study comprises of two prospective cohorts; 967 populational participants and 304 SpA patients were included into the analysis (42.7% male and 57.3% female). Disc and endplate measurements included any disc herniation, Pfirrmann grading, Schmorl's node, High Intensity Zone, and Modic change and were studied from C2/3 to L5/S1. Age, gender, weight, height, smoking history, and presence of current back pain were selected for the calculation of propensity-scores. And 219 match pairs were generated using 1:1 nearest neighbor matching. DD severity was assessed by sum of Pfirrmann scores in each segment, then compared using Mann-Whitney *U* test. SpA patients were stratified into early disease (<3 years) and later disease ( $\geq 3$  years). Univariate linear regression was then used to detect factors associated with worse lumbar Pfirrmann score. Factors with *p*-value <0.05 were then included into the multivariate model.

**Results:** SpA patients had better DD severity in all three spinal segments ( $p < 0.001$ ). Within the SpA cohort, disease activity (ASDAS-CRP) was not associated with DD presence in all segments ( $p = 0.495 - 0.800$ ). mSASSS, SPARCC spine magnetic resonance imaging (MRI) index, and BASMI were significantly higher in subjects with later disease. Male had higher SPARCC ( $p < 0.001$ ) and mSASSS ( $p < 0.001$ ) than female. In the disease-stage stratified multivariate linear regression for lumbar Pfirrmann score, SPARCC spine MRI index was associated with higher lumbar Pfirrmann scores in early disease ( $B = 0.196$ ,  $p = 0.044$ ), where mSASSS was associated with lower lumbar Pfirrmann scores in later disease ( $B = -0.138$ ,  $p = 0.038$ ). For whole spine DD, male had lower odds (odds ratio [OR], 0.622;  $p = 0.027$ ), where older age was associated with higher odds (OR, 1.095;  $p < 0.001$ ). In contrast, whole spine DD was independent from gender ( $p = 0.109$ ) in the populational cohort.

**Conclusions:** Female have a longer delay in diagnosis due to less recognized radiographic progression (mSASSS) in the lumbar spine, which also confers less stability and higher odds of DD in the whole spine. For male SpA patients with longer disease duration, a generalized increase of ankylosis means the spine is rather 'stable' and does not experience an 'increase in motion' or loading as in a high body mass index individual.

## 501

### The Triangular Osteosynthesis for Traumatic Spinopelvic Instability: A Consecutive Series

Luong Minh Quang

Saint Paul General Hospital, Hà Nội, Viet Nam

**Introduction:** Traumatic spinopelvic instabilities are rare and hard to diagnose and treat. Sacropelvic fractures with a H- or U-shaped line are severely unstable, due to a dissociation of the spine and of the upper body of the sacrum from the pelvis. They are commonly due to high-energy trauma events, with severe injuries in 80% of cases.

**Purpose:** To evaluate the clinical outcomes of traumatic spinopelvic instability (TSI) treated with triangular osteosynthesis.

**Methods:** A total of 25 consecutive patients of TSI were admitted to our hospital and included in the study from July 2018 to April 2022, and the medical records of patients were reviewed retrospectively. Patients were followed-up for at least 3 months. Fracture lines were evaluated using Denis, Isler, and Roy-Camille classification. Neuro-impairment was scored using Gibbon's classification and the clinical outcome of fracture was evaluated with Majeed function assessment at the last follow-up. The following data were also ascertained from the patient's medical records: gender, age, etiology, associated injuries, level of surgery, type of surgery, complications, and trauma mechanism.

**Results:** There were 19 men and six women with an average age of  $41.2 \pm 15.7$  years (range, 16–73 years). A total of seven cases were caused by falling, and 18 cases were caused by traffic accident. All sacral fractures had associated injuries. According to Denis classification, there were 11 cases of zone I, seven cases of zone II, and seven cases of zone III. According to Isler's classification, there were two cases of type I, three cases of type II, and two cases of type III. According to Roy-Camille classification, there were two cases of type I, three cases of type II, and two cases of type III. Sacro-iliac joint dissociation: there were six cases injured bilaterally and 11 cases injured unilaterally. Triangular osteosynthesis was applied for all patients with 14 cases bilaterally and 11 cases unilaterally. All patients were followed up continuously within an average of  $23.1 \pm 14.3$  months (range, 3–47 months). According to the Majeed function evaluation, 15 cases were classified as ex-



cellent, six cases as good, three cases as fair, and one case as bad. The average Gibbons score changed from  $1.2 \pm 0.2$  preoperatively to  $0.5 \pm 0.1$  postoperatively, which had a significant difference ( $t=2.19, p<0.05$ ). There were three of 25 cases needed internal pelvic arterial preop-embolization. Five cases of all suffered from surgical site infection, but only one patient needed debridement re-operatively.

**Conclusions:** The triangular osteosynthesis showed satisfactory outcomes in the treatment of TSI, which is recommended as an effective surgical choice.

503

### The Analysis of Treatment Failure Candidate after Preoperative Radiotherapy for Metastatic Spinal Tumor

Sang Yun Seok

*Department of Orthopaedic Surgery, Daejeon Eulji Medical Center, Daejeon, South Korea*

**Introduction:** Radiotherapy is one of the important treatment options for patients with metastatic spinal tumor. However, it is difficult to say that this is a definite treatment for metastatic spinal tumors, and there are patients who need surgical treatment because severe pain or neurologic deficits occurs even after radiotherapy. Therefore, this study aimed to analyze the patients who underwent surgical treatment after preoperative radiotherapy and check which patients had a high radiotherapy failure rate.

**Methods:** We included 81 patients who underwent decompression and fusion surgery after radiotherapy for metastatic spinal tumors. Patients who underwent surgery within 6 months after radiotherapy were classified as the failure group (group F,  $n=47$ ), while surgery cases after 6 months after radiotherapy were assigned to the effective group (group E,  $n=34$ ). Using magnetic resonance imaging before radiotherapy, the Bilsky grade, pathologic fracture, and cord compression were checked in both groups. Also, we analyzed the period from radiotherapy to surgery according to Bilsky grade.

**Results:** In group F, pathologic fracture and cord compression were more frequent than in group E ( $42/47$  vs.  $20/34$ ,  $42/47$  vs.  $23/34$ ;  $p=0.001, 0.015$ , respectively). In subgroup analysis, there was a difference in the period from radiotherapy to surgery according to Bilsky grade (Bilsky grade 0,  $n=17, 14.4 \pm 7.5$  months; grade 1,  $n=16, 7.4 \pm 6.1$  months;

grade 2,  $5.7 \pm 7.4$  months; grade 3,  $n=12, 1.5 \pm 1.1$  months).

**Conclusions:** Although this may be limited information on only patients who underwent surgery, radiotherapy failure is highly likely in patients with metastatic spinal tumor accompanied by Bilsky grade above 2, higher cord compression and pathologic fracture. In these patients, surgical treatment can be considered as the primary treatment.

507

### Comparison between the Bone Union Rates Using Auto-Iliac Bone and Bone Morphogenetic Protein without Auto Bone in a Posterior Atlantoaxial Fusion Procedure: Results from a Minimum 1-Year Follow-up

Sang Yun Seok

*Department of Orthopaedic Surgery, Daejeon Eulji Medical Center, Daejeon, South Korea*

**Introduction:** Traditionally, auto-iliac bone has traditionally been the gold standard for bone grafting in spinal fusion but has been replaced recently by recombinant human bone morphogenetic protein-2 (rhBMP-2) in several operations. Atlantoaxial bone fusions are challenging due to the biomechanical stress that arises at this level. Therefore, some concerns have been raised regarding bone fusion using rhBMP-2 without auto bone in a posterior atlantoaxial fusion procedure. This study was conducted to (1) compare the bone union rates achieved with an auto-iliac bone graft and rhBMP-2 without the auto bone and (2) check to potential advantages and disadvantages of rhBMP-2 as bone graft material in posterior atlantoaxial fusion procedures.

**Methods:** The study included 103 patients who underwent a posterior atlantoaxial fusion due to a C1–2 pathology. As bone graft material, using an auto-iliac bone graft was assigned to the iliac bone graft group (group I,  $n=68$ ), while cases involving rhBMP-2 without auto bone were assigned to an rhBMP-2 group (group B,  $n=35$ ). We evaluated the bone unions in these cases using postoperative 1-year dynamic radiographs (flexion and extension position) and computed tomography (CT). To check atlantoaxial bone fusion, we analyzed pseudomotion in postoperative dynamic radiographs and bone bridge formation, facet joint fusion, and metal loosening in postoperative

CT, respectively. Additionally, we analyzed and compared the demographic, operative, and clinical factors between the two groups of patients.

**Results:** No significant differences were evident between the bone union rates using 1-year dynamic radiographs in groups I and B (66/68, 97.0%, vs. 34/35, 97.1%, respectively;  $p=1.000$ ). However, the bone union rates using 1-year CT in group I are higher than group B (59/68, 86.7% vs. 18/35, 51.4%, respectively;  $p<0.001$ ). Additionally, the operation time is longer in group I than in group B (189.4±39.0 minutes vs. 102.6±20.9 minutes,  $p<0.001$ ). And, the hospital stay length also is longer in group I than group B (9.8±4.1 vs. 7.7±4.8,  $p=0.048$ ). Persistent pain at the graft site during 1 year was reported in 20.6% (14/68) of patients in group I. Although clinical outcomes improved postoperatively in both groups, no inter-group differences were observed.

**Conclusions:** There was no significant difference in the bone union rate on dynamic radiographs between two auto-iliac bone grafts and rhBMP-2 without auto bone. Additionally, there was no difference in the clinical outcomes. Considering the advantages including decreased operative times, shorter hospital stay, and donor site morbidity, rhBMP-2 has advantages as a grafting choice for a posterior atlantoaxial fusion procedure. But this study also demonstrated that definite bone bridge formation and facet joint fusion on postoperative CT was less checked in the rhBMP-2 without auto bone group. Therefore, a long-term follow-up is also required in posterior atlantoaxial bone fusion using rhBMP-2 without auto bone.

**Table 1.** The demographic and operative factors between two groups.

Characteristic	Group I (n=68)	Group B (n=35)	p-value
Age	57.1±17.6	60.0±14.6	0.512
Sex (%)			0.322
Male	28 (41.2)	18 (51.4)	
Female	40 (58.8)	17 (48.6)	
Body mass index (kg/m <sup>2</sup> )	23.6±3.6	24.4±4.0	0.406
Bone mineral density (spine) (g/cm <sup>2</sup> )	-1.7±1.3	-1.3±1.8	0.707
Smoking (%)	2 (13.7)	3 (19.3)	0.334
Operation time (min)	189.4±39.0	102.6±20.9	<b>&lt;0.001</b>
Hospital stays (day)	9.8±4.1	7.7±4.8	<b>0.048</b>
Donor site pain	14 (20.6%)		
Fever >37.5°C (%)	19 (27.9)	9 (25.7)	0.810
C-reactive protein in postoperative 3 days	3.7±3.6	2.4±4.7	0.229

Values are presented as mean±standard deviation or number (%). Statistically significant results are marked in bold.

**Table 2.** The radiologic and clinical factors between two groups

Variable	Group I (n=68)	Group B (n=35)	p-value
Bone union in dynamic radiographs (%)	66 (97.0)	34 (97.1)	1.000
Computed tomography (%)			
Bone bridge	55 (80.8)	14 (40.0)	<b>&lt;0.001</b>
Facet joint fusion	12 (17.6)	5 (14.3)	0.663
Metal loosening	1 (1.4)	0	1.000
Bone union	59 (86.7)	18 (51.4)	<b>&lt;0.001</b>
Preoperative VAS-N	3.9±2.5	4.1±2.9	0.783
Postoperative VAS-N	1.9±1.7	2.2±1.5	0.590
Preoperative NDI	16.3±10.0	15.9±6.8	0.887
Postoperative NDI	9.7±7.6	11.2±10.3	0.776

Values are presented as number (%) or mean±standard deviation. Statistically significant results are marked in bold.

VAS-N, Visual Analog Scale for neck pain; NDI, Neck Disability Index.

## 533

### Radiographic Analysis of Early Changes in Upper Adjacent Segments after Fusion Surgery: Oblique Lumbar Interbody Fusion versus Posterior Lumbar Interbody Fusion

Joo Young Lee

Department of Orthopaedic Surgery, Asan Medical Center, Seoul, South Korea

**Introduction:** Recently, oblique lumbar interbody fusion (OLIF) is one of the most frequently performed lumbar fusion surgery technique. The purpose of this study was to compare the early radiological changes of upper adjacent segment between OLIF without laminectomy and posterior lumbar interbody fusion (PLIF).

**Methods:** This was a retrospective comparative study. Between 2013 and 2020, group P (PLIF, n=131) and group O (OLIF, n=65) were recruited as matched pairs (Table 1). Each patient underwent plain upright whole spine lateral radiography preoperatively, 3 days, 1, 3, 6 months, and 1 year postoperatively. Radiographic outcomes (lumbar lordosis, upper adjacent segmental lordosis, retrolisthesis, and foraminal height) were measured at each time point, and changes in values from the preoperative value were noted and used for the study. Patient-reported outcome measures were obtained preoperatively and 1-year follow-ups.

**Results:** Group O was superior to group P with respect to its capability to restore lumbar lordosis (O: 4.03°±4.38°, P: 1.63°±5.11°;  $p=0.001$ ) and surgical segmental disc height

(O: 5.50±3.39 mm, P: 2.71±2.18 mm;  $p<0.001$ ) in 1 year after surgery (Fig. 1). However, group O showed an increase in upper adjacent segmental lordosis at 3 days postoperatively (O: 1.8°±4.39°, P: 0.08°±3.35°,  $p=0.001$ ) and showed a significant increase in the incidence (O: 76.9%, P: 24.6%;  $p<0.001$ ) and degree of retrolisthesis (O: 1.69±1.09 mm, P: 0.29±0.70 mm,  $p<0.001$ ) of the upper adjacent segment, and a decrease in the foraminal height of the upper adjacent segment (O: -1.43±2.12 mm, P: 0.54±2.53 mm,  $p<0.001$ ) at 1 month postoperatively (Fig. 2).

**Conclusions:** OLIF shows a superior ability to PLIF in the recovery of lumbar lordosis and surgical segmental disc height. However, it causes radiographic deterioration in retrolisthesis, segmental lordosis, and foraminal height of the upper adjacent segment after surgery. It seems that stress on the upper segment appears to cause several radiological changes in the upper adjacent segment. During fusion surgery, it should be considered that an excessive increase in disc height and lumbar lordosis of the surgical segment may cause early degenerative changes due to stress in the upper adjacent segment. Although it was not possible to confirm the clinical difference related to this in short-term follow-up observation, attention should be paid to the difference to be brought about in long-term follow-up observation.

**Table 1.** Comparison of demographics between groups O and P

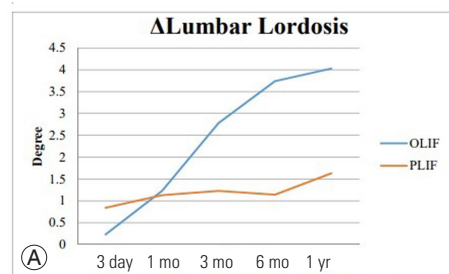
Characteristic	Group O	Group P	p-value
No. of cases	65	136	
Age (yr)	65.07±8.22	63.41±7.68	0.133
Sex			0.614
Male	16	39	
Female	49	97	
Smoking			0.880
Non-smoker	33	65	
Smoker	32	71	
Level			0.997
L3-4	10	22	
L4-5	35	74	
L3-4-5	20	40	
Lumbar lordosis (°)	50.75±8.23	48.35±12.78	0.502
Pelvic incidence (°)	53.47±10.70	51.83±10.64	0.216
Disc height (mm)	7.80±3.16	7.91±2.44	0.487
Upper adjacent segmental radiologic parameters			
Foraminal height (mm)	19.53±2.05	20.1±3.01	0.194
Segmental lordosis (°)	8.15±3.18	7.75±3.88	0.379
Flexibility (°)	7.64±2.05	7.49±3.88	0.515

(Continued on next page)

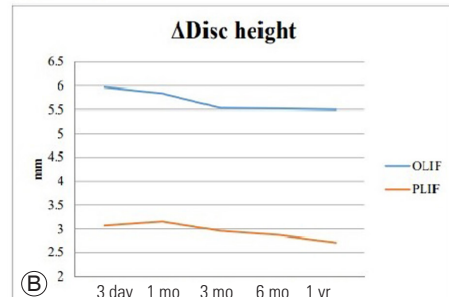
**Table 1.** Continued

Characteristic	Group O	Group P	p-value
Disc degeneration (Pfirrmann grade)	2.33±0.62	2.44±0.59	0.267
Facet sagittalization (°)	69.16±9.04	71.19±12.62	0.259
Facet degeneration (Weishaupt grade)	2.16±0.69	2.36±0.48	0.085
Patient outcomes			
Oswestry Disability index (%)	48.71±8.23	45.39±10.39	0.81
Back pain VAS	5.47±2.71	5.98±2.69	0.75
Leg pain VAS	8.51±1.16	7.61±1.94	0.63

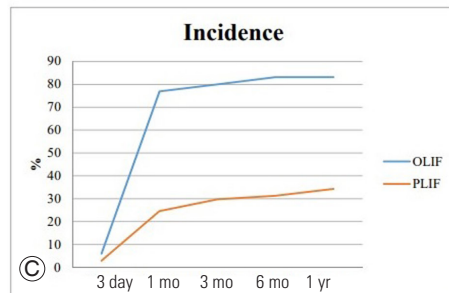
Values are presented as number or mean±standard deviation. O, oblique lumbar interbody fusion; P, posterior lumbar interbody fusion; VAS, Visual Analog Scale.



ΔLL	3days	1month	3months	6months	1 year
OLIF	0.23±4.11	1.23±4.26	2.78±4.32	3.74±4.13	4.03±4.38
PLIF	0.84±6.70	1.13±4.87	1.23±5.71	1.14±5.06	1.63±5.11
p-value	0.609	0.495	0.036*	<.000*	0.001*



Δdisc height	3days	1month	3months	6months	1 year
OLIF	5.97±3.14	5.84±3.07	5.53±3.53	5.52±3.45	5.50±3.59
PLIF	3.07±2.20	3.16±2.33	2.96±2.32	2.87±2.33	2.71±2.18
p-value	<.000*	<.000*	<.000*	<.000*	<.000*



%	3days	1month	3months	6months	1 year
OLIF	6.1	76.9	80	83.1	83.1
PLIF	2.9	24.6	29.8	31.3	34.3
p-value	.12	<.000*	<.000*	<.000*	<.000*

**Fig. 1. (A-C)** Comparison of postoperative radiological outcomes of between groups O and P. Disc height, surgical segmental disc height; Incidence, incidence of upper adjacent segmental retrolisthesis; OLIF, oblique lumbar interbody fusion; PLIF, posterior lumbar interbody fusion.

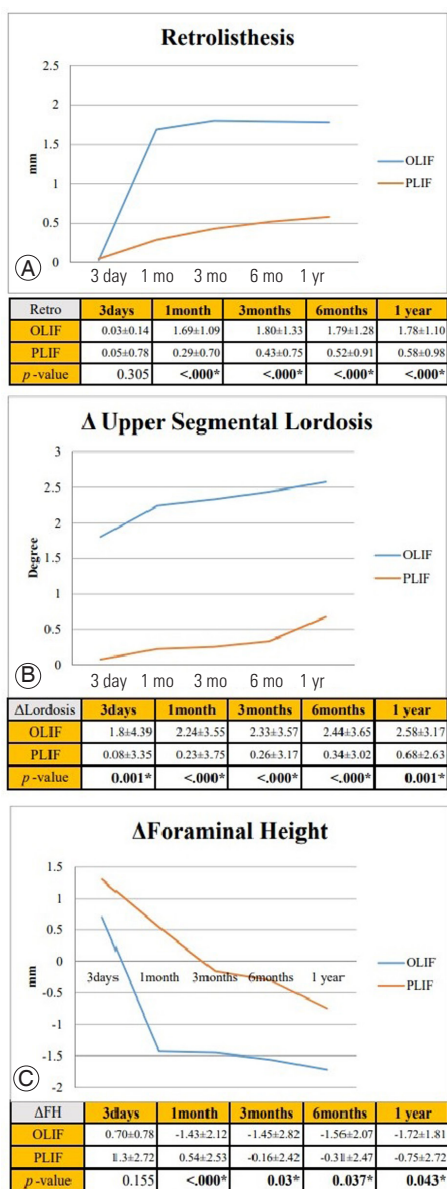


Fig. 2. (A–C) Comparison of postoperative radiological outcomes of upper adjacent segment between groups O and P. OLIF, oblique lumbar interbody fusion; PLIF, posterior lumbar interbody fusion.

## 553

### Minimally Invasive Spine Surgery: Techniques, Technologies, and Indications for Thoracolumbar Spine Fracture

Sarwar Jahan

National Institute of Traumatology & Orthopedic Rehabilitation (NITOR), Dhaka, Bangladesh

**Introduction:** Over the past few decades, interest in minimally invasive spine surgery (MISS) has increased tremendously due to its core principle of minimizing approach-related injury while providing outcomes similar to traditional open spine procedures. With technical and technological advancements, MISS has expanded its utility not only to simple spinal stenosis, but also to complex spinal pathologies such as metastasis, trauma, or adult spinal deformity. In this series, we have reviewed techniques and technology in MISS and outlined the results in comparison with traditional open spinal surgeries.

**Methods:** In this prospective observational study, a total 21 cases were included from January 2022 to August 2022 through non randomized purposive sampling. All the patients were between 15 to 60 years of age and operated within 10 days of fracture by MISS techniques; short-segment pedicle screw fixation including the fractured vertebral body. Postoperative functional outcome was assessed both clinically by Oswestry Disability Index, Visual Analog Scale, American Spinal Cord Injury Association scale, and Denis work scale and radiologically by Cob's kyphotic angle, kyphotic deformation, Beck index, and Bridwell criteria. Postoperative follow-up was conducted at 6th, 12th, and 24th weeks.

**Results:** The mean age found in 31.42±11.2 years with male predominant (74.19%). Most of the cases were manual workers (51.61%). FFH was the most common cause of injury (80.65%) and L1 was the most common level of injury (54.84%). The mean duration between injury and operation time was 5.45±2.34 days. None of cases deteriorated.

**Conclusions:** The main goal of MISS is to minimize approach-related soft tissue injury and to preserve normal anatomy, which permit a better quality of life through faster postoperative recovery. Over the past few decades, significant technological and technical advancements have made this goal possible.

591

## Feasibility of Lateral Mass Screw Insertion in the Risky Triad of C1: Comparison of the Over the Arch Technique to the Conventional Techniques

Hyung Rae Lee

Department of Orthopaedic Surgery, Uijeongbu Eulji Medical Center, Uijeongbu, South Korea

**Introduction:** There are some situations in which screw insertion to the C1 lateral mass is not possible with conventional techniques such as posterior arch (PA) and inferior lateral mass (ILM) screws (Fig. 1). The three types of atlas bony deformities that hinder the use of conventional screws may be referred to as the “risky triad of C1”: (1) a very small height of the PA ( $\leq 3.5$  mm), (2) a caudally tilted PA blocking the inferior part of C1 lateral mass, or (3) a loss of height at the ILM ( $\leq 3.5$  mm). In these situations, surgeons might be required to consider salvage techniques such as occipitocervical fixation (OCF). However, a sacrifice of about 20° range of motion in cervical flexion/extension and complications related to horizontal gaze may occur when using the OCF. We applied screws at the superior lateral mass (SLM) of the C1 in patients with deformed PA and ILM (Fig. 2).

**Methods:** We reviewed the medical records of 60 patients who underwent C1 screw fixation using the over-the-arch (OTA) technique (13 screws) and PA/ILM technique (107 screws) between 2011 and 2019. Vertebral artery (VA) injuries, screw malposition, and bony union were radiologically assessed. Clinical outcome measures including Neck Disability Index (NDI), Japanese Orthopaedic Association (JOA), and occipital neuralgia were recorded.

**Results:** Thirteen OTA screws were successfully inserted without any major complications. The NDI and JOA scores did not show significant differences between the two groups at the final follow-up. There were no VA injuries recognized during screw insertion. There was no evidence of ischemic damage to the VA or bony erosion in the occiput or atlas. Medial wall violation was observed in one screw (7.7%); however, no C0–1, C1–2, or lateral wall violations were observed. No patients developed new-onset neuralgia postoperatively after C1 fixation using the OTA technique.

**Conclusions:** The OTA technique was safe and useful for

C1 screw fixation, and may thus be used to avoid extended OCF when conventional screw insertion is not feasible.

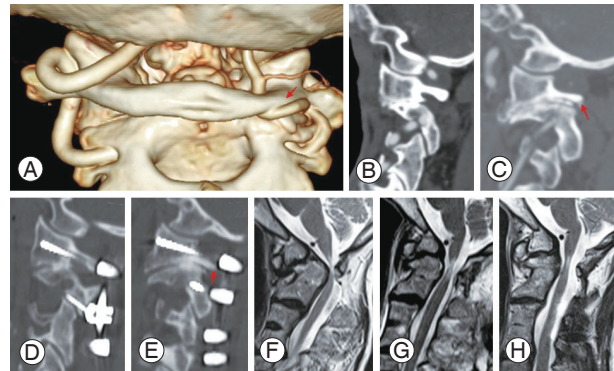


Fig. 1.

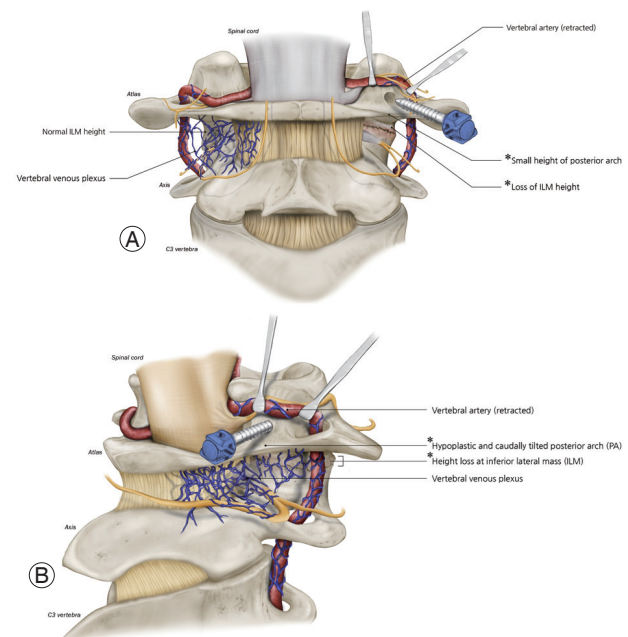


Fig. 2.

593

## Predictive Factors for the Aggravation of Cervical Alignment after Posterior Cervical Foraminotomy

Hyung Rae Lee

Department of Orthopaedic Surgery, Uijeongbu Eulji Medical Center, Uijeongbu, South Korea

**Introduction:** Posterior cervical foraminotomy (PCF) is a common surgical option for cervical radiculopathy that maintains cervical mobility by avoiding the fusion of mo-

tion segments. However, PCF has the risk of progression to cervical kyphosis, likely arising from procedure-related injuries on the facet joint and musculature. Age and preoperative hypo-lordosis have been regarded as risk factors for postoperative cervical kyphosis; however, recent studies suggested that hypo-lordosis in patients with cervical radiculopathy may be a temporary finding resulting from a positive Spurling's sign. Therefore, we investigated the risk factors for the aggravation of cervical alignment after PCF and identified their relationships with aggravation in cervical curvature.

**Methods:** The medical records of 98 patients who underwent PCF for unilateral radiculopathy and followed for >2 years were retrospectively reviewed. Segmental angle, cervical angle (CA), Pfirrmann grade, foraminal stenosis, and clinical outcomes including neck pain, arm pain, and Neck Disability Index were assessed. To identify the predictors for postoperative kyphotic changes, the patients were divided into two groups based on postoperative changes in the Cobb angle at C2–C7. Radiological and clinical outcomes were compared between groups C (control group; CA kyphotic change <5°) and K (kyphotic group; CA kyphotic change ≥5°). Univariate and multivariate linear regression analyses were used to identify the risk factors for the kyphotic changes in CA. Pearson's correlation coefficient analysis was used to determine the relationships between the risk factors and the kyphotic changes in CA.

**Results:** Group K was significantly older than group C ( $p=0.002$ ) and had a higher Pfirrmann grade ( $p=0.025$ ) (Fig. 1). In group K, neck pain was significantly increased at the last follow-up ( $p<0.001$ ). Univariate and multivariate linear regression analysis revealed that kyphotic changes of CA were significantly related to older age ( $p=0.016$ ,  $B=0.420$ ) and higher Pfirrmann grade of operative levels ( $p=0.032$ ,  $B=4.560$ ). Previously reported risk factors such as T1 slope and C2–C7 sagittal vertical axis had no significant relationship to kyphotic changes of CA. Pearson correlation analysis showed that both age ( $r=0.487$ ,  $p<0.001$ ) and Pfirrmann grade ( $r=0.249$ ,  $p=0.027$ ) had a significant relationship with the kyphotic changes in CA. Receiver operating characteristic curve analysis showed that the cut-off value of Pfirrmann grade was 3.417 for kyphotic changes in CA of ≥5° ( $p=0.008$ , area under the curve=0.703, sensitivity=91%, specificity=59%) (Fig. 2).

**Conclusions:** Our results showed the potential utility of the preoperative measurement of Pfirrmann grade for

assessing the risk of aggravation of cervical alignment following PCF. Although preoperative cervical alignment has been used for estimating postoperative kyphotic changes, independent risk factors for kyphotic changes in cervical curvature may be more useful in clinical situations. Collectively, our results suggest that careful consideration should be taken when treating older patients with a Pfirrmann grade higher than IV for disc degeneration.

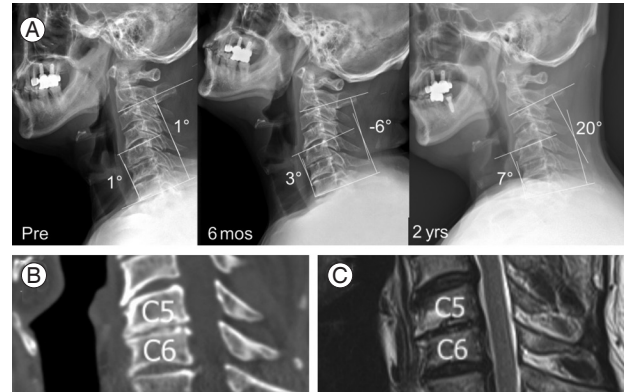


Fig. 1.

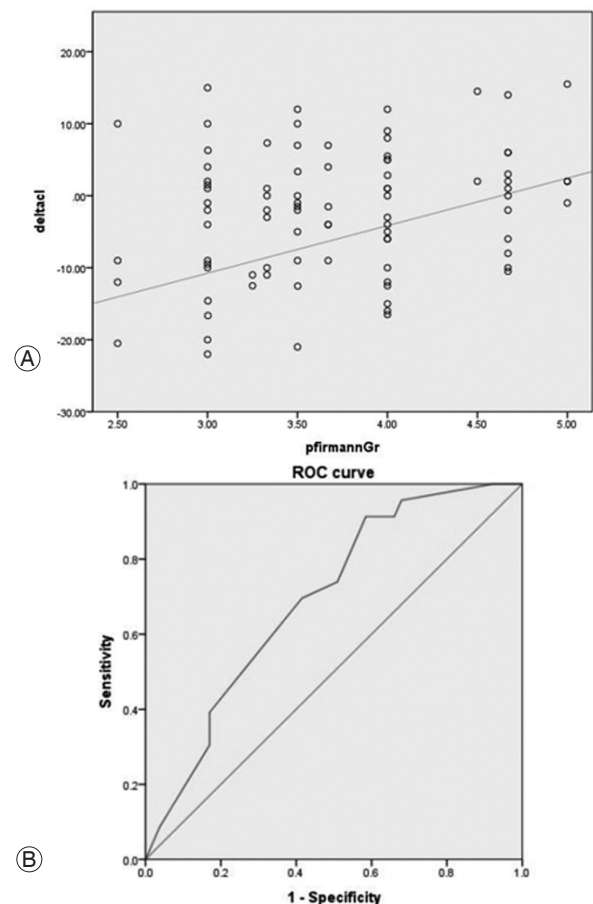


Fig. 2.

618

## Retrospective Comparative Study of Anterior Cervical Decompression and Fusion and Muscle-Preserving Selective Laminectomy in Patients with Degenerative Cervical Myelopathy

Kazuya Kitamura

*National Defense Medical College, Tokorozawa, Japan*

**Introduction:** Muscle-preserving selective laminectomy (MSL) is an alternative to conventional decompression surgery in patients with degenerative cervical myelopathy (DCM). It is less invasive, preserves the extensor musculature, and maintains the range of motion of the cervical spine. Therefore, the preferred treatment for DCM has changed from anterior decompression and fusion (ADF): anterior cervical discectomy and fusion (ACDF) and anterior cervical corpectomy and fusion (ACCF), towards MSL at our institution. Our aim was to compare surgical outcomes between ADF and MSL with patient-reported outcome measures (PROMs), complications, reoperations, and cost-effectiveness.

**Methods:** This study was a retrospective register-based cohort study. All patients with DCM who underwent ADF or MSL at Uppsala University Hospital from 2008 to 2019 were reviewed. Using analysis of covariance (ANCOVA), changes in PROMs from baseline to the 2-year follow-up were compared between the two groups, adjusting for clinicodemographic parameters, baseline PROMs, number of decompressed levels, and magnetic resonance imaging (MRI) measurements (C2–7 Cobb, C2–7 sagittal vertical axis [SVA], modified K-line interval). The PROMs, including the European Myelopathy Score (EMS), the Neck Disability Index (NDI), and the European Quality of Life-5 Dimension Questionnaire (EQ-5D), were collected from the national Swedish Spine Register. Length of hospital stay (LOS), complications, reoperations, and in-hospital treatment costs were also compared between the two groups.

**Results:** Ninety patients (mean age, 60.7 years; 51 men [57%]) were included in the ADF group, and 63 patients (mean age, 68.8 years; 41 men [65%]) in the MSL group. The ADF and MSL groups presented similar PROMs both at baseline (13.3 vs. 13.1 [EMS], 38.6 vs. 38.4 [NDI], 0.32 vs. 0.36 [EQ-5D], 47.3 vs. 45.6 [EQ-5D health]) and at the

2-year follow-up (14.1 vs. 13.3 [EMS], 33.8 vs. 31.3 [NDI], 0.43 vs. 0.42 [EQ-5D], 58.7 vs. 60.7 [EQ-5D health]). The preoperative MRIs presented similar C2–7 Cobb angles (10.7 [ADF] vs. 14.1 [MSL],  $p=0.12$ ) and modified K-line intervals (4.08 vs. 4.88,  $p=0.07$ ), but different C2–7 SVA values (16.2 vs. 19.3,  $p=0.04$ ). The ANCOVA-adjusted comparison of 2-year changes in PROMs presented no significant differences between the groups (EMS:  $p=0.618$ , NDI:  $p=0.904$ , EQ-5D:  $p=0.085$ , EQ-5D health:  $p=0.096$ ). LOS did not differ significantly (4.6 days vs. 4.1,  $p=0.31$ ). The overall complication rate was twice as high in the ADF group (22.2% vs. 9.5%,  $p=0.049$ ), while the reoperation rate was comparable (16.7% vs. 7.9%,  $p=0.146$ ). The average in-hospital treatment cost per patient was 6,870 US dollars (USD) for MSL, 7,737 USD for ACDF, and 14,953 USD for ACCF.

**Conclusions:** MSL provides similar PROMs after 2 years, a significantly lower complication rate, and better cost-effectiveness compared with ADF.

638

## Predictive Equations for Cervical Lordosis and T1 Slope of Young Adult Population without Any Neck Symptoms: Analysis of 171 Radiographs

Shankar Acharya

*Sir Gangaram Hospital, New Delhi, India*

**Introduction:** Normative values of cervical sagittal (CS) parameters including physiological cervical lordosis (CL) and their relationship with the thoracic inlet (TI) parameters have been scarcely documented in literature for healthy Indian adults.

**Purpose:** To analyze the CS and TI parameters in asymptomatic adults and form predictive equations for CL and T1 Slope (T1S).

**Methods:** We retrospectively analyzed cervical radiographs of 171 healthy adult volunteers and estimated the normative value of CS and TI parameters. Thoracic inlet angle (TIA), neck tilt (NT), and T1S were the TI parameters and cervical parameters included C2–C7 CL (Cobb's method), cervical sagittal vertical axis (cSVA), and C7 slope (C7S). T1S–CL was also calculated. Correlations were estimated and predictive equations were established using simple linear and stepwise multiple regression.

Paired sample *t*-test was used to see the statistical difference between the estimated and measured values.

**Results:** The mean age of participants was  $30 \pm 7.76$  years. Mean TIA, T1S, NT, CL, cSVA, C7S, and T1S-CL was  $79.6^\circ \pm 9.08^\circ$ ,  $29.5^\circ \pm 8.6^\circ$ ,  $49.3^\circ \pm 8.7^\circ$ ,  $21.4^\circ \pm 16.5^\circ$ ,  $18.8 \pm 12.4$  mm,  $25.7^\circ \pm 7.9^\circ$ , and  $8.7^\circ \pm 13.8^\circ$ , respectively. We established following predictive equations:  $CL = 0.66 \text{ T1S} + 0.57 \text{ TIA} - 0.68 \text{ SVA} - 30.9$  ( $r = 0.72$ ,  $R^2 = 0.53$ ,  $p < 0.01$ ),  $CL = 0.68 \text{ TIA} - 30.4$  ( $r = 0.41$ ,  $R^2 = 0.34$ ,  $p = 0.04$ ), and  $\text{T1S} = 4.45 + 0.72 \text{ C7S}$  ( $r = 0.77$ ,  $R^2 = 0.62$ ,  $p < 0.01$ ). There was no statistical difference between the predicted and the measured values of CL ( $t = 0.09$ ,  $p = 0.973$ ) or T1S ( $t = 0.14$ ,  $p = 0.84$ ).

**Conclusions:** This analysis of sagittal parameters in the asymptomatic adult population provides a valuable reference point for the management of various cervical alignment disorders.

873

## High Grade Spondylolisthesis: Reduction versus in Situ Fusion for Adult

Mohammad Mahbubur Rahman Khan

National Institute of Traumatology & Orthopaedic Rehabilitation (NITOR), Dhaka, Bangladesh

**Introduction:** There is no uniform agreement about the optimal treatment of high-grade spondylolisthesis. Surgery with reduction or *in situ* fusion is still controversial. The purpose of our study is to assess whether the evaluation of the spinopelvic balance can be effective in the surgical decision-making of high-grade spondylolisthesis.

**Methods:** A prospective study was designed for 18 patients with lumbar spondylolisthesis with severe neurological symptoms. Study time was from January 2017 to September 2022 in the National Institute of Traumatology & Orthopaedic Rehabilitation, a private hospital in Dhaka. Patients were selected for surgery depending on significant lower back pain with or without neurological deficit and no sufficient clinical improvement despite conservative care at least for 3 months.

**Results:** The evaluation was done by comparing their pre- and postoperative states including clinical evaluation, X-ray showing gradual fusion, computed tomography scan, and magnetic resonance imaging. Our choice of surgery was posterior lumbar interbody fusion and transforaminal

lumbar interbody fusion. Eight patients were treated with “*in situ*” fusion, and 10 with reduction and fusion. A clinical and radiological assessment of the deformity correction was carried out with a minimum follow-up of 2 years. The differences between the pre- and postoperative measures were statistically analyzed using a two-tailed, paired *t*-test. The patients treated with “*in situ*” fusion showed no statistically significant change at the last follow-up relative to pelvic tilt (PT), sacral slope (SS), and grade, while the patients treated with reduction showed significant changes. PT significantly decreased following surgery, while SS significantly increased, this is the indicator of a balanced pelvis.

**Conclusions:** The analysis of the spinopelvic sagittal balance is the specific determinant by which decision-making can be done. In case of the balanced deformities, no need for a reduction, but in unbalanced deformities correction is needed.

899

## A Comparison between Cortical Bone Trajectory Screws and Traditional Pedicle Screws in Patients with Single-Level Lumbar Degenerative Spondylolisthesis: 5-Year Results

Sungryul Choi

Severance Hospital, Seoul, South Korea

**Introduction:** Traditional pedicle (TP) screw insertion in posterior lumbar fusion has become a surgical treatment option for patients with degenerative lumbar diseases. Cortical bone trajectory (CBT) screw technology is a novel alternative strategy to obtain improved fixation, compared to fixation with the TP screw. We aimed to compare clinical and radiological outcomes, which include the Oswestry Disability Index (ODI) scores, Visual Analog Scale (VAS) scores, radiographic fusion, and postoperative complications such as the prevalence of adjacent segment disease, between CBT and TP screws in transforaminal lumbar interbody fusion (TLIF) for a minimum follow-up period of 5 years.

**Methods:** From January 2011 to December 2013, 80 consecutive patients with single-level low-grade degenerative spondylolisthesis underwent TP-TLIF. From January 2014 to December 2015, 131 consecutive patients with



single-level low-grade degenerative spondylolisthesis underwent CBT-TLIF. Patient-reported clinical outcome measures were obtained at baseline, and postoperatively at 6 months, 1 year, 2 years, and 5 years and adverse events after surgery were obtained. Radiologic outcomes such as radiologic adult spinal deformity (ASD), and radiographic fusion were also obtained. All analyses were conducted using SPSS Statistics.

**Results:** The postoperative VAS score for back pain was significantly lower in the CBT group through 5-year follow-up in the linear mixed model ( $p < 0.0001$ , respectively). The VAS score for leg pain was higher in the CBT group at 2 years postoperatively. The ODI scores were not significantly different between the preoperative and postoperative periods between the CBT and TP groups. Adverse events such as iatrogenic dural tear, screw malposition, and iatrogenic nerve root injury that occurred during the intraoperative period were not significantly different between the two groups. The prevalence of a second surgery for symptomatic ASD at postoperative 2 years was significantly different between the two groups ( $p = 0.044$ ).

**Conclusions:** Over a 5-year follow-up, the treatment effect of CBT screws in TLIF was comparable to that of TP screws in TLIF for patients with single-level lumbar degenerative spondylolisthesis. However, when performing CBT screws for TLIF, surgeons should consider screw malposition, breakage, and postoperative prevalence of symptomatic adjacent segment disease requiring surgery.

985

## Surgical Strategy-Oriented Classification for the Patients with Severe Dynamic Sagittal Imbalance

Sung Min Kim

*Department of Orthopaedic Surgery, Kyung Hee University Hospital at Gangdong, Seoul, South Korea*

**Introduction:** A concept, dynamic sagittal imbalance (DSI) was reported as a dynamic feature in patients with degenerative flatback for the first time. There have been several studies on the diagnosis of DSI or its features. However, there have been no studies on surgical strategies for optimal outcomes in patients with severe DSI.

**Purpose:** To analyze the characteristics of the patients with severe dynamic sagittal imbalance, develop a comprehen-

sive classification, and raise optimal surgical strategies for each condition.

**Methods:** Prospectively, 193 patients with a mean age of 65.2 years (range, 62–84 years) from 2017 to 2019 were tracked after surgical treatment for the severe dynamic sagittal imbalance that was defined as C7 sagittal vertical axis (C7SVA) becomes greater than 20 cm within 30 seconds after walking or standing in addition to rigid lumbar curve less than  $10^\circ$  in dynamic lateral radiographs and more than  $75.3^\circ$  of pelvic incidence (PI)–lumbar lordosis (LL) in previous our study. The characteristic is mainly based on radiographic findings. It is classified according to three criteria: the location of the apex, depending on combined compression fracture, and the stiffness of the apex segment. The receiver operating characteristic curves were plotted to evaluate the cut-off value of the compression rate (CR) of the vertebral body. The patients were categorized into one of three groups according to the surgical strategy (anterior column realignment [ACR], posterior spinal fixation [PSF], and pedicle subtraction osteotomy [PSO]) implemented: ACR+PSF, ACR+PSO+PSF, and PSO+PSF. Time-dependent radiographic analysis with spinopelvic sagittal parameters from each group was assessed and compared with each other using analysis of variance.

**Results:** Patients with severe dynamic sagittal imbalance can be mainly divided into two types according to the location of the apex: type I (thoracolumbar; T12, L1, or L2), type II (lumbar; L3, L4, or L5), and following modifiers were identified as potentially influencing the choice of surgical strategy: A: CR  $\leq 60\%$  in thoracolumbar or  $\leq 30\%$  in lumbar and B:  $>60\%$  in thoracolumbar or  $>30\%$  in lumbar based on the cut-off value of CR of the vertebral body (95% confidence interval,  $p < 0.001$ ) and rigid or fused of apex segment (- or +). Either type I or type II is further divided into four subtypes: type IA-, type IA+, type IB-, type IB+, type IIA-, type IIA+, type IIB-, and type IIB+. A surgical strategy was proposed to deal with each situation combining the different patterns and their modifiers by an expert's opinion consensus. At the final follow-up, C7SVA ( $p = 0.121$ ), LL ( $p = 0.665$ ), pelvic tilt ( $p = 0.096$ ), and PI–LL mismatch ( $p = 0.701$ ) were similar among the three groups according to surgical strategy.

**Conclusions:** This surgical strategy-oriented classification can be used effectively to decide preoperative surgical planning for patients with severe dynamic sagittal imbalance. Further research may be needed to validate the classification.

1011

## Do Intraoperative Neurophysiological Changes Predict Functional Outcomes Following Decompressive Surgery for Cervical Myeloradiculopathy? A Prospective Study

Keyur Akbari

*Apollo Hospital, Chennai, India*

**Introduction:** There is insufficient evidence on the therapeutic relationship between Intraoperative Neuromonitoring (IONM) changes during cervical spinal decompressive surgery for cervical compressive myelopathy (CCM) and neurological outcomes. Thus, in this current study, we prospectively assessed the effect of IONM changes in predicting postoperative neurological recovery in patients with CCM.

**Methods:** Twenty-eight patients who underwent cervical spine surgery with IONM for compressive myeloradiculopathy were enrolled. During surgery motor-evoked potential (MEP) and somatosensory-evoked potential (SSEP) at baseline, before, and after decompression was documented. A decrease in latency >10% or an increase in amplitude >50% was regarded as a “positive change”. Patients were subgrouped based on IONM changes into group A (those with positive changes) and group B (those with no change or deterioration). Nurick grade and modified Japanese Orthopaedic Association (mJOA) were evaluated before and after surgery. The Spearman correlation coefficient was used to ascertain the strength of the association.

**Results:** Nine patients (32.1%) showed improvement in MEP. The mean preoperative Nurick grade and mJOA score of groups A and B were (2.55±0.83 and 11.11±1.65) and (2.47±0.7 and 11.32±1.24), respectively. The mean postoperative Nurick grade of group A and B at 6 months was 1.55±0.74 and 1.63±0.46, respectively, and this difference was not significant. The mean postoperative mJOA score of groups A and B at 6 months was 14.3±1.32 and 12.9±1.29, respectively, and this difference was statistically significant ( $p=0.011$ ). Spearman correlation coefficient showed a significant positive correlation between the IONM change and the mJOA score at 6 months postoperatively ( $r=0.47$ ,  $p=0.01$ ).

**Conclusions:** The trend of improvement in Nurick grade

was observed in patients showing improvement in motor evoked potentials but did not reach statistical significance. Trend pertaining to improvement in mJOA was observed in patients showing improvement in motor evoked potentials was seen only at 6 months postoperatively whereas there was no significant difference at 3 months. We recommend serial monitoring of mJOA but also caution other investigators that the benefit of intraoperative monitoring might be observed only around 6 months postoperatively. Also, mJOA is a better indicator of improvement compared to Nurick grade.

1036

## Epidemiological Characteristics and Factors of Early Mortality for Traumatic Cervical Spinal Cord Injury with Radiographic Abnormality: A Multicenter Nationwide Cohort Study

Kyota Kitagawa

*Tertiary Emergency Medical Center, Tokyo Metropolitan Bokutoh Hospital, Tokyo, Japan*

**Introduction:** Traumatic cervical spinal cord injury (TCSI) is a relatively common injury in Japan, with the frequency of occurrence increasing each year. However, few reports have focused on cervical spine injuries with fracture or dislocation. The objectives of our study were to investigate the clinical features of TCSI with radiographic abnormality.

**Methods:** A cohort study was designed using the Japan Trauma Data Bank from January 2004 to December 2019. Of 14,611 patients with TCSI, 5,367 patients with cervical spine fracture and dislocation were extracted and divided into the survival and mortal groups. Patient background, cause of injury, severity of paralysis, neurological level of injury, and comorbidity were compared. The primary endpoint was acute mortality. Using logistic regression analysis, multivariate analysis was performed.

**Results:** The survival group consisted of 4,487 patients, and the mortality group consisted of 880 patients. The mean age was 62.0±18.3 years old in the survival group and 62.6±22.6 years old in the mortality group. Elderly patients over 70 years old were 1,775 (39.6%) in survivals and 438 (49.9%) in mortalities. Fall at ground level was the most common cause of injury in survivors (44.1%) against mortalities (25.8%). Contrarily, high-energy trau-

mas such as traffic accidents were the leading cause of mortalities (47.3%) against survivors (29.8%). The mortalities group showed more frequencies of bradycardia (47.8% in the mortality group, 5.5% in the survival group), hypotension (60.9% in the mortality group, 8.4% in the survival group), and severe disturbance of consciousness (77.9% in the mortality group, 9.6% in the survival group) at presentation than the survival group. The Injury Severity Score, which correlates with severity and mortality, was also higher in the mortality group ( $55.9 \pm 23.8$ ) than in the survival group ( $23.9 \pm 14.0$ ). The mortality group had more cervical spine dislocation (59.7% in the mortality group, 38.2% in the survival group) and complete paraplegia above C3 (56.6% in the mortality group, 4.7% in the survival group) than the survival group. The mortality group was more frequently associated with concomitant injuries at all sites than the survival group, especially with head injuries (50.9% in the mortality group, 25.9% in the survival group) and thoracic injuries (42.7% in the mortality group, 18.0% in the survival group). Multivariate analysis of mortality revealed that ages over 70 years (odds ratio [OR], 1.79; 95% confidential interval [CI], 1.25–2.58), bradycardia at presentation (OR, 3.12; 95% CI, 1.98–4.91), hypotension at presentation (OR, 2.75; 95% CI, 1.84–4.11), severe disorder of consciousness at presentation (OR, 7.16; 95% CI, 4.69–10.9), cervical spine dislocation (OR, 1.56; 95% CI, 1.08–2.27), complete paraplegia above C3 (OR, 2.86; 95% CI, 1.90–4.29), and head injuries (OR, 1.48; 95% CI, 1.01–2.15) were independent risk factors of mortality.

## 1060

### A Risk Quantification Reference Table for Progressed Adolescent Idiopathic Scoliosis Surgery: An Exact Case Matched Outcomes Analysis

Jun-Hao Tan

National University Hospital, Singapore

**Introduction:** Surgical treatment delay in adolescent idiopathic scoliosis (AIS) due to family preferences is common. Multiple studies have demonstrated that patients with curve progression will result in more complex surgeries and increased complications. However, these stud-

ies were unable to quantify the exact amount of increase in risks and outcomes correlated to the curve progression and subsequent increased surgical complexity.

**Purpose:** This study aims to quantify the increase in risks as the Cobb angle increases and provide a Quantifiable Risk Reference Table that can be utilized for counseling.

**Methods:** This was a retrospective exact matched case-control study, conducted at a single university hospital. AIS patients were divided into three groups: group A: Cobb angle  $50^\circ$ – $60^\circ$ , group B:  $61^\circ$ – $70^\circ$ , and group C<sub>Final</sub>  $\geq 80^\circ$ . Each patient in group C<sub>Final</sub> who had curve progression was then traced back in time to review the clinical data at earlier presentations at  $50^\circ$ – $60^\circ$  (C<sub>1</sub>) and  $61^\circ$ – $70^\circ$  (C<sub>2</sub>). Patient demographics and radiological, operative, and outcomes data were compared between group A vs. group C<sub>1</sub> and group B vs. group C<sub>2</sub>.

**Results:** A total of 614 AIS surgeries were reviewed. Utilizing the EM technique, a total of 302 AIS patients were recruited. There were 147, 111, 31, and 32 patients matched in groups A, B, C<sub>1</sub>, and C<sub>2</sub>, respectively. C<sub>2</sub>\_Final patients had 34% curve pattern change, 23.2% higher incidence of requiring two surgeries, and 17.3% increase in complications. There was a statistically significant increase of 2.4 spinal levels fused, 12% increase in implant density, 35% increase in operative time, 97% increase in intraoperative blood loss, 10% loss of scoliosis correction, 40% longer hospitalization stay, and 36% increase in costs for patients who had curve progression.

**Conclusions:** This study is the first to use a homogeneously matched AIS cohort to provide a Quantifiable Risk Reference Table. The Risk Table provides essential knowledge for treating physicians when counseling AIS patients.

## 1069

### Efficacy, Safety, and Reliability of Single Posterior Approach for Unstable Thoracolumbar Burst Fracture Treated with Anterior Reconstruction and Posterior Instrumentation

Sharif Ahmed Jonayed

National Institute of Traumatology & Orthopaedic Rehabilitation, Dhaka, Bangladesh

**Introduction:** Management of unstable thoracolumbar burst fractures is still a controversial issue. Fracture mor-

phology, neurologic status, and surgeon preference play major roles in deciding the appropriate approach. Though the combined anterior and posterior instrumentation provides the most stable repair, but optimizing neural decompression and stable internal fixation using a single approach over the least number of spinal segments is the goal. Moreover, the use of both approaches on a trauma patient may increase morbidity. Anterior reconstruction of spine through only one approach can provide an effective outcome.

**Purpose:** The purpose of this study is to evaluate the neurological, functional, and radiological outcome of the anterior reconstruction of the spine by a single posterior approach in cases of unstable thoracolumbar burst fractures.

**Methods:** Eight patients with acute unstable thoracolumbar burst fractures (T-11 to L-4) with neurological deficit in the age group of 16–60 years with McCormack's score 6 or more and thoracolumbar injury severity score (TLISS) 5 or more were included. Neurological status, Visual Analog Scale (VAS), angle of kyphotic deformity, McCormack's score, and TLISS score were evaluated.

**Results:** The mean duration of surgery was 255 minutes. The mean blood loss was 440 mL. The mean improvement of the American Spinal Cord Injury Association scale was 1.67 in a patient with incomplete spinal injury whereas the patient with complete spinal injury remains the same at the last 6 months' follow-up. The mean preoperative kyphotic angle was improved from 25° to 5° postoperatively. VAS score improved from 6.1 to 1.7.

**Conclusions:** The single posterior approach is a safe, cost-effective, and reliable surgical approach for the reconstruction of all the columns of the spine. It reduces the operative time, blood loss, the morbidity associated with a combined approach with a good outcome.

acuity deficits. We aimed to investigate the correlations among age, pain severity, disability, and tactile acuity in patients with chronic low back pain by using multiple tactile acuity tests.

**Methods:** A total of 58 participants (36.40±14.95 years) with chronic low back pain were recruited, and tactile acuity tests (i.e., 2-point discrimination, point-to-point test, and 2-point estimation) were performed on their painful low back areas. A Numerical Rating Scale that ranged from 0 ("no pain") to 10 ("the worst pain") was used as the scoring standard to quantify pain intensity of low back pain, including general pain, maximum pain, and pain unpleasantness during the past 3 months. Disability was measured by using the Oswestry Disability Index (ODI) and the Roland-Morris Disability Questionnaire (RMDQ). The correlations between age, pain intensity, disability, and tactile acuity were characterized by Pearson's correlation coefficients. Subgroup analyses according to the median values of age, pain intensity, and disability were used to compare the intergroup difference in tactile acuity.

**Results:** Results illustrated significant negative associations among age, pain intensity, disability, and tactile acuity ( $R^2=0.314$  to  $0.617$ ,  $p<0.05$ ). Subgroup analyses revealed that patients with below-the-median values of age ( $p<0.001$ ), maximum pain ( $p\leq 0.013$ ), general pain ( $p\leq 0.004$ ), pain unpleasantness ( $p\leq 0.006$ ), ODI ( $p<0.001$ ), and RMDQ ( $p\leq 0.001$ ) had better performance in tactile acuity tests than those with above-the-median values.

**Conclusions:** Our findings confirmed negative associations among age, pain severity, disability, and tactile acuity in patients with CLBP. Severe CLBP was associated with worsening tactile acuity. Specifically, CLBP patients with advanced age, severe pain, and severe dysfunction may experience a significant deterioration in tactile acuity.

1086

## Correlations between Age, Pain Intensity, Disability, and Tactile Acuity in Patients with Chronic Low Back Pain

Kangyong Zheng

The Hong Kong Polytechnic University, Hong Kong, China

**Introduction:** Chronic low back pain is an overwhelming problem for a wide range of people and leads to tactile

1117

## Does Platelet-Rich Plasma Enhance Fusion in Transforaminal Lumbar Interbody Fusion? A Prospective Clinico-Radiological Comparative Study

Ganesan Sudhir

*Sri Ramachandra Institute of Higher Education and Research, Chennai, India*

**Introduction:** Several animal studies have shown that platelet-rich plasma (PRP) is effective in enhancing bone fusion. But the role and efficacy of PRP in spinal fusion surgery remain uncertain. The objective was to evaluate the efficacy of PRP in bone fusion and to compare the clinical and radiological outcomes of transforaminal lumbar interbody fusion (TLIF) with and without PRP.

**Methods:** This is a prospective study done on 50 patients who underwent TLIF surgery for various spinal pathologies. Patients were divided into the control group (underwent TLIF with interbody cage and local bone grafts alone) and the study group (underwent TLIF with interbody cage, local bone grafts, and PRP). Functional outcome was evaluated using Visual Analog Scale (VAS) and Oswestry Disability Index (ODI). The radiological outcome was assessed by Bridwell's grading system for fusion on computed tomography scan at the end of 2 years.

**Results:** The average bone fusion rate was significantly higher in the PRP group compared to the control group; however, the average duration of fusion was not statistically significant. There was no difference in VAS and ODI at 1–2 years. There was also no significant difference in lower back pain, leg pain, and numbness in both groups at the end of 1 year.

**Conclusions:** Although there is no statistically significant difference in functional outcome between both groups, local application of PRP along with autologous bone grafts increases bone fusion rates with good clinical and radiological outcomes.

1126

## Can We Predict the Outcome after Direct Repair for Lumbar Pars Defect

Ujjwal Kanti Debnath

*Jagannath Gupta Institute of Medical Sciences, Kolkata, India*

**Introduction:** Only few sporting individuals with symptomatic lumbar pars injuries require surgical repair and it is often difficult to predict the outcome following surgery.

**Purpose:** Predictive factors for a good outcome following direct repair for lumbar pars defect were analyzed for a predictive model.

**Methods:** A total of 52 consecutive young sporting individuals with a mean age of 19 years (range, 8–35 years) were treated with direct repair for lumbar pars defect confirmed on imaging studies (i.e., single-photon emission computed tomography, computed tomography, and magnetic resonance imaging scans). And 50 patients completed the Visual Analog Scale (VAS), Oswestry Disability Index (ODI), and 36-item Short Form Health Survey (SF-36) questionnaires as a part of their assessment. Preoperative background variables were used in a multiple regression model to find the strongest predictor of postoperative outcome as measured by ODI.

**Results:** Buck's screw repair of the pars defect was carried out in 44 patients (33 males and 11 females). Unilateral in eight patients (seven males and one female) and bilateral in 36 patients (26 males and 10 females). Although age at surgery showed linear co-linearity ( $\rho=0.32$ ,  $p<0.05$ ), it was not significant in the model. The most consistent association with the preoperative VAS score was the pre- and postoperative ODI scores, i.e.,  $\rho=0.51$  ( $p<0.01$ ) and  $\rho=0.33$  ( $p<0.05$ ), respectively. In the bilateral group, with Buck's repair at a single level, i.e., 33/36 patients (93%) had returned to sports at a mean time of 7.5 months (range, 6–12 months). Overall, 44/52 individuals (84%) had returned to their sports with a post-treatment ODI score of  $<10$ . The stepwise regression modeling suggested six independent factors (preoperative ODI, preoperative SF-36 physical component summary [PCS], Buck's repair, multiple operations, professionalism, and pars defect at L3), as the determinants of the outcome (i.e., postoperative ODI) in 80.9% patients ( $R^2=0.809$ ).

**Conclusions:** The outcome after direct repair of pars defects below 25 years of age runs a predictable course. Pro-

fessionalism in sports has a high impact on the outcomes. Preoperative ODI and SF-36 PCS scores are significant predictors of good functional outcome. The regression equation can predict the outcome in 80.9% of sporting individuals undergoing Buck's repair.

1187

## Central Sensitization Is a Significant Risk Factor for the Chronic Low Back Pain

Hiroshi Hashizume

Wakayama Medical University, Wakayama, Japan

**Introduction:** Central sensitization is defined as an increased responsiveness of nociceptors in the central nervous system to either normal or sub-threshold afferent input. To clarify the relationship between central sensitization and chronic low back pain (CLBP), we conducted a longitudinal survey under the spread of coronavirus disease 2019 (COVID-19) infection in Japan.

**Methods:** Invitations were sent to 771 people who participated in the baseline survey in July 2019 before the spread of the COVID-19 infection in rural areas in Wakayama prefecture, and 227 people (79 men, 148 women; average age at baseline, 68.5±9.5 years) who participated in the follow-up survey in October 2020 were included in the analysis. The main evaluation items were (1) presence or absence of CLBP (definition: low back pain that lasts for 3 months or more) and (2) central sensitization screening tool: Central Sensitization Inventory (CSI). At the time of follow-up survey, we also asked about whether or not to refrain from going out due to the spread of COVID-19 infection. Statistics: First, we observed changes in the prevalence of CLBP and CSI scores through the observation period. Second, the participants were divided into the following four groups and the baseline characteristics were compared among the groups. (1) "None group" did not have CLBP through the observation period. (2) "De novo group" did not have CLBP at baseline while it had CLBP at follow-up. (3) "Continued group" had CLBP through the observation period. (4) "Improved group" had CLBP at the baseline while it did not have CLBP at the follow-up. Third, a multiple logistic regression analysis was conducted to elucidate risk factors for the development of CLBP on 167 patients who did not have CLBP at baseline.

**Results:** The prevalence of CLBP were 59/227 (26%) at baseline and 71/227 (32%) at follow-up. The CSI score was 16.9 at baseline and 17.1 at follow-up. There were 131 participants (60%) in the "none" group, 32 (15%) in the "de novo" group, 39 (18%) in the "continued" group, and 15 (7%) in the "improved" group. There were no significant differences in gender, age, body mass index at baseline, and whether or not to refrain from going out among the four groups. The baseline CSI score (mean) was 14.2 in the "none" group, 17.9 points in the "de novo" group, 22 points in the "continued" group, and 20 points in the "improved" group. A significant difference was observed between the "none" group and the "continued" group. The multiple logistic regression analysis revealed that higher baseline CSI scores were a significant risk factor for the development of CLBP.

**Conclusions:** (1) After the spread of COVID-19 infection, the prevalence of CLBP increased. (2) Higher CSI score was a significant risk factor for the development of CLBP.

1201

## Multicenter Validation of Using the Distal Radius and Ulna Classification to Predict Scoliosis Progression: APSS Scoliosis Focus Group Study

Hideyuki Arima

Hamamatsu University School of Medicine, Hamamatsu, Japan

**Introduction:** The peak height velocity (PHV) is a useful index to predict scoliosis progression in adolescent idiopathic scoliosis (AIS), but the timing of PHV varies from patient to patient. Risser staging has been often used to predict, but there are reports that it is insufficient for PHV prediction. Bone maturity assessment using hand and wrist X-rays such as the Distal Radius and Ulna (DRU) classification is growing in popularity and is used clinically in various countries. However, its cross-ethnicity and cross-cultural validity have never been evaluated.

**Purpose:** The purpose of this study is to investigate the predictability of PHV and peak curve progression in patients with AIS from a multicenter study in the Asia Pacific countries.

**Methods:** AIS patients aged 10 to 18 years who were enrolled in a multicenter study at several Asian scoliosis re-

ferral centers and were subsequently available for follow-up for at least 6 months were prospectively reviewed. Baseline DRU grade and Cobb angle of the major scoliosis curve and changes in body height and Cobb angle of major scoliosis curve over the following 6 months were investigated. The relationship between baseline DRU classification and changes in body height and Cobb angle of major scoliosis curve within 6 months was examined.

**Results:** The study collected data from 81 AIS patients (13 males and 68 females) from Asian countries (57 Japanese, 18 Malaysians, and six Taiwanese) with a mean age of  $13.4 \pm 1.8$  years. Baseline body height was  $154.8 \pm 8.4$  cm and Cobb angle of major scoliosis curve was  $24.2^\circ \pm 8.9^\circ$ , whereas 6 months later they were  $156.4 \pm 7.8$  cm and  $23.7^\circ \pm 9.6^\circ$ , respectively. The Jonckheere-Terpstra trend test indicated that, with an increasing Radius grade (R5, 6, 7, 8, 9, 10, 11), change in body height ( $5.5 \pm 0.9$ ,  $3.8 \pm 2.4$ ,  $2.2 \pm 1.4$ ,  $1.5 \pm 1.2$ ,  $0.6 \pm 0.7$ ,  $0.8 \pm 1.3$ ,  $-0.5$ ;  $p < 0.001$ ), and Cobb angle ( $-1.0 \pm 12.7$ ,  $3.5 \pm 2.3$ ,  $1.6 \pm 4.0$ ,  $-1.3 \pm 5.6$ ,  $-2.1 \pm 4.2$ ,  $0.2 \pm 2.7$ ,  $-4.3$ ;  $p = 0.019$ ) showed an increasing trend. Whereas for Ulna grade (U4, U5R5, 6, 7, 8, 9), there was a trend for change in body height ( $5.1 \pm 1.5$ ,  $2.9 \pm 1.9$ ,  $1.4 \pm 1.4$ ,  $1.2 \pm 1.2$ ,  $0.7 \pm 1.2$ ,  $0.7 \pm 1.0$ ;  $p < 0.001$ ), but no statistically significant trend was found in the change of Cobb angle ( $1.3 \pm 6.2$ ,  $3.1 \pm 7.8$ ,  $1.7 \pm 4.1$ ,  $-0.9 \pm 4.2$ ,  $0.5 \pm 4.5$ ,  $0.5 \pm 0.7$ ;  $p = 0.197$ ).

**Conclusions:** The results of an Asian multicenter collaborative study validated the Radius grade of DRU classification as a practical bone maturity assessment with statistically significant trends in height and scoliosis curve changes. The DRU classification has the potential to detect patients with progressive scoliosis at an early stage. Especially in patients with R6 or less, scoliosis may progress in a short period of time, and more frequent and longer follow-up is necessary.

1203

## A Comparative Factor Analysis and New Magnetic Resonance Imaging Scoring System for Differentiating Pyogenic versus Tuberculous Spondylodiscitis

Patchara Pornsopanakorn

Maharat Nakhon Ratchasima Hospital, Nakhon, Thailand

**Introduction:** The differential diagnosis between pyogenic

spondylodiscitis (PyS) and tuberculous spondylodiscitis (TS) is crucial. Accurate diagnosis and early treatment are important to prevent further progression of disease and decrease patient morbidity.

**Purpose:** This study aims to compare and analyze the difference in clinical and magnetic resonance imaging (MRI) findings between PyS and TS and to develop and validate a simplified multi-parameter MRI-based scoring system for differentiating TS from PyS.

**Methods:** We compared the predisposing factors of 190 patients (67 PyS patients and 123 TS patients) whose confirmed diagnosis by laboratory, culture, or pathology. The demographics, clinical characteristics, laboratory results, and MRI findings of the patients were collected between 2015 and 2020. The data were analyzed using logistic regression methods. The selected logistic coefficients were transformed into an MRI-based scoring system. Internal validation was done with the bootstrapping procedure.

**Results:** The multivariate analysis of the relevant factors for TS vs. PyS group demonstrated that facet joint arthritis (odds ratio [OR], 0.19; 95% confidence interval [CI], 0.02–1.28), intraosseous abscess (OR, 18.20; 95% CI, 2.24–147.26), well-defined paravertebral soft tissue extension (OR, 12.67; 95% CI, 1.77–90.55), all spreading (OR, 72.47; 95% CI, 6.88–763.93), epidural phlegmon (OR, 0.0037; 95% CI, 0.003–0.042), and thoracic lesion (OR, 116.87; 95% CI, 4.33–3155.81) significantly influenced the differential diagnosis between TS vs. PyS group and were used for derivation of the scoring system. The score-based model showed an area under the receiver operating characteristic curve of 0.91 (95% CI, 40.38–513.42). The developed scoring system ranged from 0 to 24 and was cutoff at greater than or equal to 10 for TS (OR, 144; 95% CI, 40.38–513.42).

**Conclusions:** This simplified MRI-based scoring system for differentiating TS from PyS was helpful to guide the appropriate treatment when the causative organism is not identified.

1212

## Non-surgical Management of Flexion Distraction Type of Spinal Column Injuries, Institutional Preview

Shamim Ahmad Bhat

*Hospital for Bone and Joint Surgery, Government Medical College Srinagar, Srinagar, India*

Thoracolumbar fractures with flexion distraction mechanism of injury, involving all the three columns of the spinal vertebrae, are common presentations in “fall from height” and “road traffic injuries.” These fracture patterns with intact neurology present a surgical dilemma of whether to manage conservatively or surgically. When a “fractured” vertebra having “normal neurology,” with posterior element bony injury, is held in a biomechanically acceptable position and alignment, it unites readily without the need for surgical stabilization of the fractured bones for the bony union. Our study comprised 74 patients treated conservatively and reported for final follow-up for clinical and radiographic assessment. Patients enrolled were treated between 2014 to 2016, and the final follow-up of a minimum of 1 year (range, 1–3 years). There were 56 males and 18 females, and 90% of cases were “fall from height” (mostly from fruit trees). Nonoperative support of the spine was continued for 12 weeks (pop jacket in 45, brace in 29), followed by physiotherapy and rehabilitation. The mean kyphosis at the fractured level at presentation was 35° (range, 15°–60°), it was reduced by the initiation of the conservative treatment by about 25° and finally, at 1 year of follow-up, the mean correction of kyphosis was about 30°. The restoration of the anterior vertebral height was about 75% of the normal adjacent vertebrae at the initiation of the conservative treatment and it improved subsequently to 80% at the end of 1 year. Visual Analog Scale score at final follow-up was 2. No deterioration of neuro or loss of vertebral kyphosis and height was noted in any case. No residual instability at end of 1 year was demonstrated in stress views of the X-ray at the fracture site. Conservative treatment in selected cases of three-column bony chance fractures without neurological deficit can be managed successfully with conservative treatment and achieving and maintaining normal bony configuration and stability by virtues of bony healing without instrumentation. The bony chance fractures can

be managed when maintained in biomechanically desirable and acceptable alignment and immobilization of the spine in well-contoured orthosis or pop.

1223

## The Alternation of Junctional Levels after Decompression and Alignment Correction for Cervical Kyphotic Deformity-Induced Multilevel Cervical Myelopathy: A Retrospective Case Analysis

Hao-Wen Chen

*Orthopaedic Department, Hualien Tzu Chi Hospital, Hualien, Taiwan*

**Introduction:** Multilevel cervical myelopathy (MCM) caused by cervical kyphotic deformity (CKD) had made an indication for cord decompression and alignment correction with long instrumented structures. However, the subsequential change over the junctional level after the correction and fusion remains an unidentified issue. Therefore, the aim of this study is to evaluate the junctional alignment change as well as the functional outcome after long instrumented correction and decompression for the CKD-induced MCM.

**Methods:** From 2016 to 2019, 50 cases of CKD-induced MCM were enrolled for decompression and correction. The sagittal alignment changes of junctional levels, including occipital-cervical angle (C0–2 Cobb angle [CA]), C2–7 CA, C2–7 sagittal vertical axis, and T1 slope (T1S). While functional outcomes (modified Japanese Orthopaedic Association score, Visual Analog Scale, Neck Disability Index) were also evaluated preoperatively, at 3 months, 6 months, 24 months, and 36 months postoperatively.

**Results:** The lordotic change and the improvements in functional outcomes were both considerable almost in every patient within 6 months postoperatively. However, the compensatory mechanism presented secondary to the chronic kyphotic deformity was found reversed as follow-up and turned significant since 12 months postoperatively. Besides, the reversed change in sagittal alignment was positively related to the age, and the scale of lordotic corrected during the initial surgery. However, these changes were not significantly correlated to the functional outcomes at any time point of the follow-up.

**Conclusions:** As horizontal gaze is the functional require-



ment of the patient's daily life, a decrease of T1S and hyperextension of occipital-cervical junction occurred as compensation for the chronic cervical lordosis loss. If T1S decrease alone cannot achieve cervical sagittal balance, hyper-lordotic change in O–C2 segment may occur as secondary compensation. After alignment correction with instrumented fusion, patients tended to regain normalization of T1S, and the proportion of normalized T1S was related to the correction scale. Reversed compensatory change after alignment correction occurred over junctional levels. The normalization of certain radiographic parameters, representing spinal balance could gradually achieve after the alignment correction. If neural and soft tissue allowed, the larger instrumented correction as needed would prefer to achieve more normalized cervical alignment without the worry of deterioration of clinical outcome within a 3-year follow-up.

1279

## Comparison of Surgical Outcomes Between three-Column Osteotomy and Anterior-Posterior Fusion for Osteoporotic Vertebral Fracture

Shinji Takahashi

*Osaka Metropolitan University, Osaka, Japan*

**Introduction:** Corrective surgery for osteoporotic vertebral fractures (OVF) is often difficult. While the elderly patient requires the least invasive technique possible, osteotomy (3CO) may also be necessary to achieve the desired correction angle. The purpose of this study was to compare the surgical outcomes of anterior-posterior fixation using X-core and 3CO.

**Methods:** We compared cases in which anterior-posterior fixation or 3CO was performed at our institution for OVF vertebral deformity. Since most of the cases in the lower lumbar region are fixed anterior-posterior, cases in the thoracolumbar transition region were selected. Anterior-posterior fixation was performed for those with mobility in the supine position, including the intervertebral discs above and below the fractured vertebra in dynamic imaging, and 3CO was performed for those with poor mobility. Anterior-posterior fixation was performed in 24 cases and 3CO in 26 cases.

**Results:** The mean age was  $75.7 \pm 6.6$  years in the anterior-posterior fixation group and  $73.2 \pm 7.8$  years in the 3CO group. Mean follow-up was 27.9 months and 43.3 months, respectively. The mean operative time was 272 minutes and 355 minutes, and the mean blood loss was 319 mL and 810 mL, both with statistically significant differences (t-test,  $p < 0.05$  for both). There were no differences between the two groups with respect to the pain Visual Analog Scale or Japanese Orthopaedic Association scores. There was a statistically significant difference in local kyphosis between the anterior-posterior and 3CO groups,  $32.1^\circ$  and  $50.3^\circ$  preoperatively, but  $20.6^\circ$  and  $23.7^\circ$  at the last observation, with no difference between the two groups. Reoperation was more common in the anterior-posterior fixation group (17% in four cases and 8% in the 3CO group), although there was no significant difference. Correction loss was particularly high in the anterior-posterior group, especially in cases in which the local angle was corrected more than  $6^\circ$  from that in the supine position at the time of dynamic imaging.

**Conclusions:** When vertebroplasty cannot be performed for OVF, anterior-posterior fixation including corpectomy or 3CO is necessary. Anterior-posterior fixation using an X-core was less invasive when local mobility was allowed, but if the target angle cannot be achieved in the supine position, 3CO should be considered because forcing the vertebrae to lift up from the anterior position may cause corrective loss.

1284

## Predictors of Neurological Outcome of Acute Traumatic Central Cord Syndrome: Outcome of a Treatment Algorithm

Verma Vishal

*All India Institute of Medical Sciences Rishikesh, Rishikesh, India*

**Introduction:** Central cord syndrome is caused by an acute cervical spinal cord injury, resulting in disproportionate limb weakness, sensory loss below the lesion, and bladder dysfunctions. This paper aims to compare the functional and surgical outcomes in the patients managed surgically by anterior or posterior approach and to predict the independent prognostic factors for final neurological outcomes.

**Purpose:** Retrospective analysis of prospectively collected

data to investigate the outcome of acute traumatic central cord syndrome following the new treatment algorithm.

**Methods:** This study was a retrospective review of patients with central cord syndrome presented between January 2019 and January 2020. Preoperative radiographic assessment of the patients using plain radiographs, computed tomography, and magnetic resonance imaging divided them into two groups. Group 1 included an anterior procedure in which the patient had anterior compression, segmental kyphosis greater than 10°, posterior longitudinal ligament disruption, and three-column injury managed with anterior cervical discectomy and fusion/anterior cervical corpectomy and fusion, and group 2 included in which patients having maintained cervical lordosis, segmental kyphosis lesser than 10°, multi-segmental posterior compression, managed with posterior approach and laminectomy and fusion performed when there is up to 2 level compression, and laminoplasty performed when there is greater than 2 level compression.

**Results:** Among 24 patients, 18 were males and six were females. The mean age group was 44.79 years. A univariate analysis was carried out to look for the factors which are predictive of neurological improvement at the final follow-up. Factors taken into account for carrying out the univariate analysis were age, adolescent idiopathic scoliosis (AIS) scores, maximal canal compromise, maximal spinal cord compression, the extent of parenchymal damage, early (<24 hours) surgery, and late (>24 hours) (Table 1). Following it, a multivariate regression analysis was carried out in order to predict the factors which significantly associated with a final neurological recovery. Statistical significance was presumed for a  $p$ -value of <0.05 (Table 2). On univariate analysis, there is a significant association between low AIS scores ( $p=0.02$ ), maximal canal compromise ( $p=0.04$ ), maximal spinal cord compression ( $p=0.02$ ), and extent of cord parenchymal damage ( $p=0.02$ ) with poor neurological outcomes. On multivariate analysis, maximal spinal canal compromise, the extent of parenchymal damage, and admission AIS scores are independent risk factors for poor neurological outcomes. In the anterior surgery group, there was a statistically significant increase in the modified Japanese Orthopaedic Association (mJOA) hand component scores at 6 months ( $p=0.02$ ), which again became insignificant at the final follow-up similarly, Neck Disability Index (NDI) scores were higher in the posterior surgery group than the anterior surgery group at 6 months and at the final follow-

up ( $p=0.01$ ). As compared to the anterior surgery group, the posterior surgery group had a longer surgery duration and more blood loss.

**Conclusions:** The approach does not affect functional outcomes at the final follow-up, except for the initial improvements in mJOA hand component scores and NDI. Also, the posterior approach is associated with increased surgical time and blood loss compared to anterior as well as greater neck disability scores.

**Table 1.** Univariate analysis

Variable	$p$ -value
Age	0.07
Maximal spinal cord compression	0.02
Maximal canal compromise	0.04
Extent of parenchymal damage	0.02
Admission AIS scores	0.02
Segmental kyphosis	1.00

AIS, adolescent idiopathic scoliosis.

**Table 2.** Multivariate analysis

Variable	Relative risk	$p$ -value
Admission AIS scores	0.59	0.03
Maximum canal compromise	1.56	0.01
Extent of parenchymal damage	1.68	0.01

AIS, adolescent idiopathic scoliosis.

## 1287

### Comparison of Three Different Instrumentation Constructs in a Prospective Cohort of Thoracolumbar Burst Fractures: Does Interbody Fusion Offers Any Advantage over Fractured Level Instrumentation

Bhaskar Sarkar

All India Institute of Medical Sciences Rishikesh, Rishikesh, India

**Introduction:** Ideal construct design for posterior instrumented fusion in thoracolumbar burst fractures remains much debated worldwide. Current study presents comparative outcome of three different posterior constructs in such injuries.

**Methods:** Patients between 18 to 60 years of age and operated for single-level thoracolumbar burst fracture (T10–

L2) with neurologic deficit were included in the study prospectively between July 2020 to April 2022. The decision on surgical treatment was based on a Thoracolumbar Injury Classification and Severity Scale score of 5 or more. Patients with intact pedicles at fractured levels were treated with short-segment with index screws (group I). The remaining patients were treated with either short-segment fixation with an interbody cage (TLIF) (group II) or long-segment fixation (group III) depending upon a semi-randomized model. Patients were followed for a minimum of 6 months. The outcome was measured in terms of improvement in pain (Visual Analog Scale [VAS] score), level of activity (Oswestry Disability Index [ODI] score), neurological improvement (American Spinal Cord Injury Association [ASIA] scores), fusion status (Bridewell computed tomography scoring), perioperative complications, and radiological outcomes. The three treatment groups were compared and statistical analysis was done. The significance level for  $p$ -values was set at  $<0.05$ .

**Results:** A total of 60 patients were included with 20 patients in each group and a mean age of 39 years. At presentation, the number of patients with ASIA grades A, B, C, and D were 31, 6, 14, and 9, respectively. All patients had significant improvement in VAS and ODI scores at the final follow-up. No patient showed deterioration in neurology after surgery. At the end of 6 months, neurological status was 13 in ASIA A, 4 in ASIA B, 22 in ASIA C, 6 in ASIA D, and 15 in ASIA E. Four patients had traumatic dural tears and were treated with direct repair with augmentation. Two patients in group 3 required operative debridement for deep surgical site infection. Statistical analysis did not reveal any significant difference between the three groups in terms of ASIA grade improvement, canal clearance, length of hospital stay, VAS or ODI scores, fusion scores, and loss of kyphotic correction on follow-up. However, estimated blood loss and surgery time were found to be statistically significant when compared between group I ( $395\pm 36$  mL and  $144\pm 27$  minutes) and group III ( $744\pm 114$  mL and  $203\pm 23$  minutes) ( $p<0.05$ ), as well as between group II ( $422\pm 54$  mL and  $157\pm 17$  minutes) and group III ( $p<0.05$ ), although no significant difference was found between groups I and II ( $p=0.151$ ).

**Conclusions:** Short-segment posterior fixation with instrumentation of fractured vertebra was found to be better than interbody fusion or long-segment fixation in terms of estimated blood loss and duration of surgery. Though all three constructs performed similarly with regard to

neurological improvement or fusion status.

## 1293

### The Surgical Results of Onstage of Laminoplasty and Anterior Cervical Fusion for the Patients with Multilevel Cervical Spondylotic Myelopathy: Postoperative 8-Year Follow-up

Wen-Tien Wu

*Department of Orthopaedics, Hualien Tzu Chi Hospital, Buddhist Tzu Chi Medical Foundation, Hualien, Taiwan*

**Introduction:** Expansive open-door laminoplasty (EOLP) is effective for multilevel cervical spondylotic myelopathy (MCSM). When MCSM is combined with one- or two-level segmental kyphosis, instability, or major anterior foci, EOLP with short-segment anterior cervical fusion (ACF) results in good short-term neurological recovery and can preserve the postoperative range of motion. The objective of this study was to evaluate the medium-term clinical outcomes of this procedure and to analyze the risk factors affecting neurological function at the last follow-up.

**Methods:** A total of 73 patients who have received one stage EOLP and ACF from January 2010 to October 2014 were enrolled in this study. These patients exhibited MCSM with combined short segmental kyphosis, instability, or major anterior pathology. The follow-up period lasted at least 8 years. The radiographic outcomes were collected from plain radiographs with dynamic views checked preoperatively and at the last follow-up. Neurological status and Visual Analog Scale scores for neck pain were evaluated. Logistic regression analysis was then applied to determine the correlation between radiographic parameters and rates of neurological recovery.

**Results:** The mean Japanese Orthopaedics Association recovery rate at the last follow-up was 75.4%. The improvement in functional scores and reduction in neck pain were statistically significant. The most influential risk factor affecting neurologic recovery was preoperative functional status. Five of them developed radiographic adjacent segment pathology but none of the patients needed further cervical spine surgery during this follow-up period.

**Conclusions:** EOLP followed by short-segment ACF is a favorable treatment for patients with MCSM with concomi-

tant short-segment kyphosis, instability, or major anterior pathology and had long-term satisfying functional outcomes.

1306

### The Impact on Spinal Deformity Progression among Pediatric Patients with SMA Treated with Nusinersen

Kenny Yat Hong Kwan

*The University of Hong Kong, Hong Kong*

**Introduction:** The lifetime probability of spinal deformity progression reaching the surgical threshold in spinal muscle atrophy (SMA) is high. Although nusinersen treatment has been demonstrated to improve motor function, its impact on scoliosis progression is unknown.

**Purpose:** The objective of this study was to evaluate the impact on spinal deformity progression among pediatric patients with SMA treated with nusinersen.

**Methods:** A retrospective review of prospectively collected data from a territory-wide SMA cohort at our institution who received nusinersen treatment between 2018 and 2021 was performed. Longitudinal radiographic data on spinal deformity progression in the coronal and sagittal planes pre- and post-nusinersen treatment were reviewed. Serial changes in motor function were evaluated using the Children's Hospital of Philadelphia Infant Test of Neuromuscular Disorders and Hammersmith Infant Neurological Examination for type 1 patients; and Hammersmith Motor Functional Scale Expanded, Revised Upper Limb Module, and 6-Minute Walk Test (6MWT) for type 2 and 3 patients. Their ambulatory status was recorded.

**Results:** A total of 21 patients (type 1=7, type 2=7, type 3=7) were included in the analysis. The median age at the time of nusinersen initiation was 6.2 years (range, 0.81–16.6 years), and the mean duration of follow-up was 23 months (range, 6–47 months). During the study period, motor function scores were stable or improved in 18 patients (86%). In terms of ambulatory status after nusinersen administration, 57% of type 1 patients became sitters from being non-sitters at baseline and 14% of type 2 patients became supported walkers from independent sitters. Type 3 patients were also able to walk further in their 6MWT, improving from a baseline median distance

of 50.1 to 73 m at latest assessment. However, scoliosis continued to progress in all subtypes, with a mean rate of Cobb angle increase of 4.8°, 13.8°, and 3.9° per year, respectively. A sub-analysis of each subtype showed that the rate progression was most rapid during ages 5 and 10 years (16.5°, 18.4°, and 4.6° per year for patients with type 1, 2, and 3 SMA respectively).

**Conclusions:** Although nusinersen improved motor function scores in pediatric patients with SMA, it did not prevent the development nor decrease the progression of scoliosis.

1314

### How Paraspinal Atrophy Affects Pain and Function in Degenerative Spinal Conditions? An Analytical Study on Degenerative Disc Disease without Instability and in Spondylolisthesis

Sudarshan Pramod

*Aster Malabar Institute of Medical Sciences, Calicut, India*

**Introduction:** Paraspinal muscle integrity has been implicated to play a critical role in the maintenance of global spinal alignment in turn helping vertebral stabilization and movement. The difference in the impact of paraspinal atrophy in conditions like spondylolisthesis is inconclusive. This study aims to compare the severity of pain and functional deterioration in patients with spondylolisthesis and degenerative lumbar disease without instability and correlate it with paraspinal muscle mass density.

**Methods:** A total of 40 patients were divided into two groups: group A with spondylolisthesis and group B with degenerative lumbar disease without instability. Visual Analog Scale score (VAS score) for pain and Modified Oswestry Disability Index (ODI) score was used for functional assessment. Cross-sectional areas (CSA) of paraspinal muscles (erector spinae, multifidus, and psoas major) to vertebral body ratio were calculated from T2 axial magnetic resonance imaging images at L4 and L5 levels and these values and scores were correlated.

**Results:** Comparing the values in both the groups, the mean CSA to vertebral body ratio for the erector spinae muscle was significantly lower in group B ( $p=0.0442$  at L4,  $p=0.0103$  at L5) whereas that for the multifidus muscle and psoas major was not statistically significant. None of the

general variables significantly predicted any of the muscle area values. VAS score difference and functional outcome between the groups were insignificant. The mean functional score as per Modified ODI was 38.65 (standard deviation [SD]=18.68; range, 12–60) in group A compared to 47.96 (SD=17.36; range, 26.6–71.1) in group B ( $p=0.8717$ ).

**Conclusions:** Patients with degenerative spinal conditions suffer from atrophy of all paraspinal muscles. The higher degree of atrophy of their erector spinae muscle is seen in cases of degenerative disc disease without instability compared to spondylolisthesis.

1342

## Fusion Block Tilt following Corrective Surgery in Lenke 5 Adolescent Idiopathic Scoliosis

Weng Hong Chung

Department of Orthopaedic Surgery (NOCERAL), Faculty of Medicine, Universiti Malaya, Kuala Lumpur, Malaysia

**Introduction:** We observed some Lenke 5 adolescent idiopathic scoliosis (AIS) patients developed fusion block tilt (FBT) following posterior spinal fusion (PSF) surgery. However, its occurrence and outcomes were not previously investigated.

**Methods:** We retrospectively reviewed 100 Lenke 5 AIS patients who had undergone PSF with a minimum 2-year follow-up. FBT was defined as the angle between the longitudinal axis of the fusion block (the line connecting the centroid of the upper instrumented vertebra and the centroid of the lowest instrumented vertebra) with the vertical axis (Fig. 1). The calculated minimal detectable change of FBT was  $1.131^\circ$ . Therefore, we defined the presence of FBT when the measured FBT was  $2^\circ$  or more. Demographic parameters, revised Scoliosis Research Society-22 scores, and radiological parameters were collected and analyzed.

**Results:** At 2 months postoperatively, FBT was found in 81.0% of patients. At final follow-up, patients who developed FBT had larger main thoracic (MT) Cobb angle ( $18.0^\circ \pm 8.5^\circ$  vs.  $13.1^\circ \pm 5.1^\circ$ ,  $p=0.018$ ); larger MT apical vertical translation (MT-AVT) ( $13.7 \pm 9.7$  mm vs.  $6.9 \pm 4.8$  mm,  $p=0.004$ ); and larger disc wedge angle ( $3.7^\circ \pm 3.4^\circ$  vs.  $1.8^\circ \pm 2.3^\circ$ ,  $p=0.021$ ) when compared to those without FBT. And 22% of patients with FBT developed an unacceptable

increase in the main thoracic curve (UIMT) at final follow-up as compared to none among patients without FBT; 37.0% of patients with FBT developed FBT progression of  $2^\circ$  or more at final follow-up. However, there was no significant difference in radiological shoulder outcomes. There was no significant difference in preoperative and final follow-up SRS-22r scores between both groups.

**Conclusions:** AIS patients with Lenke 5 curves may develop FBT following PSF and some may progress over time. Patients who had FBT postoperatively were found to have larger MT curvature, larger MT-AVT, and UIMT at the final follow-up.

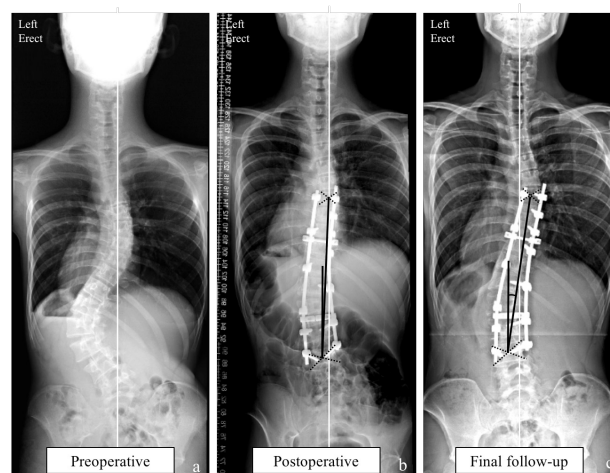


Fig. 1.

1343

## Validation of the Predictive Formula for Optimal Upper Instrumented Vertebra Tilt Angle (Based on Preoperative Erect Radiograph) in Adolescent Idiopathic Scoliosis: A Comparison with the Calculated Optimal Upper Instrumented Vertebra Tilt Angle Derived from the Supervised Supine Side Bending Films

Weng Hong Chung

Department of Orthopaedic Surgery (NOCERAL), Faculty of Medicine, Universiti Malaya, Kuala Lumpur, Malaysia

**Introduction:** The optimal upper instrumented vertebra (UIV) tilt angle was described in 2016 and was calculated based on the supine side bending films (SSBF). This parameter was found to have significant correlation with

medial shoulder and neck balance after posterior spinal fusion in adolescent idiopathic scoliosis patients. Recently we have introduced a predictive formula for the optimal UIV tilt angle based on preoperative erect radiographs. The aim of this study was to validate the predictive formula and compare it with values obtained from the SSBF.

**Methods:** This was a retrospective study involving Lenke 1 and 2 patients. The optimal UIV tilt angle derived from the predictive formula  $(0.396 \times \text{preoperative UIV tilt angle}) - (0.349 \times \text{preoperative T1 tilt angle}) - 0.871$  was P-tilt angle (P-TA). The calculated optimal UIV tilt angle derived from the SSBF was C-tilt angle (C-TA). Correlation study was performed to compare these two values as well as to assess its accuracy for different UIV levels.

**Results:** A total of 134 patients were included, 18 males (13.4%) and 116 females (86.6%). There were 102 (76.1%) Lenke 1 and 32 (23.9%) Lenke 2 patients, respectively. UIV were at T2 (41.8%), T3 (50.0%), and T4 (6.7%) in the majority of patients. The mean preoperative main thoracic Cobb angle was  $66.3^\circ \pm 16.6^\circ$ , with flexibility rate of  $56.8\% \pm 16.4\%$ , correction rate of  $64.7\% \pm 10.4\%$ , and side bending correction index of  $1.2 \pm 0.3$ . The correlation between P-TA and C-TA was 0.678 ( $p < 0.001$ ). For UIV at T2, T3, and T4, the P-TA was  $\leq 3^\circ$  compared with C-TA in 85.7%, 92.6%, and 99.9% of patient, respectively. Conversely 10.8%, 4.5%, and 0.0% of patients had P-TA  $\geq 5^\circ$  compared with C-TA at T2, T3, and T4, respectively.

**Conclusions:** There is significant correlation between P-TA and C-TA. Utilizing the P-TA would reduce the need for additional side bending radiographs. However, the use of P-TA will need to be assessed in larger multi-center studies.

1347

## Comparison of Perioperative Outcomes among Adolescent Idiopathic Scoliosis Patients Operated by a Dedicated Spine Team Approach: Were There Any Differences between the First, Second, and the Last Case?

Sin Ying Lee

Department of Orthopaedic Surgery (NOCERAL), Faculty of Medicine, Universiti Malaya, Kuala Lumpur, Malaysia

**Introduction:** Corrective scoliosis surgery has the potential

risk of major and minor complications. Many recommendations in surgical management had been described with the goal of improving the efficiency and outcomes of these patients. Interest in the concept of a dedicated team for surgical standardization had grown over the years. This is to improve the cost-effectiveness of patient care while achieving desirable operative outcomes.

**Purpose:** The purpose of this study was to compare the perioperative outcomes between the first, second, and last case of the day in adolescent idiopathic scoliosis (AIS) patients who underwent posterior spinal fusion by a dedicated spine team approach.

**Methods:** Data from 123 AIS patients who underwent surgery utilizing a dedicated spine team approach in a single center between the years 2021 and 2022 were retrospectively analyzed. Patients were classified in accordance with the sequence of surgery with case 1 being the first case, case 2 being the second case, and case 3 being the last case of the day. The dedicated team consists of three senior spine consultants who operated using a dual attending surgeon approach, a dedicated anesthetist, operative, and anesthetic nurses, a radiographer as well as operation theatre assistant. Perioperative outcomes measured were operative time, intraoperative blood loss, blood transfusion requirement, hemoglobin level, number of screws used, length of hospital stay (from completion of surgery to the day of discharge), and complication rate.

**Results:** The mean age of patients was  $17.3 \pm 5.2$  years. The mean major Cobb angle was  $64.1^\circ \pm 16.4^\circ$ . There were no significant differences between case 1 (N=41), case 2 (N=41), and case 3 (N=41) in terms of age, gender, body mass index, Lenke classification, Risser grading, and preoperative major Cobb angle ( $p > 0.05$ ). All perioperative outcomes between case 1, case 2, and case 3 were comparable ( $p > 0.05$ ). The mean operative time, intraoperative blood loss, hemoglobin drift, number of screws, and patient-controlled analgesia morphine usage were  $127.8 \pm 32.9$  minutes,  $665.1 \pm 277.9$  mL,  $2.0 \pm 0.8$  g/dL,  $14.3 \pm 2.4$  screws, and  $15.9 \pm 11.2$  mg, respectively. The mean length of hospital stay was  $3.0 \pm 0.2$  days (Table 1). None of the patients required a blood transfusion. The complication rate in this study was 2.4% with three complications. One patient with a superficial surgical site infections requires reoperation. Two patients had superficial surgical site infection which resolved with antibiotics treatment.

**Conclusions:** Implementation of a dedicated spine team

approach led to comparable perioperative outcomes between the first, second, and last case of the day among AIS patients operated in a consecutive case operation list. This could be due to improved efficiency while maintaining standardized patient care.

**Table 1.** Demographic and perioperative outcomes for 123 AIS patients operated by a dedicated spine team approach.

Demographic data	Total N = 123	Case 1 N = 41	Case 2 N = 41	Case 3 N = 41	p value
Age (years)	17.3 ± 5.2	15.9 ± 4.0	17.3 ± 5.2	18.7 ± 6.1	0.050
Gender					0.144
Female	111 (90.2%)	40 (36.0%)	35 (31.5%)	36 (32.4%)	
Male	12 (9.8%)	1 (8.3%)	6 (50.0%)	5 (41.7%)	
Height (cm)	157.0 ± 6.9	156.9 ± 7.0	157.1 ± 6.3	157.2 ± 7.7	0.987
Body weight (kg)	47.0 ± 10.1	47.0 ± 9.1	48.1 ± 11.3	45.9 ± 10.0	0.611
Body mass index (kg/m <sup>2</sup> )	19.0 ± 3.4	19.0 ± 3.1	19.4 ± 3.8	18.5 ± 3.2	0.465
Lenke Classification					0.265
1	56 (45.5%)	20 (35.7%)	19 (33.9%)	17 (30.4%)	
2	19 (15.4%)	4 (21.1%)	8 (42.1%)	7 (36.8%)	
3	1 (0.8%)	0 (0.0%)	1 (100.0%)	0 (0.0%)	
4	3 (2.4%)	0 (0.0%)	1 (33.3%)	2 (66.7%)	
5	34 (27.6%)	16 (47.1%)	9 (26.5%)	9 (26.5%)	
6	10 (8.1%)	1 (10.0%)	3 (30.0%)	6 (60.0%)	
Risser					0.586
0	5 (4.1%)	2 (40.0%)	1 (20.0%)	2 (40.0%)	
1	11 (9.0%)	4 (36.4%)	3 (27.3%)	4 (36.4%)	
2	12 (9.8%)	3 (25.0%)	6 (50.0%)	3 (25.0%)	
3	10 (8.2%)	5 (50.0%)	3 (30.0%)	2 (20.0%)	
4	32 (26.2%)	13 (40.6%)	12 (37.5%)	7 (21.9%)	
5	52 (42.6%)	13 (25.0%)	16 (30.8%)	23 (44.2%)	
Preoperative major Cobb angle (°)	64.1 ± 18.4	59.5 ± 10.9	67.0 ± 17.5	65.8 ± 18.9	0.078
<b>Perioperative outcomes</b>					
Number of screws	14.3 ± 2.4	13.6 ± 2.6	14.6 ± 2.1	14.7 ± 2.4	0.074
Operative time (mins)	127.8 ± 32.9	119.2 ± 29.3	128.5 ± 27.9	135.8 ± 39.1	0.070
Intraoperative blood loss (mL)	665.1 ± 277.9	615.4 ± 218.9	680.1 ± 314.1	699.9 ± 291.4	0.358
Blood transfusion					-
No	123 (100.0%)	41 (33.3%)	41 (33.3%)	41 (33.3%)	
Yes	0 (0.0%)	0 (0.0%)	0 (0.0%)	0 (0.0%)	
Preoperative Hb level (g/dL)	13.4 ± 1.2	13.3 ± 0.9	13.4 ± 1.3	13.5 ± 1.3	0.707
Postoperative Hb level (g/dL)	11.4 ± 1.1	11.3 ± 0.9	11.3 ± 1.3	11.6 ± 1.2	0.471
Hb drift (g/dL)	2.0 ± 0.8	2.0 ± 0.6	2.1 ± 0.9	2.0 ± 0.8	0.852
PCA morphine usage (mg)	15.9 ± 11.2	17.9 ± 12.0	14.5 ± 9.0	15.2 ± 12.3	0.337
Length of hospital stay	3.0 ± 0.2	3.0 ± 0.2	3.0 ± 0.2	3.0 ± 0.2	0.518
Complication rate					0.772
Yes	3 (2.4%)	0 (0.0%)	2 (66.7%)	1 (33.3%)	
No	120 (97.6%)	41 (34.2%)	39 (32.5%)	40 (33.3%)	

Values expressed in number (percentage) or mean ± standard deviation.  
Hb: haemoglobin; PCA: Patient-controlled analgesia; Length of hospital stay (from completion of surgery to the day of discharge)

utilization while maintaining standard patient care.

**Purpose:** To report on the efficiency of OT utilization with a dedicated spine team approach for posterior spinal fusion surgeries (PSF) in adolescent idiopathic scoliosis (AIS) patients while demonstrating standardization of patient outcomes in terms of different stages of OT time and intraoperative blood loss.

**Methods:** This was a retrospective study of three AIS patients operated in a day, i.e., from 8 AM to 8 PM, by a dedicated spine team in a single academic institution between year 2021 and 2022. A dedicated spine team comprised of three senior spine consultants who operated using a dual attending surgeon strategy, an anesthetic consultant, dedicated surgical scrub nurses, anesthesiology nurses, radiographers, and neuromonitoring technicians assigned to all spine surgeries. All cases were performed according to the standardized protocols including patient preparation (patient transport, positioning, and draping), anesthesia protocol, image intensifier use, surgical techniques, and postoperative protocol. All team members were familiar with the standardized protocols. Primary outcomes measured were preoperative time (time interval between patient's entry to OT and initiation of skin incision), operative time (time interval between initiation of skin incision and completion of skin closure), postoperative time (time interval between completion of skin closure and exit from OT), total OT time (time interval between entry to OT and exit from OT), intraoperative blood loss, and blood transfusion requirement.

**Results:** A total of 102 AIS cases were recruited where on average, three cases were operated per day from 8 AM to 8 PM (Fig. 1). The mean age was 17.2±5.4 years with mean major Cobb angle of 63.3°±15.5°. The mean preoperative, operative, postoperative, and total OT time for case 1 were 37.4±4.9 minutes, 117.6±29.6 minutes, 14.4±6.1 minutes, and 169.4±31.3 minutes, respectively. OT timing for case 2 were 36.9±5.4 minutes, 125.4±25.1 minutes, 13.7±3.7 minutes, and 174.6±25.8 minutes, respectively whereas case 3 were 37.6±5.4 minutes, 125.8±29.4 minutes, 17.0±12.1 minutes, and 180.4±31.4 minutes, respectively. Case 1 to 3 had comparable OT timing for all stages ( $p>0.05$ ). Intraoperative blood loss for case 1 to 3 were 616.6±225.4 mL, 649.4±275.6 mL, and 648.6±260.1 mL, respectively ( $p=0.832$ ). None of the patients received blood transfusion (Table 1).

**Conclusions:** With a dedicated spine team approach, we can optimize the OT utilization without compromising

1349

## A Dedicated Spine Team Approach Optimized the Efficiency of Operating Theatre Utilization While Maintaining a Standard Patient Care in Adolescent Idiopathic Scoliosis Surgery

Sin Ying Lee

Department of Orthopaedic Surgery (NOCERAL), Faculty of Medicine, Universiti Malaya, Kuala Lumpur, Malaysia

**Introduction:** Many protocols had been established to improve healthcare cost efficiency by optimizing utilization of operating theatre (OT). OT utilization is one of the costliest constituents in the healthcare system. In view of high cost incurred in spine deformity surgeries, a dedicated spine team had been assembled to optimize OT

patient care by performing surgery on three AIS cases in a day. The OT timing and intraoperative blood loss for each stage were comparable between the first, second, and last case operated on the day.

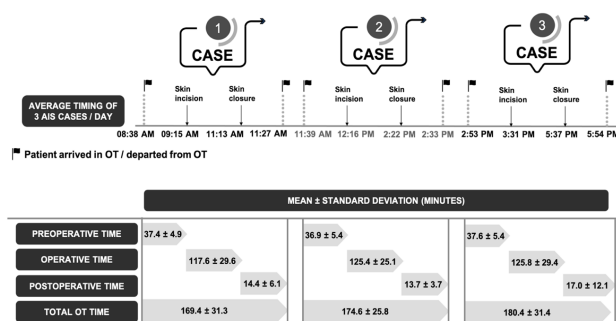


Figure 1. Illustration of average timing for 3 AIS cases performed by a dedicated spine team per day and the mean ± standard deviation for preoperative, operative, postoperative and total operating theatre (OT) time ( $p > 0.05$ ).

Table 1. Demographic, preoperative, and operative data for 102 AIS patients operated by a dedicated spine team approach.

	Case 1 N = 34	Case 2 N = 34	Case 3 N = 34	Total N = 102	p value
Age (years)	15.7 ± 4.1	17.5 ± 5.4	18.3 ± 6.2	17.2 ± 5.4	0.118
Gender					0.288
Female	33 (35.5%)	29 (31.2%)	31 (33.3%)	93 (91.2%)	
Male	1 (11.1%)	5 (55.6%)	3 (33.3%)	9 (8.8%)	
Height (cm)	157.6 ± 6.9	156.8 ± 6.6	156.2 ± 6.9	156.9 ± 6.8	0.691
Body weight (kg)	46.5 ± 9.2	48.8 ± 11.4	45.3 ± 10.5	46.9 ± 10.4	0.392
Body mass index (kg/m <sup>2</sup> )	18.7 ± 3.2	19.7 ± 3.8	18.5 ± 3.5	19.0 ± 3.5	0.284
Lenke Classification					0.687
1	15 (32.6%)	14 (30.4%)	17 (37.0%)	46 (45.1%)	
2	4 (23.5%)	7 (41.2%)	6 (35.3%)	17 (16.7%)	
3	0 (0.0%)	1 (100.0%)	0 (0.0%)	1 (1.0%)	
4	0 (0.0%)	1 (33.3%)	2 (66.7%)	3 (2.9%)	
5	14 (46.7%)	9 (30.0%)	7 (23.3%)	30 (29.4%)	
6	1 (20.0%)	2 (40.0%)	2 (40.0%)	5 (4.9%)	
Risser					0.447
0	2 (40.0%)	1 (20.0%)	2 (40.0%)	5 (4.9%)	
1	3 (30.0%)	3 (30.0%)	4 (40.0%)	10 (9.8%)	
2	3 (25.0%)	6 (50.0%)	3 (25.0%)	12 (11.8%)	
3	5 (55.6%)	3 (33.3%)	1 (11.1%)	9 (8.8%)	
4	12 (44.4%)	8 (29.6%)	7 (25.9%)	27 (26.5%)	
5	9 (23.1%)	13 (33.3%)	17 (43.6%)	39 (38.2%)	
Preoperative major Cobb angle (°)	59.3 ± 9.4	65.4 ± 17.0	65.2 ± 18.2	63.3 ± 15.5	0.185
Preoperative Hb level (g/dL)	13.2 ± 0.9	13.3 ± 1.3	13.4 ± 1.3	13.3 ± 1.2	0.851
Intraoperative blood loss (mL)	616.6 ± 225.4	649.4 ± 275.6	648.6 ± 260.1	638.2 ± 252.5	0.832
Intraoperative ABG					
pH	7.37 ± 0.03	7.36 ± 0.03	7.36 ± 0.04	7.36 ± 0.03	0.617
PaO <sub>2</sub> (mmHg)	222.0 ± 40.3	219.2 ± 37.1	214.4 ± 30.3	218.6 ± 36.0	0.682
PaCO <sub>2</sub> (mmHg)	41.3 ± 2.1	41.5 ± 2.1	41.1 ± 2.3	41.3 ± 2.2	0.695
HCO <sub>3</sub> <sup>-</sup> (mmol/L)	23.1 ± 1.5	22.9 ± 1.5	22.6 ± 1.5	22.9 ± 1.5	0.373
Base excess	-1.6 ± 1.9	-1.9 ± 1.9	-2.3 ± 1.9	-1.9 ± 1.9	0.379
Lactate (mmol/L)	1.3 ± 0.6	1.6 ± 2.1	1.2 ± 0.4	1.4 ± 1.3	0.466
Postoperative Hb level (g/dL)	11.2 ± 0.9	11.2 ± 1.2	11.4 ± 1.1	11.3 ± 1.1	0.611
Blood transfusion					-
No	34 (33.3%)	34 (33.3%)	34 (33.3%)	102 (100.0%)	
Yes	0 (0.0%)	0 (0.0%)	0 (0.0%)	0 (0.0%)	
OT time for each stage					
Preoperative time (mins)	37.4 ± 4.9	36.9 ± 5.4	37.6 ± 5.4	37.3 ± 5.2	0.856
Operative time (mins)	117.6 ± 29.6	125.4 ± 25.1	125.8 ± 29.4	123.0 ± 28.1	0.402
Postoperative time (mins)	14.4 ± 6.1	13.7 ± 3.7	17.0 ± 12.1	15.0 ± 8.2	0.213
Total OT time (mins)	169.4 ± 31.3	174.6 ± 25.8	180.4 ± 31.4	174.8 ± 29.7	0.308

Values expressed in number (percentage) or mean ± standard deviation.

ABG: arterial blood gas; Hb: haemoglobin; Pa: partial pressure in arterial blood; O<sub>2</sub>: oxygen; CO<sub>2</sub>: carbon dioxide, HCO<sub>3</sub><sup>-</sup>: bicarbonate; OT: operating theatre

## 1356

### Hip-Spine Syndrome: Which First and Which Last Longer?

Shih-Tien Wang

Kinmen Hospital, Ministry of Health and Welfare, Jinhu, Taiwan

**Introduction:** It is common to meet the clinical picture that patients with buttock, groin, and thigh pain with the presence of degenerative disease of both the hip and the spine. Since the referred pain pattern from the lumbar spine and hip joint were similar, suggesting that the pathological changes might be interrelated. Because of the overlap of symptoms, the proper diagnosis and treatment of this pathological condition can present a substantial challenge to even the most skilled specialists. Especially when the lesion site from both was severe enough to warrant surgery, it may be difficult to decide on the optimal order of treatment. The aim of this study was to discuss in patients with the complex hip-spine syndrome, accepting hip replacement first or spine surgery first can experience a longer duration of pain relief.

**Methods:** This is a retrospective study. From September 2006 to September 2019, patients with complex hip-spine syndrome who underwent lumbar spine surgery, hip replacement, or both were included. Group A comprised patients who underwent hip first and then underwent lumbar surgery. Group B comprised patients who underwent lumbar surgery first and then underwent a hip replacement. Group C comprised patients who accepted hip replacement first and experienced enough pain relief and did not need further lumbar surgery. The exclusion criteria included patients who accepted previous spine or hip surgery, symptomatic spinal stenosis, metastasis cases, and patient who accepted both surgeries within 3 months. We evaluated the surgical outcome with preoperative and postoperative Oswestry Disability Index questionnaire and preoperative and postoperative Visual Analog Scale pain score. In patients who accepted both kinds of surgeries (group A and group B), we compared the duration between the two surgeries. Evaluating which kind of surgeries can provide longer discomfort relief.

**Results:** A total of 148 patients were included in this study. Group I comprised 48 patients with age 73.8±11.4 years, group II comprised 28 patients with age 70.8±12.8 years, and group III comprised 72 patients with age 64.6±12.51



years. The patient's age was not significantly different between group I and II but significantly younger in group III ( $p < 0.001$ ). The duration between surgeries is 55.1 months in group A and 25.4 months in group B with a significant difference ( $p = 0.029$ ).

**Conclusions:** In patients with both hip lesions and lumbar spinal stenosis without the obvious neurological deficit and no obvious primary pain source, hip replacement provides a longer duration of discomfort relief compared with lumbar spine surgery. Most patients who presented with complex hip spine syndrome experienced resolution or improvement of their pain after hip replacement.

1390

## Perception of Spinal Deformity among Patients with Adolescent Idiopathic Scoliosis

Matthew Song Peng Ng

*Yong Loo Lin School Of Medicine, National University of Singapore, Singapore*

**Introduction:** Adolescent idiopathic scoliosis (AIS) is the most common form of structural spinal deformity, affecting 1% to 4% of children globally. Patients with AIS are generally pain-free; however, some might be able to perceive their skeletal deformity, thus affecting their self-image. Major Cobb angle, coronal balance, and truncal balance are radiological measurements used to evaluate AIS severity. The threshold of spinal deformity that alters patients' perception of their deformity is not known.

**Purpose:** (1) To determine the correlation of the severity of scoliotic deformity using radiological measurements of major Cobb angle, coronal balance, truncal balance, and curve type with an established validated revised Scoliosis Research Society-22 (SRS-22r) instrument consisting of an overall score and five domains of self-image, pain, function, mental health, and satisfaction. (2) To evaluate other demographic factors such as curve type, gender, and age affecting the patient perception of scoliotic deformity.

**Methods:** A retrospective analysis of prospectively collected SRS-22r data from 357 consecutive patients between February 2020 and May 2021 was conducted. Inclusion criteria were (1) 11 to 20 years old, (2) no leg length discrepancy, and (3) underwent scoliosis screening at our tertiary institution. Each patient completed their SRS-22r

questionnaire online prospectively. Standing erect radiographs of the patients were obtained using an EOS Imaging System. Radiological measurements were obtained by one researcher and confirmed by an orthopedic spine surgeon. The major Cobb angle was measured as the angle between the two end vertebrae of the largest curve. The coronal balance was measured as the horizontal distance between a plumb line drawn from the C7 vertebra and a vertical line bisecting the sacrum. The truncal balance was measured as the horizontal distance between a vertical line bisecting the thoracic cavity and a vertical line bisecting the sacrum. Patients were also categorized as having a single curve (one major curve with a minor compensatory curve) or a double curve (two curves with less than 5° difference in Cobb angles).

**Results:** Major Cobb angle and truncal balance had a significant but small negative correlation with SRS-22r. The coronal balance had no significant correlation with SRS-22r. Multiple regression showed that skeletal deformity (as measured by major Cobb angle and truncal balance) significantly affected self-image but not pain for patients with a major Cobb angle of 51°–60° ( $R^2 = 0.265$ ,  $p < 0.01$ ), 61°–70° ( $R^2 = 0.528$ ,  $p < 0.01$ ), and above 70° ( $R^2 = 0.277$ ,  $p < 0.01$ ). Skeletal deformity also significantly affected the self-image of patients with a single curve ( $R^2 = 0.117$ ,  $p < 0.01$ ), patients who are female ( $R^2 = 0.139$ ,  $p < 0.01$ ), and patients who are 14 years old and above ( $R^2 = 0.252$ ,  $p < 0.01$ ).

**Conclusions:** In our cohort, patients only started perceiving their scoliotic deformity when their major Cobb angle is above 50°. Patients who have a single curve were more likely to perceive their deformity than those with a double curve. Female patients and those who were 14 years old and above are more likely to perceive their deformity. Lastly, there was no clear relationship between pain and scoliosis.

1405

## Assessment of Biomechanical Advantages in Combined Anterior-Posterior Cervical Spine Surgery by Radiologic Outcomes: Pedicle Screw over Lateral Mass Screw

Sang-Ho Kim

Department of Orthopaedic Surgery, Yonsei University College of Medicine, Seoul, South Korea

**Introduction:** The combined anterior-posterior approach has shown better clinical outcomes for multi-level cervical spondylotic myeloradiculopathy and degenerative kyphosis cases. Traditionally, posterior fixation in the combined approach has been achieved using lateral mass screws. However, with the development of insertion techniques and advantages in load-sharing properties from biomechanical studies, cervical pedicle screws have been proposed as an alternative in certain cases.

**Purpose:** To assess the biomechanical advantage of cervical pedicle screw fixation over lateral mass screw fixation in combined anterior-posterior decompression and fusion cases.

**Methods:** Seventy-six patients received anterior-posterior combined cervical surgery for myelopathy or radiculopathy or both from June 2013 to December 2020. Patients were divided into two groups: the lateral mass screws (LMS) group and the posterior pedicle screws (PPS) group. Lateral cervical spine X-rays were taken for all patients at preoperative, immediate postoperative, 3-month follow-up, and 1-year follow-up periods. Differences in radiologic outcomes between the two groups were assessed statistically. The C2–C7 cervical lordosis and C2–C7 sagittal vertical axis were used for the cervical sagittal balance. Subsidence was defined as a decrease in the vertebral body height. For vertebral body remodeling, the amount of vertebral body width change was checked.

**Results:** There were 40 patients in the LMS group, and the total number of segments was 153. Thirty-six patients belonged to the PPS group, with 152 segments operated in total. At 1 year postoperatively, the number of patients whose C2–C7 cervical lordosis was less than 20° decreased larger in the PPS group ( $p=0.001$ ). The amount of vertical height change from immediate to 1-year post-surgery was less in the PPS group than in the LMS group ( $p=0.030$ ). The mean vertebral body width change was

larger in the PPS group than in the LMS group, during 3 months to 1-year post-surgery ( $p=0.000$ ).

**Conclusions:** In anterior-posterior combined cervical surgery cases, maintenance of cervical lordosis and protection of the vertebral body from subsidence was better in the pedicle screw fixation than the lateral mass screw fixation. More bone remodeling as of resorption occurred in the anterior portion of the vertebral body-allograft spacer constructs when using the pedicle screw fixation method.

1408

## Difference of Postoperative Radiologic Change on Sacro-Iliac joint by Multi-factors in Adolescent Idiopathic Scoliosis

Sang-Ho Kim

Department of Orthopaedic Surgery, Yonsei University College of Medicine, Seoul, South Korea

**Introduction:** Postoperative pain after mechanical correction and fusion in adolescent idiopathic scoliosis (AIS) has always been a major concern for spine surgeons. It is hard to find reasonable causes for that kind of pain because AIS patients were so young and had a low chance of other past histories. Generally, 15% of primary back pain or lower extremity pain is based on the sacro-iliac (SI) joint, so we focused on the change of the SI joint after the fusion operation. This study aims to investigate the postoperative radiologic change of SI joints in AIS patients.

**Methods:** Patients who underwent mechanical correction and fusion operations at our hospital from 2005 to 2017 were selected as the study subjects. Patients with past history related to SI joint and delivery, or with inaccurate radiographs were excluded. We evaluated X-ray or computed tomography scans for SI joints for all patients on preoperative, immediate postoperative, 6-month, 1-year, 2-year, and 5-year postoperative periods. We measured fusion level, sagittal parameter of the whole spine, and parameters for evaluating scoliosis, for investigation of differences in radiologic change by them.

**Results:** Comparing the two groups, more radiologic changes of SI joint were observed in patients who received fusion up to L3 and L4. Preoperative Cobb's angle of the major thoracic or thoracolumbar curve was not related to SI joint change, and neither did postoperative Cobb's angle

and amount of corrected angle. But the amount of Cobb's angle change showed a significant difference between SI joint change group and the non-change group. Sagittal parameters (lumbar lordosis, thoracic kyphosis, pelvic incidence, etc.) were also unrelated to SI joint changes.

**Conclusions:** Posterior fusion up to L3 and L4 caused more radiologic degenerative changes of the SI joint than fusion to upper L3.

1420

### Comparison of the Assessment of Sanders Skeletal Maturity Using Single Low Radiation Dose EOS Spine Hand Radiography and Conventional Hand Radiography

Glenys Poon

*National University Hospital, Singapore*

**Introduction:** Bracing is recognized as an effective treatment method in the prevention of curve progression for adolescent idiopathic scoliosis (AIS) in skeletally immature patients with moderate curves. Bone age is an important factor in determining initiation and conclusion of bracing with the Sanders skeletal maturity scale (SSMS) shown to be a reliable indicator of skeletal maturity with good correlation to peak growth velocity. Currently, this is based on a separate left-hand posterior-anterior (PA) radiograph, which requires additional radiation. In recent years, there is increasing popularity of the EOS slot-scanning system (EOS Imaging, Paris, France) for the assessment of AIS due to its significantly reduced radiation dose. With the goal of reducing radiation exposure and improving the efficiency of clinic visits, this study aims to determine if a simultaneously performed low-dose EOS spine-hand radiograph would provide adequate image quality to allow for accurate assessment of skeletal maturity based on SSMS in AIS patients.

**Methods:** Radiographs from AIS patients aged 10–21 years over a time period of 1 year who had consecutively undergone both a low-dose EOS spine-hand radiograph taken with the left hand positioned above the left shoulder and a conventional hand radiograph were selected. These radiographs were anonymized and collated into a viewing document. Twelve trained spine surgeons then reviewed these radiographs and graded the skeletal maturity of the

patient using SSMS based on both the EOS Spine-hand radiographs and the conventional PA hand radiograph imaging. Their responses were then analyzed and used to determine the agreement between the grading of the skeletal maturity across 2 imaging modalities using SSMS with conventional imaging as the gold standard reference point. Intra-class correlation coefficients were also used to determine the reliability of both the grading system and the imaging modalities.

**Results:** A total of 240 radiographs (80 conventional, 80 EOS, and 80 inverted EOS images) were selected from 122 AIS patients who presented between July 2020 and July 2021. The absolute agreement in skeletal maturity grading between EOS imaging and conventional radiography was 61.2% using the SSMS method. And 91.2% of responses fell within a single grade point difference with 21.3% of responses reflecting a single point positive deviation grading and 9.2% of responses reflecting a single point negative deviation grading. Intra-class coefficients across the 12 respondents using the SSMS were 0.912 for conventional imaging and 0.850 for EOS imaging.

**Conclusions:** Although the absolute agreement in skeletal maturity grading using SSMS between EOS imaging and a conventional radiograph was less than expected at 61.2%, the fact that 91.2% of responses fell within a single-point difference is encouraging. Furthermore, not only is the intra-class coefficient of 0.850 for EOS imaging using SSMS across 12 respondents high but it is also similar to the reference standard of 0.912 for conventional imaging, indicating a high inter-rater reliability of the SSMS even with the EOS imaging. Overall, these results suggest that EOS imaging provides adequate image quality for the grading of skeletal maturity using SSMS and can be considered a viable substitute for conventional imaging.

1446

### Erector Spinae Atrophy/Fatty Infiltration Is a Risk Factor for the Development of Adult Spinal Deformity: Results of a 6-Year Follow-up of a Large Cohort of Residents

Keiji Nagata

*Wakayama Medical University, Wakayama Japan*

**Introduction:** The purpose of this study was to identify

predictors of adult spinal deformity (ASD) occurrence/progression in a longitudinal study.

**Methods:** This longitudinal cohort study was part of the Japanese Research on Osteoarthritis, Osteoporosis Against Disability (ROAD) study. A total of 796 participants in T-town, Wakayama Prefecture, were included in this study. And 538 (158 males and 380 females; mean age,  $60.3 \pm 12.2$  years) were eligible for evaluation of standing lateral radiographs and baseline magnetic resonance imaging (MRI) of the whole spine. They were followed up for 6 years. Lumbar spine (L1/2–5/S) disc degeneration (sum of Pfirrmann grade: 5–25), the sum of the thoracolumbar spine (T1–L5) morphological fracture grade (0–51) (Fx-index), cross-sectional area (CSA:  $\text{mm}^2$ ) of paravertebral muscle (multifidus, erector spinae), and psoas major and fatty infiltration ratio (FIR: %) were measured. The progression (P) group was defined as those who met the following two conditions: (1) baseline pelvic tilt  $>20^\circ$ , (2) C7 SVA  $>50$  mm progression, and SVA  $>50$  mm.

**Results:** The incidence of ASD was 23 (9.6%). Regarding MRI, the sum of Pfirrmann grade ( $4.1 \pm 4.2$ ,  $2.3 \pm 3.5$ ;  $p=0.0125$ ), Fx-index ( $19.8 \pm 1.9$ ,  $18.0 \pm 2.6$ ;  $p=0.0008$ ), erector spinae CSA ( $11.8 \pm 3.2$ ,  $13.3 \pm 3.3$ ;  $p=0.022$ ), FIR (erector spinae:  $12.0 \pm 8.0$ ,  $7.0 \pm 3.2$ ;  $p<0.0001$ ; multifidus:  $16.2 \pm 4.6$ ,  $12.4 \pm 4.4$ ;  $p<0.0001$ ) were significantly different among two groups, while no significant differences were observed in CSA and FIR in the psoas major muscle. Multiple logistic regression analysis (after adjustment for age, gender, and body mass index) was used to determine the association between each parameter and ASD. There were significant differences in erector spinae cross-sectional area (+1 mm; odds ratio [OR], 0.78; 95% confidence interval [CI], 0.63–0.95;  $p=0.0129$ ) and erector spinae FIR (+1%; OR, 1.1; 95% CI, 1.02–1.20;  $p=0.0106$ ) were predictors of the development of ASD.

**Conclusions:** Erector spinae muscle CSA/FIR is the most important factor that can cause ASD progression.

1578

## Total *En-Bloc* Spondylectomy versus Stereotactic Ablative Body Radiotherapy in Patients with Single Spinal Metastasis

Dong-Ho Kang

Department of Orthopaedic Surgery, Seoul National University Hospital, Seoul, South Korea

**Introduction:** Total *en-bloc* spondylectomy (TES) is the traditional surgical treatment of primary spinal tumors. TES can achieve low tumor recurrence, but there are also disadvantages including surgical site infection, weakness, and pneumonia. Since the introduction of stereotactic ablative radiotherapy (SABR) which delivers a higher dose of radiation to target tissues while minimizing the dose exposure to normal tissue, the therapeutic role of TES in spinal metastasis has been diminished. While previous studies on TES or SABR, respectively, have reported their efficiency in achieving good local control rates and improving survival rates, information is still lacking about comparing the efficacy of the two different types of treatment.

**Purpose:** The purpose of our study is to compare TES and SABR in patients with single spinal metastasis by assessing local recurrence, and overall survival.

**Methods:** This is a retrospective study from a single tertiary hospital. We included all patients who underwent TES or SABR in patients with single spinal metastasis since 2000. Patients' demographics including performance status, and oncologic information including primary tumor type, the New England Spinal Metastasis Score (NESMS), and modified Tokuhashi score were reviewed. Information on recurrence and survival after treatment was checked through a review of electronic medical records, picture archiving, and communication systems, and a request of the Ministry of Public Administration and Security of the country. For the between-group comparison, we used only the follow-up data collected up to 97.7 months in the TES group, which was the longest follow-up period in the SABR group, and we did exact matching of patients with the primary origin, NESMS, and modified Tokuhashi score. Survival analysis was performed on both all patients and matched patients.

**Results:** A total of 90 patients were included, with 20 patients receiving TES and 70 patients receiving SABR, with

a mean follow-up of 35.4 months. The cumulative 12, 24, and 60-month local progression rates among matched patients were 5.6%, 12.8%, and 21.5% in the TES group, and 31.0%, 43.5%, and 43.5% in the SABR group, respectively. Kaplan-Meier curve about the local progression among matched patients showed no significant difference between the TES and SABR group ( $p=0.133$ ) (Fig. 3). Survival analysis of matched patients also showed no significant difference between TES and SABR group for the survival period (median [95% confidence interval]: 55.2 months [40.8–69.6] vs. 41.0 months [0.0–93.4];  $p=0.207$ ) (Fig. 4). TES group had a higher rate of major complications such as paralysis.

**Conclusions:** There was no significant difference in survival between the groups receiving TES and SABR in patients with single spinal metastasis. It is expected that the role of SABR will increase in the future.

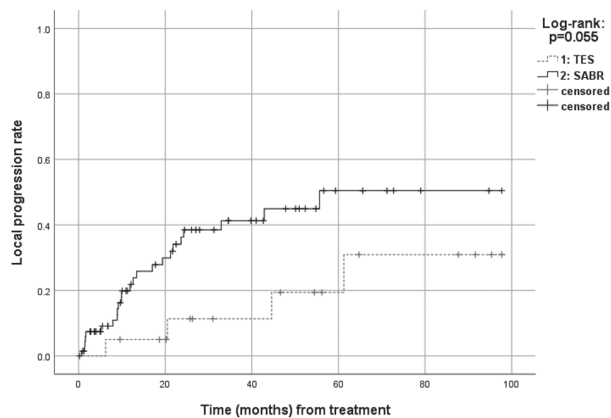


Fig. 1. Kaplan-Meier curve for local progression of all patients.

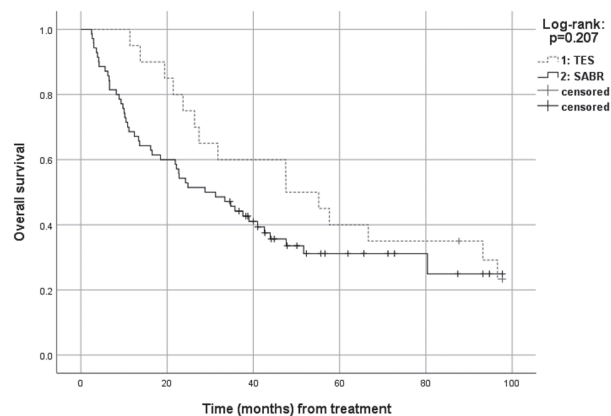


Fig. 2. Kaplan-Meier curve for overall survival of all patients.

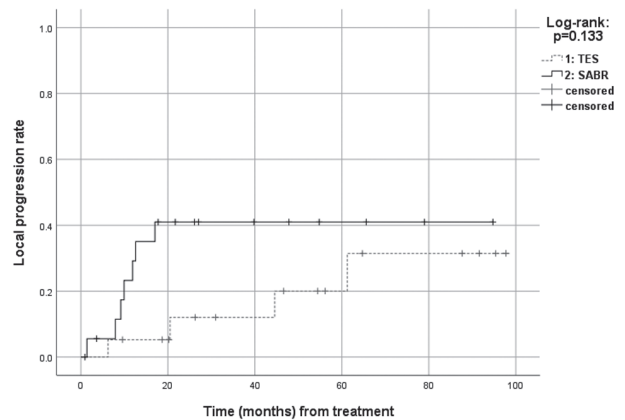


Fig. 3. Kaplan-Meier curve for local progression of matched patients.

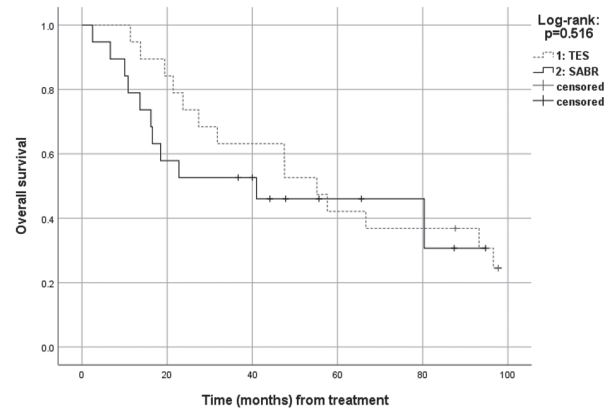


Fig. 4. Kaplan-Meier curve for overall survival of matched patients.

1647

## The Risk of Injury to the Internal Carotid Artery during C1 Lateral Mass Screw Fixation

Ryo Kitagawa

Saiseikai Kanazawa Hospital, Kanazawa, Japan

**Introduction:** C1 lateral mass screw fixation poses a risk of injury to the internal carotid artery (ICA) that locates anteriorly to the lateral mass. Few reports described injury of ICA caused by C1 screws. This study aimed to assess the anatomical relationship of ICA and C1 lateral mass and to evaluate the risk of injury to the ICA during C1 lateral mass screw fixation.

**Methods:** The author retrospectively analyzed 246 ICAs in 123 patients who underwent computed tomography angiography of the cervical spine, 65 males and 58 females, with an average of 63.8 years old, to assess the position of the ICA in association with the C1 lateral mass. For pa-

tients with an ICA ventral to the lateral mass, the shortest distance between the ICA and the anterior cortex of lateral mass was measured to evaluate the risks of ICA injury. The sagittal distance from the anterior cortex of the lateral mass to the anterior arch apex and the odontoid process was also measured as the landmark for a tip of the bicortical screw.

**Results:** Fifty-seven out of 123 patients (46.3%, 42 unilaterally, 15 bilaterally) had the ICA in front of the C1 lateral mass, indicating the at-risk region. The remaining 65 patients had the ICA lateral to the C1 lateral mass. None had the ICA medial to the lateral mass. For those 57 patients in whom the ICA was in the at-risk region, the mean shortest distance between the ICA and the anterior surface of the C1 lateral mass was 4.5 mm (range, 0.9–10.2 mm) (Fig. 1). The mean sagittal distance from the anterior cortex of the lateral mass to the tips of the anterior tubercle and odontoid process was 6.5 mm and 1.8 mm, respectively (Fig. 2). Those patients with ICA in the at-risk region significantly had higher ages and hypertension than those without at-risk ICA (Mann-Whitney *U* test, chi-square test,  $p < 0.05$ ).

**Conclusions:** A high percentage of patients demonstrate an ICA directly ventral to the C1 lateral mass, which poses a risk of ICA injury caused by an over-penetrated bicortical screw. Using lateral fluoroscopy helps visualize landmarks for the ideal position of the tips of bicortical screws. Our results showed that the majority of the anterior cortex of the lateral mass was behind the anterior tubercle of C1 and slightly anterior to the odontoid.

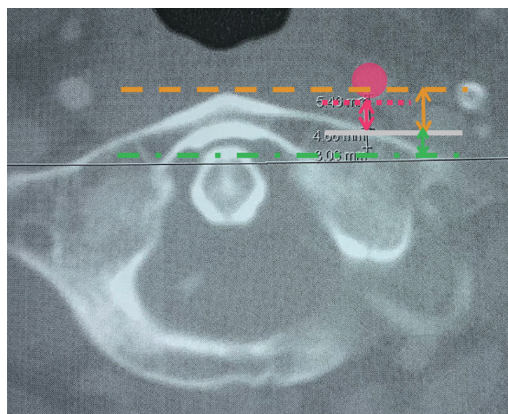


Fig. 1.

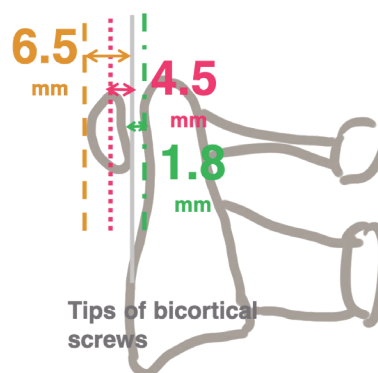


Fig. 2.

1663

## What Makes Them Stay? A Study on Effects of Socioeconomic Indicators on Length of Stay and Postoperative Rehabilitation Following Minimally Invasive Transforaminal Lumbar Interbody Fusion

Ramkumar Mohan

Singapore General Hospital, Singapore

**Introduction:** The patient undergoing spine surgery must comprehend an alphabet soup of terminology and procedure risks and understand rehabilitation goals. This may not be possible for all patients from varied backgrounds, and this can have implications for the postoperative outcome. This study investigates the effects of socioeconomic indicators on length of stay (LOS) as well as rehabilitation targets following minimally invasive transforaminal lumbar interbody fusion (MIS-TLIF).

**Methods:** We analyzed socioeconomic status (SES) factors at the individual level using room index which is based on the tiered-subsidy housing system in Singapore. Secondly, we use Socioeconomic Disadvantage Index (SEDI) and Socioeconomic Advantage Index (SAI) to compare SES at the neighborhood level. Recruitment of consecutive patients that underwent single and double-level MIS-TLIF procedures from August 2015 to August 2022 across two institutions was included in the study. We derived patient postal codes from records and cross-referenced them with the national database to derive individual patient room index (equation for room index: total [number of rooms in a flat × number of such flats per block] / total number of units in a block). SEDI and SAI indices were obtained

from a public policy paper by Earnest and his colleagues. After comparative analysis, at individual and neighborhood levels, the analysis was repeated with propensity score matching at a 1:1 ratio.

**Results:** A total of 221 patients were analyzed. And 115 (52.0%) of our total cohort were female patients and the overall median LOS was 4 days (interquartile range, 2.00–6.00 days). When room index values were compared (Table 1), no significant differences were noted in terms of LOS, intraoperative variables, postoperative complications, and follow-up compliance. Similarly, when unmatched cohorts stratified by neighborhood-based SES indicators were compared, no significant differences were noted. However, in these unmatched cohorts, there were numerical trends towards shorter LOS in individuals from neighborhoods with higher SAI (4.00 [3.00–7.00] vs. 3.00 [2.00–5.00],  $p=0.092$ ). Congruent numerical trends were noted in individuals in neighborhoods with higher disadvantage scores having longer LOS (4.00 [3.00–6.00] vs. 3.00 [2.00–6.00],  $p=0.156$ ). After matching cohorts, there was a significantly shorter LOS noted amongst patients living in neighborhoods with higher advantage scores ( $n=73:73$ ) (4.00 [3.00–6.25] vs. 3.00 [2.00–5.00],  $p=0.035$ ). There was also a non-significant trend towards patients with higher neighborhood advantage scores having a lower number of physiotherapy sessions needed before being discharged (3.83 [2.41] vs. 2.82 [1.44],  $p=0.071$ ). We noted a complementary non-significant trend towards patients with higher disadvantage scores having longer LOS after matching (4.00 [3.00–6.00] vs. 3.50 [2.00–5.70],  $p=0.297$ ).

**Conclusions:** Significant differences in cohorts stratified by neighborhood SES indicators suggest that patients with better neighborhood advantage indices had shorter LOS and fewer physiotherapy requirements. These findings were supported by numerical trends amongst patients with higher disadvantage scores having longer LOS. We believe that this paper provides a novel take on studying LOS post-TLIF procedures. We surmise that a spine patient originating from an advantaged neighborhood may potentially have a better understanding of a commonly performed procedure and will likely have a successful outcome in terms of length of stay and improved physiotherapy outcomes. We wish that the findings of this paper can be used in understanding the socioeconomic factors involved in successful understanding and subsequent postoperative care for patients undergoing routine spine surgery.

**Table 1.** Length of stay compared against neighborhood and individual indices (matched and unmatched cohorts)

	Median (interquartile range)	<i>p</i> -value
Unmatched analysis		
Individual analysis		
Room index <4	3.00 (3.00–5.00)	0.892
Room index ≥4	4.00 (2.00–6.00)	
Neighborhood analysis		
SAI ≤95.4	4.00 (3.00–7.00)	0.092
SAI >95.4	3.00 (2.00–5.00)	
Neighborhood analysis		
SEDI ≤100.2	3.00 (2.00–6.00)	0.156
SEDI >100.2	4.00 (3.00–6.00)	
Matched analysis		
<i>n</i> =70:70, Individual analysis		
Room index <4	3.50 (2.25–5.00)	0.413
Room index ≥4	3.00 (2.00–6.00)	
<i>n</i> =73:73, Neighborhood analysis		
SAI ≤95.4	<b>4.00 (3.00–6.25)</b>	<b>0.035</b>
SAI >95.4	3.00 (2.00–5.00)	
<i>n</i> =83:83, Neighborhood analysis		
SEDI ≤100.2	3.50 (2.00–5.75)	0.297
SEDI >100.2	4.00 (3.00–6.00)	

Statistically significant results are marked in bold.

SAI, Socioeconomic Advantage Index; SEDI, Socioeconomic Disadvantage Index.

## 1673

### The Surgical Management for Thoracic and Lumbar Spinal Tuberculosis: The One-Stage Surgery Combined Anterior and Posterior Approaches in Lateral Position of the Patient

Thanh Vo

Hospital for Trauma-Orthopedics, Ho Chi Minh City, Vietnam

**Introduction:** In the surgical treatment of spinal tuberculosis, the classical Hong Kong operation with an anterior approach combined with anti-tuberculosis chemotherapy allows the healing of spinal tuberculosis. But after surgery, patients must stay in bed for 2–3 months in waiting for bone fusion, this is the disadvantage of this method. Our study is aiming to shorten the postoperative long bed rest and persuade the patients to early mobilization by adding the posterior fixation to the anterior Hong Kong technique.

**Methods:** We present the results of a series of 50 cases operated from July 8, 2003 to January, 2012 at Hospital for Trauma-Orthopedics, Ho Chi Minh City, Vietnam in realizing the one stage surgery combined anterior and posterior approaches in lateral position of the patient. The document noted as follows: mean age,  $39.9 \pm 14.4$  years (range, 18–74 years); sex: male (n=25), female (n=25); preoperative motor neuro-deficits, 37 cases paralysis (74%); Frankel C/D (27 cases, 54%), Frankel A/B (10 cases, 20%); and preoperative bladder dysfunction (36%).

**Results:** The outcomes were as follows: surgical time:  $276.7 \pm 73.3$  minutes (range, 180–530 minutes), blood loss:  $1,064.6 \pm 595.7$  mL (range, 100–3,300 mL); kyphosis: preoperative  $28.3^\circ \pm 14.2^\circ$  (range,  $6^\circ$ – $66^\circ$ ), postoperative  $12.8^\circ \pm 6.1^\circ$  (range,  $0^\circ$ – $37^\circ$ ), at last follow-up  $18.1^\circ \pm 9.9^\circ$  (range,  $0^\circ$ – $50^\circ$ ); loss of correction rate: 5.3%; motor recovery: complete motor recovery (31/37 cases, 84%), partial motor recovery (6/37 cases, 16%); bladder function recovery: complete bladder recovery (16/18 cases, 89%), none bladder recovery (2/18 cases, 11%; and mini-open transaxillary (n=1), mini-open thoracotomy (n=35), mini-FEY (n=2), mini-DIGBY (n=1), mini-open lumbotomy (n=7), mini-open thoracotomy+transaxillary (n=3), mini-open thoracotomy+lumbotomy (n=1). All cases obtained a good fusion including two cases with ruptured rods. The mean follow-up was  $53 \pm 28.6$  months (range, 17–144 months). Good results were obtained. The disadvantages were the surgical time lasted longer, and more blood loss even under control.

**Conclusions:** The combined anterior Hong Kong Operation and posterior correction-fixation allow the patient to get up early for rehabilitation (sitting, standing, and walking) in a couple of days following the operation without thoracolumbar bracing. This is an advanced step in the surgical management of thoracic and lumbar spinal tuberculosis. With only an unchanged lateral position during surgery, the author can perform the anterior Hong Kong technique for decompression and anterior support and the posterior correction-fixation by pedicle screw insertion without a C-arm check. The lateral position demonstrated three logistic points: firstly, anterior decompression; secondly, posterior correction-fixation with whole pedicle screws construct; then, anterior support insertion by cage, expander, or autograft (especially, logistic for the serious kyphotic patients). The author contributes one more method option in the surgical management for the patients involved in neuro-deficits, advanced kyphosis,

and serious instability.

## 1818

### Treatment of Chronic Spinal Cord Injury: Is There Any Hope?

Muhammad Jawad Saleem

*Orthopedic Spine Institute, Lahore, Pakistan*

**Introduction:** Here we are presenting outcome of new treatment option (adhesiolysis of cord+ arachnoidectomy+dentectomy) of chronic spinal cord injury.

**Methods:** This prospective case series was carried out using the probability consecutive sampling technique. The study was conducted at Orthopedic Spine Institute, Doctors Hospital & Medical Centre, Lahore from 1st January 2021 to 31st July 2022. A sample size of seven patients presented in our hospital with chronic spinal cord injury (American Spinal Cord Injury Association [ASIA] scale A and B) was recruited in the study and followed prospectively. Patients with sharp injuries and firearm injuries were excluded from the study. All patients had preoperative magnetic resonance imaging. All patients were operated by a single surgeon. The outcome measures were neurology and improvement in bowel and bladder control. Patients were followed up at 3 weeks, 6 weeks, 12 weeks, 6 months, and 12 months postoperative.

**Results:** The mean age was 24 years old. The mean follow-up was 6 months. There was no neurological worsening following surgery. Four patients with ASIA B improved to ASIA C. Two patients have an improvement in dysesthetic pain. One patient did not improve after surgery. The average operation time was 3 hours. Postoperatively remained flat for 72 hours. The average hospital stay was 4 days. There was no wound infection reported in the study.

**Conclusions:** It is concluded that adhesiolysis of cord+ arachnoidectomy and dentectomy is a safe option in chronic spinal cord injuries, where there is no hope in previous literature. But current data is limited and more work is required to establish this treatment option.



1823

## Paradoxical Worsening on Imaging in the Early Treatment Course of Tuberculous Spondylodiscitis: Should It Be a Concern?

J. Naresh-Babu

*Mallika Spine Centre, Kothapet, India*

**Introduction:** Pott's spine is the most common extrapulmonary presentation of tuberculosis. Currently, magnetic resonance imaging (MRI) is the gold standard imaging modality for early diagnosis and monitoring of the response to the treatment. Many a time, radiological worsening with clinical improvement of the patient poses a challenge concerning the course of the treatment. Our study intends to document the radiological changes during chemotherapy at serial intervals coupled with clinical and hematological evaluations. It also intends to identify whether there is a need to alter the course of therapy.

**Methods:** In this prospective, clinico-radiological, and observational study, serial monitoring of patients was performed from diagnosis till 12 months of chemotherapy. Radiological assessment was done with serial MRI images for various radiological parameters. Clinical assessment was performed with Measure Your Medical Outcome Profile version 2 (MYMOP 2) and erythrocyte sedimentation rate (ESR). All patients followed the standard 4 drug regime of anti-tubercular therapy.

**Results:** A total of 52 patients were included in the study; 30 were males and 22 were females. The mean MYMOP2 score at the time of diagnosis was 4.98. It was 3.18 and 0.33 by the end of 1 month and 12 months of chemotherapy, respectively. The mean ESR at diagnosis was 64.13 mm at the end of 1 hour. After 1 month of chemotherapy, it was 48.98 and decreased to 23.08 after 12 months of chemotherapy. The average number of vertebrae involved at the initial presentation was 2.52. At the end of the first month, it was 2.78 vertebral bodies. The average number of affected vertebral bodies has decreased from the 3-month follow-up, and a similar trend continued in subsequent visits. The mean percentage of vertebral body hypointensity in T1 images at diagnosis was  $74.4\pm 30.7\%$ . At the end of the first month, the mean was  $79\pm 22\%$ . The mean percentage of vertebral body hyperintensity in T2 images at the time of initial diagnosis, the mean was  $70.6\pm 21\%$ , which increased to  $73.6\pm 23.9\%$  at the end of the first

month. At the time of presentation, the average extent of pre and/or paraspinal abscess was 2.13. At the end of the first month, the average extent was 2.73. The total number of endplates involved at the initial presentation was 105 in 52 patients, out of which 60 endplates have eroded. At the end of the first month, 83 endplates were found to have been eroded. This unforeseen radiological worsening despite clinical improvement of the individual during chemotherapy is termed as "paradoxical worsening."

**Conclusions:** The individual's clinical response to the therapy takes precedence over the radiological picture regarding the line of management in the early stages of treatment. Paradoxical worsening should not be a concern; instead, it should be expected. There are only few situations necessitating surgical management.

1896

## The Role of Single-Photon Emission Computed Tomography/Computed Tomography in Analyzing the Radiographic Prevalence of Asymptomatic Degenerative Spondylosis in a Consecutive Cohort of Patients Presenting with Cancer

Atharv Patankar

*St. George's Hospital, London, United Kingdom*

**Introduction:** Degenerative spondylosis (DS) represents a challenging condition to diagnose and treat. The onset is often insidious but radiographic evidence does not necessarily equivocate to pain generators. The clinical picture could be further complicated by predisposing spine-related factors and underlying medical conditions accumulated over time. There are multiple modalities to investigate DS including X-ray, magnetic resonance imaging, and computed tomography (CT), but symptoms may not be equivocal to DS to support the clinical findings. The investigation of metastases commonly utilizes single-photon emission computed tomography (SPECT)/CT for identification of areas of increased osteoblastic activity to denote disease. It is also utilized as a second line investigation of potential pain generators in the spine. The aim of the study was to analyze the prevalence of asymptomatic DS in a consecutive hospital cohort of oncology patients who had SPECT/CT for investigation of metastases.

**Methods:** Oncology patients underwent SPECT/CT were analyzed between 2015–2019. Exclusion criteria were as follows: back pain, inflammatory disorders, metastases, trauma, and infection. Radiology reports were examined for DS and anatomical distribution of tracer uptake.

**Results:** A total of 1,182 patients had a Whole-Body SPECT/CT used for the spinal analysis. After exclusions (age >80 years [n=260], non-cancer [n=318], back pain [n=72]), 522 reports with cancer were utilized. The mean age was 65 years (range, 4–80 years). Age and distribution of DS are given in the Table 1.

**Conclusions:** The prevalence of radiological asymptomatic DS is prevalent in large proportions of patients without back pain, and its incidence increases with age. Approximately 60% of 60-year-old and 70% of 70 years old patients have asymptomatic DS in the lumbosacral region. We conclude that SPECT/CT will detect radiographic degenerative spondylosis in an asymptomatic hospital cohort and this prevalence increase with age. Therefore, this modality of imaging must be utilized with caution when investigating potential pain generators.

**Table 1.** Proportion of patients with DS by age (%)

Location of DS (%)	Age group (yr)					
	≤30 (n=0)	31–40 (n=11)	41–50 (n=39)	51–60 (n=87)	61–70 (n=178)	71–80 (n=207)
Cervical			10	29	30	33
Thoracic		27	33	61	65	64
Lumbo-sacral		9	28	62	77	76
Sacro-iliac joint		9	10	15	16	4
Whole spine			5	20	25	27

From 522 reports, 25 (5%) had adult spinal deformity: scoliosis (22, 88%), kyphosis (3, 12%). DS, degenerative spondylosis.

## Abstracts for Medal Papers E-Poster Papers

030

### Predictors of Cerebrospinal Fluid Leak Following Dural Repair in Spinal Intradural Surgery: Surgical Indications and Dural Repair Techniques

Lei Jiang

Singapore General Hospital, Singapore

**Introduction:** Surgical management of spinal intradural lesions involves the opening of the dura which requires a robust repair to prevent postoperative cerebrospinal fluid (CSF) leakage. The ideal method of dural closure and the efficacy of dural sealants has not been established in the current literature. We aim to compare the effectiveness of dural closure techniques in preventing CSF leaks following surgery for intradural lesions and seek to identify additional factors associated with CSF.

**Methods:** We performed a retrospective analysis of all intradural spinal cases performed at a tertiary spine center from 1 April 2015 to 29 January 2020 and collected data on patient bio-profile, dural repair technique, and CSF leak rates. Multivariate analysis was performed to identify predictors for postoperative CSF leak.

**Results:** A total of 169 cases were reported during the study period. There were 15 cases in which postoperative CSF leak was reported (8.87%). Multivariate analysis demonstrated patient age (odds ratio [OR], 0.942; 95% CI, 0.891–0.996), surgical indication listed in the “others” category (OR, 44.608; 95% CI, 1.706–166.290), and dural closure with suture, sealant, and patch (OR, 22.235; 95% CI, 2.578–191.798). Postoperative CSF leak was associated with the risk of surgical site infection with a likelihood ratio of 8.704 ( $\chi^2 [1]=14.633, p<0.001$ ).

**Conclusions:** To our knowledge, this is the first study examining predictors of CSF leak following surgery for intradural pathologies. Identifying predictors for CSF leaks can assist in the counseling of patients with regard to surgical risk and expected postoperative recovery.

178

## Factors Affecting the Prognosis of Recovery of Motor Power and Ambulatory Function after Surgery for Metastatic Epidural Spinal Cord Compression

Sehan Park

Department of Orthopaedic Surgery, Dongguk University Ilsan Hospital, Goyang, South Korea

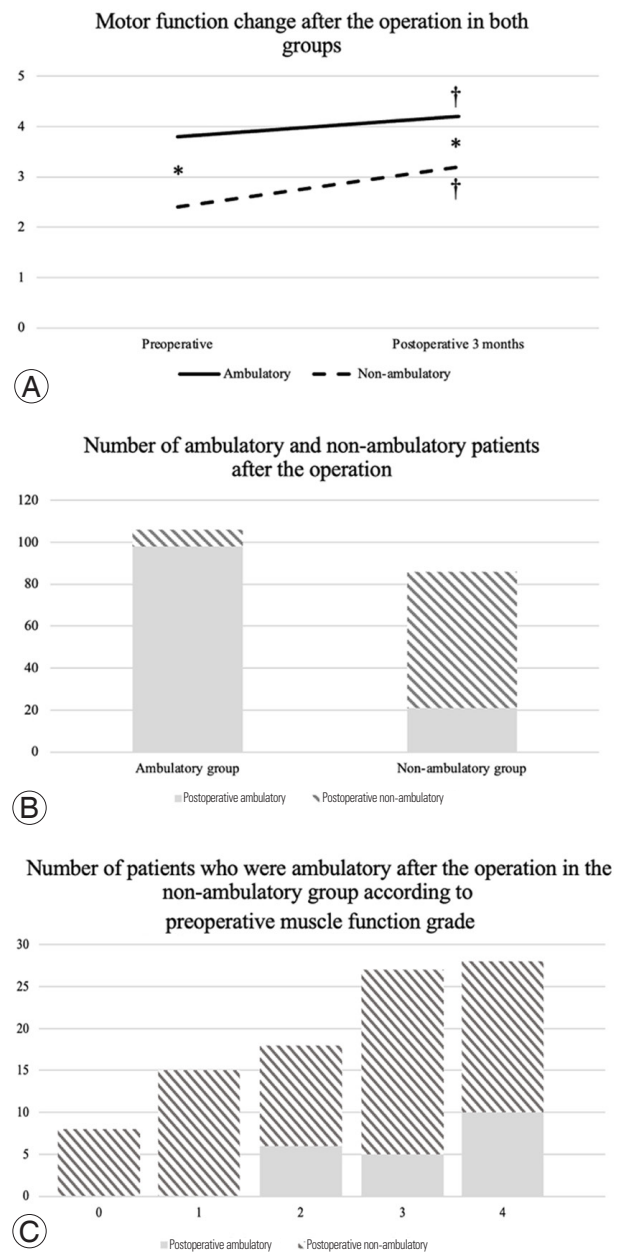
**Introduction:** Metastatic epidural spinal cord compression (MESCC) causes neurological deficits that could hinder ambulation. Understanding the prognostic factors associated with the better neurological recovery and regain of ambulatory functions would be important for surgical planning in MESCC patients with neurological deficits. The present study was conducted to elucidate prognostic factors of neurological recovery in MESCC patients.

**Methods:** A total of 192 patients who had surgery for MESCC due to preoperative neurologic deficit were reviewed. A motor recovery rate  $\geq 50\%$  and regain of ambulatory functions were defined as the primary favorable endpoints. Factors associated with a motor recovery rate  $\geq 50\%$ , regain of ambulatory function, and patient survival were analyzed.

**Results:** About half (48.4%) of the patients had a motor recovery rate  $\geq 50\%$  (Fig. 1A). The factors “involvement of the thoracic spine” ( $p=0.015$ ) and “delayed operation” ( $p=0.041$ ) were associated with poor neurological recovery. And 24.4% of patients who were not able to walk due to MESCC before the surgery were able to walk after the operation (Fig. 1B). A low preoperative muscle function grade was associated with a low likelihood of regaining ambulatory functions ( $p=0.002$ ) (Fig. 1C). Furthermore, performing the operation  $\geq 72$  hours after the onset of the neurological deficit significantly decreased the chance of regaining ambulatory functions ( $p=0.020$ ). Postoperative ambulatory function significantly improved patient survival ( $p=0.048$ ) (Fig. 2).

**Conclusions:** Delayed operation and the involvement of the thoracic spine were poor prognostic factors for neurological recovery after MESCC surgery. Furthermore, a more severe preoperative neurologic deficit was associated with a lesser likelihood of regaining ambulatory functions postoperatively. Earlier detection of motor weaknesses and expeditious surgical interventions are necessary, not

only to improve patient functional status and quality of life but also to enhance their survival.



**Fig. 1.** (A) Motor function change after the operation in both groups. (B) Number of ambulatory and non-ambulatory patients after the operation. (C) Number of patients who were ambulatory after the operation in the non-ambulatory group according to preoperative muscle function grade.

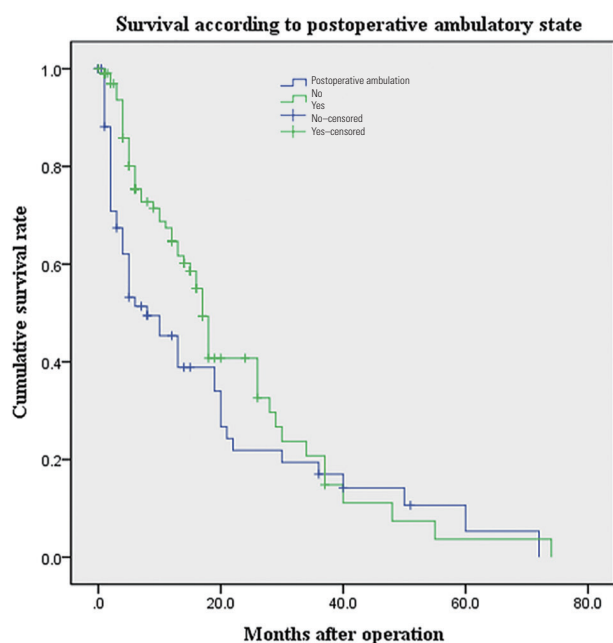


Fig. 2. Survival according to postoperative ambulatory state.

## 256

### A Comparative Factor Analysis of Spinal infection in Adults: Pyogenic versus Tuberculous Spondylodiscitis

Patchara Pornsopanakorn

Maharat Naorn Ratchasima Hospital, Nakhon Ratchasima, Thailand

**Introduction:** The differential diagnosis between pyogenic and tuberculous spondylodiscitis is crucial. Accurate diagnosis and early treatment are important to prevent the further progression of the disease and decrease patient morbidity.

**Purpose:** This study aims to compare and analyze the difference in clinical and magnetic resonance imaging findings between pyogenic spondylodiscitis (PyS) and tuberculous spondylodiscitis (TS)

**Methods:** We compared the predisposing factors of 190 patients (67 PyS patients and 123 TS patients) whose confirmed diagnosis by laboratory, culture, or pathology. The demographics, clinical characteristics, laboratory results, and radiographic findings of the patients were collected between 2015 and 2020. The data were analyzed using logistic regression methods. The predictive factors for differentiating PyS vs. TS were identified.

**Results:** The relevant factors for TS vs. PyS group, as

identified by univariate analysis, were female (odds ratio [OR], 2.83; 95% confidence interval [CI], 1.50–5.36), the duration of symptoms >4 weeks (OR, 12.15; 95% CI, 4.93–29.94), white blood cell count >10,000 (OR, 0.21; 95% CI, 0.11–0.40), percentage of neutrophil >75% (OR, 0.35; 95% CI, 0.19–0.65), alkaline phosphatase level (OR, 0.31; 95% CI, 0.17–0.58), lesion at thoracic level (OR, 11.00; 95% CI, 3.77–32.14), vertebral destruction more than 50% (OR, 6.36; 95% CI, 3.14–12.86), heterogenous vertebral enhancement (OR, 19.21; 95% CI, 3.91–94.26), intraosseous abscess (OR, 28.06; 95% CI, 10.45–75.37), well-defined paravertebral soft tissue extension (OR, 84.75; 95% CI, 8.75–820.88), ill-defined paravertebral soft tissue extension (OR, 0.22; 95% CI, 0.03–1.49), epidural abscess (OR, 2.75; 95% CI, 1.49–5.08), epidural phlegmon (OR, 0.01; 95% CI, 0.004–0.033), facet joint arthritis (OR, 0.20; 95% CI, 0.10–0.41), and anterior longitudinal ligament (ALL) spreading (OR, 23.28; 95% CI, 9.43–57.49). However, the multivariate analysis demonstrated that only facet joint arthritis (OR, 0.19; 95% CI, 0.02–1.28), intraosseous abscess (OR, 18.20; 95% CI, 2.24–147.26), well-defined paravertebral soft tissue extension (OR, 12.67; 95% CI, 1.77–90.55), ALL spreading (OR, 72.47; 95% CI, 6.88–763.93), epidural phlegmon (OR, 0.0037; 95% CI, 0.003–0.042), and thoracic lesion (OR, 116.87; 95% CI, 4.33–3155.81) significantly influenced the differential diagnosis between TS vs. PyS group.

**Conclusions:** Our study showed the strongly predictive factors for differentiating spinal TB from pyogenic spinal infection were facet joint arthritis, intraosseous abscess, well-defined paravertebral soft tissue extension, ALL spreading, epidural phlegmon, and thoracic lesion. Thus, these clinico-radiological findings were helpful to guide the appropriate treatment when the causative organism is not identified.

## 652

### Antiplatelet Therapy Does Not Prolong Length of Stay Following Anterior Cervical Discectomy and Fusion

Beatrice Tan

Changi General Hospital, Singapore

**Introduction:** Anterior cervical discectomy and fusion (ACDF) is a commonly performed procedure that gener-

ally does not require a prolonged inpatient stay. The development and implementation of an enhanced recovery after surgery (ERAS) protocol aims to streamline patients' pre- and postoperative management to even further reduce the length of inpatient stay required. We aim to determine if pre-existing use of antiplatelets, with its risk implications with regard to patient co-morbidities and peri- or postoperative bleeding, results in longer inpatient admissions, and may therefore exclude patients from being safely included in an ERAS protocol.

**Methods:** Preliminary data from 71 patients who had undergone ACDF procedures at a single institution from January 2020 to December 2021 were analyzed for pre-existing anticoagulation use, and length of inpatient stay. Patients who underwent ACDF following polytrauma and required surgery for other injuries were excluded. A Mann-Whitney U test was performed to determine if there were any significant differences in the length of inpatient stay between patients who were on pre-existing anticoagulation therapy compared to those who were not. Results were deemed to be significantly different if the *p*-value was less than 0.05.

**Results:** A total of 69 patients were included in the final analysis, of which 11 patients were on pre-existing antiplatelet therapy, and 58 were not. All patients on antiplatelets were on single-agent therapy, which had been suspended prior to surgery. The mean length of inpatient stay across the study population was 5.62 days whereas the median length of stay was 3 days. The mean length of inpatient stay for patients who were not on antiplatelet therapy was 4.97 days, compared to 9.09 days for patients on antiplatelet therapy. The median length of stay for both groups was 3 days. There was no significant difference in the length of inpatient stay between the two groups (*p*-value=0.267; >0.05).

**Conclusions:** Preliminary data suggest that pre-existing antiplatelet therapy does not adversely affect the length of inpatient stay in patients undergoing ACDF if medications have been adequately suspended prior to surgery. Patients on pre-existing antiplatelet therapy may be suitable for enrolment in ERAS protocols for ACDF procedures. However, a limitation of this study is the small number of patients with very prolonged admissions skewing the analyzed mean values. Further research with a larger population size would be recommended. This study may also be extended to determine if other anticoagulation modalities, such as warfarin or direct oral anticoagulants, or dual

antiplatelet therapy result in any difference in length of inpatient stay following ACDF.

719

## Morphological Evaluation of the Lumbar Curve in Adolescent Idiopathic Scoliosis Lenke Type 1

Yuichi Shimizu

*Kyoto Prefectural University of Medicine, Kyoto, Japan*

**Introduction:** The morphology of adolescent idiopathic scoliosis (AIS) has been evaluated in various ways using medical imaging. It has become possible to output three-dimensional (3D) polygonal models of individual vertebrae directly from computed tomography (CT) scanners, making it relatively easy to perform detailed 3D analyses of spinal curves. However, morphological differences according to Lenke classification and morphological evaluation of each thoracolumbar spine region are unknown. Therefore, the purpose of this study was to quantitatively evaluate and characterize the morphology of the lumbar spine curve of AIS Lenke type 1 by morphological evaluation using a 3D polygonal model of the lumbar spine in patients with AIS and without scoliosis.

**Methods:** A total of 18 patients who had developed idiopathic scoliosis and underwent a preoperative CT scan were included in this study. There were six cases of AIS Lenke classification type 1A-L, six type 1B, and six type 1C. In addition, six patients without scoliosis with CT scans performed for non-spinal diseases were assessed as controls. We output the 3D polygon model from CT scanners in each case. The translations (X-t, Y-t, and Z-t) and rotation angles (X-r, Y-r, and Z-r) of each vertebra (L1–5) in the coronal, sagittal, and vertical axes were measured based on the centroid of each vertebra and compared between AIS and control cases. The N group consisted of non-scoliosis cases, and the S group consisted of scoliosis cases. The correlations between each parameter in the AIS cases were investigated. We also compared the amount of translation and rotation angle for each lumbar modifier in AIS cases. Group A consisted of type 1A-L, group B consisted of type 1B, and group C consisted of type 1C.

**Results:** Comparisons of N and S groups showed kyphosis and right deviation at L1/2; right lateral flexion and left vertebral rotation at L2/3; right lateral flexion, left rota-

tion, and left deviation at L3/4; and left rotation and right deviation at L4/5 in S group (Fig. 1). Strong positive correlations X-t and Z-r were observed in S group (Fig. 2). Groups B and C showed more significant deviation than that in group A at L3/4 and 4/5 in X-t.

**Conclusions:** The lumbar AIS curve is characterized by a maximum lateral wedging angle, a small vertebral rotation angle near the apical vertebra, and a maximum rotation angle at the end vertebra. In addition, there was a lateral shift to the contralateral side of the rotation direction and a shortening to the craniocaudal side. These were considered to represent the characteristics of the lumbar spine in AIS Lenke type 1. A strong correlation between Z-r and X-t was observed. We considered that the lateral deviation of the vertebral body may predict the angle of rotation. The lateral deviation at L3/4 and L4/5 may be one of the factors that define the lumbar modifier in AIS Lenke type 1. The 3D polygonal model enabled a detailed 3D quantitative evaluation and clarified the morphological characteristics of the lumbar spine curve of Lenke type 1.

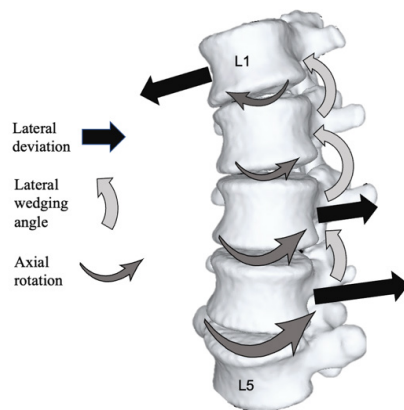


Fig. 1. Qualitative sketch of the variation of translation and rotation among each lumbar vertebra in adolescent idiopathic scoliosis Lenke type 1.

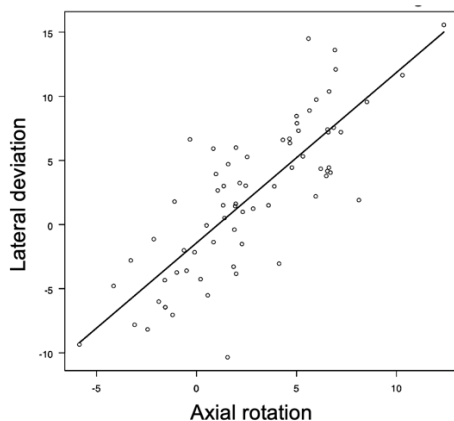


Fig. 2. A correlation between axial rotation and sagittal translation.

## 801

### Can Thoracic Inlet Angle Be Used as a Substitute for T1 Slope?

Kenta Takakura

Department of Orthopaedics, Graduate School of Medicine, Gunma University, Maebashi, Japan

**Introduction:** T1 slope is an important radiographic parameter of sagittal spinal balance for surgical planning. However, the T1 superior endplate can be difficult to visualize on radiographs due to overlying anatomical structures. Furthermore, some patients with severe cervical myelopathy are unable to keep in a standing position during radiographic examination. Therefore, we focused on the thoracic inlet angle (TIA), which shows a constant value regardless of posture and can be evaluated by magnetic resonance imaging (MRI) on a supine position. This study aimed to investigate the usefulness of preoperative TIA for predicting the development of kyphotic deformity after cervical laminoplasty.

**Methods:** The authors retrospectively extracted data for patients with cervical myelopathy who underwent cervical laminoplasty with a minimum 2-year follow-up. Patients were divided into two groups according to the occurrence of postoperative cervical kyphosis. The T1S was measured on a standing radiograph. The TIA is defined as the angle formed by a line from the center of the T1 upper endplate vertical to the T1 upper endplate and a line connecting the center of the T1 upper endplate and the upper end of the sternum. The TIA was evaluated by MRI in a supine position. We examined the correlation analysis between the preoperative T1S and TIA, and a receiver operating characteristic curve analysis was performed to compare predicting ability of the postoperative cervical kyphosis.

**Results:** A total of 98 patients were enrolled (mean age, 73.7 years; 41.8% female). Postoperative kyphosis occurred in 11 patients (11.2%). In the kyphosis group, both preoperative T1S and TIA were smaller compared with the non-kyphosis group (T1S:  $23.5^\circ \pm 14.5^\circ$  vs.  $30.3^\circ \pm 9.1^\circ$ ,  $p=0.03$ ; TIA:  $76.1^\circ \pm 10.2^\circ$  vs.  $81.8^\circ \pm 8.3^\circ$ ,  $p=0.04$ ). There was a positive correlation between the preoperative T1S and TIA (correlation coefficient:  $r=0.43$ ,  $p<0.001$ ). The optimal cutoff value for predicting postoperative kyphosis was T1S  $<26^\circ$  (sensitivity, 73%; specificity, 69%; area under the curve [AUC], 0.70; 95% confidence interval

[CI], 0.49–0.91) and TIA  $<83^\circ$  (sensitivity, 82%; specificity, 48%; AUC, 0.68; 95% CI, 0.49–0.86), respectively. The preoperative TIA showed similar accuracy and reliability as a predictor of postoperative kyphosis compared with the preoperative T1S (DeLong test:  $p>0.05$ )

**Conclusions:** The preoperative TIA was positively correlated with the preoperative T1S and can be used as a substitute to estimate the T1S when the superior endplate of T1 is not well visualized, or patients are unable to keep in a standing position due to severe myelopathy.

827

## An Analysis of 49 Cases with Pedicle Fractures of the C2 Axis: Is Surgery Necessary?

Sung Kyu Kim

*Department of Orthopaedic Surgery, Chonnam National University Medical School and Hospital, Gwangju, South Korea*

**Introduction:** Spine surgeons often confuse C2 pedicle fractures (PFs) with pars interarticularis fractures. In addition, little information is available about the characteristics and treatment strategies for C2 PFs. We sought to investigate the characteristics of C2 PFs and to propose an appropriate treatment strategy.

**Methods:** A total of 49 patients with C2 PFs were included in this study. We divided these patients into unilateral and bilateral C2 PF groups. The incidence rates and characteristics of other associated C2 and C2–3 injuries, and other cervical injuries, were evaluated. In addition, treatment methods and outcomes were analyzed.

**Results:** Twenty-two patients had unilateral C2 PFs and 27 patients had bilateral C2 PFs. Among the cases of unilateral C2 PFs, all patients had one or more other C2 fractures, and 20 patients (90.9%) had one or two C2 body fractures. Meanwhile, among the cases of bilateral C2 PF, all patients had two or more other C2 fractures and one or two C2 body fractures. In unilateral C2 PFs, three patients with C2–3 anterior slip or adjacent cervical spine (C1–3) injury underwent surgery and 19 patients (86.4%) were treated with conservative methods. In bilateral C2 PFs, three patients with C2–3 anterior slip or SCI at C2–3 underwent surgery and 24 patients (88.9%) were treated with conservative methods.

**Conclusions:** Our results showed that C2 PFs do not occur alone and are always accompanied by other associated

C2 injuries. C2 PFs should, generally, be thought of as a more complex fracture type than hangman's fracture or dens fracture. Despite the complex fracture characteristics, most C2 PFs can be managed with conservative treatment. However, surgical treatments should be considered if the C2 PFs are accompanied by the C2–3 anterior slip and adjacent cervical spine injury.

1112

## Comparative Analysis between Supine Manual Traction Radiographs with Bending Radiographs in Adolescent Idiopathic Scoliosis

Subramaniam Macherla Haribabu

*Chettinad Hospital and Research Institute, Kelambakkam, India*

**Introduction:** Radiographic assessment of curve flexibility in the preoperative process is a key part of surgical planning in adolescent idiopathic scoliosis (AIS) patients. Evaluation of the radiographic flexibility index of the scoliotic curve aids in assessing the structural change of curve and the rigidity of curve; it helps in determining the surgical technique whether only a posterior approach or combined anterior and posterior will be required and the amount of correction that is safely possible.

**Purpose:** The aim of the study is to compare traction radiographs with bending radiographs in AIS patients. Controversy exists in the literature between traction radiographs and supine bending radiographs on which spinal deformity surgeons can rely to determine the flexibility of the scoliotic curve.

**Methods:** Supine manual traction anteroposterior radiograph is taken with the patient in the supine position, with traction applied by a person with the head halter at the chin and counter traction applied with the pelvic belt, leg straps, and supine bending radiographs are taken with the patient asked to bend as much as possible on the right and left and whole spine anteroposterior radiograph is taken extending from the mastoid process up to lesser trochanter of the femur. AIS patients who underwent surgery during 2016 to 2020 period were retrospectively analyzed. Patients were divided into three groups A, B, and C based on the Cobb angle of the major structural curve. Patients with Cobb angles between  $40^\circ$  to  $65^\circ$ ,  $65^\circ$  to  $90^\circ$ , and more than  $90^\circ$  were included in groups A, B, and C, respec-

tively. Flexibility indices obtained from both traction and bending radiographs were correlated with percent change in Cobb angle post-surgery correction. Statistical analysis was done and results were tabulated.

**Results:** There were 36, 16, and 16 patients in groups A, B, and C, respectively. The mean age of the patients was 13.3 years. The mean reduction in Cobb angle following surgery was 31.6° and 30.8° with bending and supine traction radiographs when compared to preoperative anteroposterior radiographs. The mean flexibility index obtained was 38% with supine side-bending radiographs and 37.1% with traction radiographs. The mean postoperative correction percentage in our series was 70% (range, 65% to 77%). The additional correction of 33% is attributed to the general anesthesia relaxant effect coupled with powerful correction provided by the three-column fixation of the pedicle screw construct. In group A, there was a negative correlation to bending radiographs ( $r=-0.072$ ) and a positive correlation to traction radiographs with post-surgery correction percentage ( $r=0.188$ ). In group B, there was a statistically significant, positive correlation with bending radiographs ( $r=0.729$ ,  $p=0.04$ ) and a negative correlation with traction radiographs ( $r=-0.166$ ). In group C, a statistically significant positive correlation was seen between traction radiographs to post-surgery correction percentage ( $r=0.769$ ,  $p=0.01$ ).

**Conclusions:** Supine manual traction radiographs reveal a better flexibility index than bending radiographs in severe stiff curves (Cobb angle, more than 90°) and in minimally stiffer curves (Cobb angle, 40° to 65°). In moderately stiffer curves (Cobb angle, 65° to 90°), supine bending radiographs provide a better flexibility index than traction radiographs. Supine manual traction radiographs should always accompany bending radiographs in evaluating AIS patients, especially with severe stiff curves.

**1182**

## Comparative Study of Anterior and Posterior Combined Surgery with Lateral Lumbar Interbody Fusion versus Vertebral Body Replacement for Osteoporotic Vertebral Burst Fractures

Kazuo Doi

*Dokkyo Medical University, Mibu, Japan*

**Introduction:** Spinal column instability and aggravation of local kyphosis are often observed in patients with osteoporotic vertebral burst fractures (OVBF), and surgical treatment is recommended for patients with severe low back pain and/or neurological complications. Because of aged patients' numerous comorbid medical complications and frequent instrumentation failure secondary to osteoporosis, the optimal treatment of OVBF has been controversial. The purpose of this study is to compare the surgical results of lateral lumbar interbody fusion (LIF) and vertebral body replacement (VBR) in reconstructive surgery for OVBF.

**Methods:** In this retrospective study, a total of 16 patients (five males, 11 females; mean age at surgery, 71.3 years) with OVBF who underwent anterior and posterior combined surgery and received follow-up for a mean of 26.8 months were enrolled. Eight patients underwent LIF, and eight patients underwent VBR as anterior column reconstruction. The clinical records were reviewed for operation time, intraoperative blood loss, complications, and radiological and neurological improvements. The neurological status using the modified Frankel Grade system was assessed. Postoperative fusion was evaluated using computed tomography reconstruction scans.

**Results:** No significant difference between the two groups (LIF/VBR) was observed in the number of fused intervertebral levels (2.5/3.3), operative time (247/280 minutes), and intraoperative blood loss (336/570 mL). No significant difference was observed in neurological improvement or the angle of kyphosis correction (10.4°/12.5°). However, the loss of correction (3.6/6.3) and cage subsidence (3.4/6.9 mm) was significantly greater in the VBR group. There were no significant differences in perioperative complications, but two patients in the VBR group underwent additional surgery for cage dislodgement. Pseudarthrosis was noted in one patient in both groups (12.5% nonunion rate).



**Conclusions:** In terms of surgical duration and blood loss, no significant difference was observed between LIF and VBR as anterior column reconstruction procedures. Neurological recovery and perioperative complications rates were also almost the same with both procedures. On the contrary, postoperative complications such as cage dislodgement and severe local kyphosis progression were more often observed in VBR. In the LIF procedure, snug-fit insertion of the cage into the interbody space reconstructs anterior support by establishing bone-cage-bone continuity, and the use of a wide interbody cage spanning the lateral borders of the apophyseal ring minimizes the risk of cage subsidence. Anterior and posterior combined surgery with LIF procedure may be one of the effectual treatment options for OVBF.

1733

## Single-Level Endoscopic Transforaminal Lumbar Interbody Fusion Achieves Similar 1-Year Clinical and Radiological Outcomes Compared to Conventional Minimally Invasive Transforaminal Lumbar Interbody Fusion with Reduced Surgery Duration, Blood Loss, and Length of Hospital Stay

David Shaoen Sim

Singapore General Hospital, Singapore

**Introduction:** Endoscopic minimally invasive transforaminal lumbar interbody fusion (E-TLIF) is a novel technique with smaller skin incisions and decreased soft tissue disruption compared to conventional minimally invasive transforaminal lumbar interbody fusion (MIS-TLIF). E-TLIF in this study was performed via a uniportal transforaminal approach under general anesthesia and neuromonitoring with the use of an expandable titanium interbody cage. This study presents a single surgeon experience comparing 1-year outcomes of E-TLIF versus MIS-TLIF in an Asian population.

**Methods:** A retrospective review was conducted on all consecutive patients who underwent single-level E-TLIF or MIS-TLIF by a single surgeon in a tertiary spine institution from 2018 to 2021 with 1-year follow-up. Inclusion criteria for both procedures were degenerative disc disease with grade I or II spondylolisthesis and mild to moderate central canal stenosis. The choice of technique was depen-

dent on the availability of endoscopic technology in later years, surgeon, and patient preference. Both techniques were compared based on clinical outcomes including length of stay, blood loss, and surgery duration. Patient-reported outcomes between both groups were assessed including Visual Analog Scale (VAS) score for back pain and lower limb pain, Oswestry Disability Index (ODI), and North American Spine Society (NASS) Neurogenic Symptom Score (NSS). Radiological parameters were also evaluated including segmental lordosis, posterior disc height, and amount of listhesis.

**Results:** Thirteen E-TLIF and 34 MIS-TLIF patients were included. Both groups were similar in age, body mass index, gender, and levels at which surgery was performed. E-TLIF had shorter surgery duration ( $167 \pm 17$  minutes vs.  $259 \pm 43$  minutes for E-TLIF and MIS-TLIF group, respectively;  $p < 0.001$ ), reduced blood loss ( $81 \pm 72$  mL vs.  $181 \pm 225$  mL,  $p = 0.033$ ), and decreased length of stay ( $1.8 \pm 0.9$  days vs.  $4.7 \pm 2.9$  days,  $p < 0.001$ ) compared to MIS-TLIF. Both E-TLIF and MIS-TLIF patients had significant improvements in all patient report outcomes scores assessed comprising of VAS score for back pain, VAS score for lower limb pain, ODI, and NSS. Both E-TLIF and MIS-TLIF patients also had significant improvements in the radiographic parameters assessed comprising of segmental lordosis, posterior disc height, and amount of listhesis. Between the E-TLIF and MIS-TLIF groups, there was no significant difference in postoperative VAS score for back pain ( $0.5 \pm 1.5$  vs.  $0.7 \pm 1.8$ ,  $p = 0.700$ ), VAS score for lower limb pain ( $0.8 \pm 1.9$  vs.  $0.3 \pm 1.1$ ,  $p = 0.379$ ), ODI ( $19.2 \pm 9.5$  vs.  $15.9 \pm 13.1$ ,  $p = 0.344$ ), and NSS ( $11.1 \pm 16.9$  vs.  $14.6 \pm 16.4$ ,  $p = 0.542$ ). There was no significant difference in the change in segmental lordosis ( $3.2 \pm 1.7$  vs.  $2.1 \pm 2.7$ ,  $p = 0.126$ ), posterior disc height ( $3.2 \pm 1.7$  vs.  $2.1 \pm 2.7$ ,  $p = 0.126$ ), and listhesis ( $-4.5 \pm 2.7$  vs.  $-2.9 \pm 2.3$ ,  $p = 0.080$ ) between the E-TLIF and MIS-TLIF groups. No complications were recorded for E-TLIF while MIS-TLIF had a case of dura tear and another case of Meralgia paresthetica. There was no cage subsidence or implant loosening for both groups.

**Conclusions:** E-TLIF can achieve similar excellent clinical and radiological outcomes compared to MIS-TLIF while reducing surgery duration, blood loss, and length of hospital stay. This novel technique offers a safe, effective, and less invasive alternative approach to lumbar fusion.

## Abstracts for E-Posters

154

### Extensive Thoracic and Lumbar Spine Actinomycosis in an Immunocompetent Patient Causing Paraparesis: A Case Report

Sagar Kishor Kokate

*Topiwala National Medical College and Bai Yamunabai Laxman Nair Charitable Hospital, Mumbai, India*

**Introduction:** Actinomyces, a Gram-positive commensal bacterium, is extremely rare in immunocompetent individuals. Spinal cord compression with the neurological deficit is rarer still. We report a case with extensive actinomycosis of the thoracic and lumbar spine presenting with paraparesis. We have reviewed the literature on this rare infection.

**Case Report:** We present a case of a 35-year-old female with bilateral lower limb weakness with difficulty in walking since 4 months with multiple discharging sinuses and swelling from the back. The patient first noticed swelling in the back with discharge 10 years back for which incision and drainage (I&D) were done. Later another I&D were done 7 years later for similar complaints. After this intervention, the patient still had similar complaints and was referred to a tertiary care hospital. Culture from discharging sinus came positive for actinomycetoma. Amoxicillin, doxycycline, septran, and ceftriaxone were tried without success. Because the patient developed bilateral weakness in lower limbs, T3–T9 laminectomy with decompression was done and the intraoperative specimen was sent for routine cultures and histopathology. Actinomyces colonies were identified in culture and histopathological examination showed filamentous bacteria typical of this organism. Postoperatively, the patient was given three cycles of injection amikacin and oral Cotrimoxazole and Rifampicin for 3 months (modified Welsh regimen). Postoperatively, the surgical wound healed well. Sinuses healed after 3 months. The patient's bilateral lower-extremity motor strength improved slowly over 1 year and at the final follow-up is walking unsupported normally. The patient continues to be on chronic suppressive antibiotics (augmentin and rifampicin) for the last 1 year.

**Conclusions:** Spinal actinomycosis with diffuse involve-

ment of the thoracic and lumbar spine is extremely rare in an immunocompetent patient. We present treatment for one such patient who has been successfully treated for neurological deficit and is on chronic suppressive antibiotics for this indolent infection.

168

### Etiologies of Early Reoperation after Unilateral Biptoral Endoscopic Spine Surgery

Hanjin Jang

*Department of Orthopaedic Surgery, Seran General Hospital, Seoul, South Korea*

**Purpose:** The purpose of this study was to compare the causes and characteristics of reoperations after unilateral biportal endoscopy.

**Methods:** Out of a series of 740 patients who underwent operations for spinal stenosis, herniated disc, and foraminal stenosis between 2015 and 2016, 61 patients (39 males and 22 females; mean age, 69.3 years) underwent primary and revision operations, which were included in this study. The following clinical parameters were retrospectively assessed: the primary surgical methods, the intervals between primary and revision operations, and surgical findings in the revisions.

**Results:** In total, 61 patients underwent reoperations by three neurosurgeons. (All surgeon was young and had below 2 years' career in biportal endoscopic spine surgery [BESS].) The reoperation rate was 8.6%. All reoperations were performed after BESS; 36 patients were single level and 25 patients were multiple levels. And 59 cases of reoperations were performed within 0.5 years after primary surgery, and two were performed within 1 year. Real recurrent herniation was 24 cases. Postoperative hematoma was 14. Minimally invasive spine surgery (MISS) diagnosis of the symptomatic level was 8; remained disc was 4. MISS level was 3. Adhesive arachnoiditis was 3. Another level recurrent disc was 2. Incomplete decompression, epidural abscess, and dura repair was each 1. All revision was carried by BESS excepted two cases (epidural abscess and dura repair). Serious complication was one infected case and others were minor curative complications.

**Conclusions:** BESS has a broad indication of spinal disease and relatively safe method. The reoperation rate was higher than common open surgery. But all surgeon was a

beginner at BESS and almost the complication was minor. Real recurrent herniation was the most common cause of reoperations, and more reoperations for real recurrent herniations and shorter intervals were found after minimally invasive endoscopic discectomy than after open disc surgery.

253

## Association Factor for Surgical Site Infection in Spine Instrumentation Surgery

Shinji Tanishima

*Division of Orthopaedic Surgery, Department of Sensory and Motor Organs, School of Medicine, Faculty of Medicine, Tottori University, Tottori, Japan*

**Introduction:** Surgical site infection (SSI) is a serious complication in spine instrumentation surgery that not only delays underlying disease treatment but also leads to permanent disability and sometimes death. SSI is difficult to treat once it occurs, requiring multiple surgeries and instrumentation removal. Therefore, risk factor examination is important in preventing SSIs. This study aimed to examine the spinal instrumentation surgery risk factors.

**Methods:** Between 2015 and 2021, 526 patients (279 males, 247 females) with a mean age of  $68.8 \pm 14.3$  years (range, 18–92 years) who underwent spinal instrumentation surgery and could be followed up for at least 30 days at our hospital were included. Infectious spondylitis and cases of simultaneous multiple high-level surgeries were excluded. Age, gender, concurrent malignant disease, diabetes, skin disease, hemodialysis, smoking, steroid use, body mass index, immunosuppressive drug use, preoperative albumin level, total protein American Society of Anesthesiologists classification, and detection of pathogens in preoperative nasal cultures were included as patient factors. Surgery-related factors included repeat surgery at the same site, presence of emergency surgery, prophylactic vancomycin application, surgery duration, and blood loss. Univariate analysis was performed for statistical analysis, and logistic analysis was performed for factors with an associated trend ( $p < 0.2$ ). The significance level was set at  $p < 0.05$ .

**Results:** About 14/526 patients (2.7%) were infected; 12 cases with deep infection and two cases with superficial infection. The organism of origin was identified in 11

cases and unknown in three cases. Univariate analysis showed gender (female %) (noninfected vs. infected group: 47.4% vs. 28.6%), concurrent malignant disease (noninfected vs. infected group: 14.4% vs. 35.7%), preoperative C-reactive protein (CRP) level (noninfected vs. infected group:  $0.72 \pm 1.74$  mg/dL vs.  $2.34 \pm 4.33$  mg/dL), immunosuppressive drug use (noninfected vs. infected group: 5.1% vs. 14.3%), same high-level revision surgery (noninfected vs. infected group: 8.2% vs. 28.6%), emergency surgery (noninfected vs. infected group: 27.7% vs. 50%), and vancomycin use (noninfected vs. infected group: 6.7% vs. 21.4%) were associated. Logistic analysis showed that the same high reoperation (odds ratio [OR], 6.6; 95% confidence interval [CI], 1.74–24.9;  $p = 0.006$ ) and CRP level (OR, 1.2; 95% CI, 1.19–1.42;  $p = 0.048$ ) were associated.

**Conclusions:** Poor soft tissue condition and high CRP levels may be due to overlooked concurrent infection or decreased immunity due to other inflammatory diseases that may be associated with reoperated patients. Therefore, stricter infection control measures are needed.

268

## Long-term Outcome of Surgery for Ossification of the Posterior Longitudinal Ligament

Yoshiharu Kawaguchi

*Department of Orthopaedic Surgery, University of Toyama, Toyama, Japan*

Posterior decompression surgery is usually indicated in patients with cervical myelopathy due to ossification of the posterior longitudinal ligament (OPLL), as OPLL frequently brings multi-level spinal cord compression. We have reported more than 20 years of follow-up after *en-bloc* laminoplasty for patients with OPLL. The overall surgical outcome was satisfactory in most of the cases; however, we encountered several patients who developed postoperative neurological deterioration during the follow-up period. One of the causes of neurological deterioration in the long-term follow-up was newly developed spinal cord compression by the progression of OPLL. Five percent of the patients required an additional second surgery due to OPLL progression. Mixed and continuous types of OPLL have a risk of OPLL progression. In our

research, several biomarkers, such as hypersensitive C-reactive protein and periostin, were related to the progression of OPLL. Thus, inflammation as well as bony activity might cause the progression. Recent papers reported the possibility to reduce OPLL progression by fusion surgery instead of laminoplasty. Postoperative radiculopathy, including C5 palsy, is another issue. It has been reported that 5% of the patients have postoperative radiculopathy. We have a patient with severe arm pain after *en-bloc* laminoplasty. She had severe neuropathic pain for more than 20 years. In my presentation, I will talk about the long-term outcome of posterior decompression for OPLL based on our experience and raise some issues after surgery.

271

## Comparison of Percutaneous Endoscopic Surgery to Treat Infectious Spondylodiscitis with or without Spinal Epidural Abscess: A Retrospective Study and Literature Reviews

Chiayu Lin

Department of Orthopaedic Surgery, China Medical University Hospital, China Medical University, Taichung, Taiwan, Republic of China

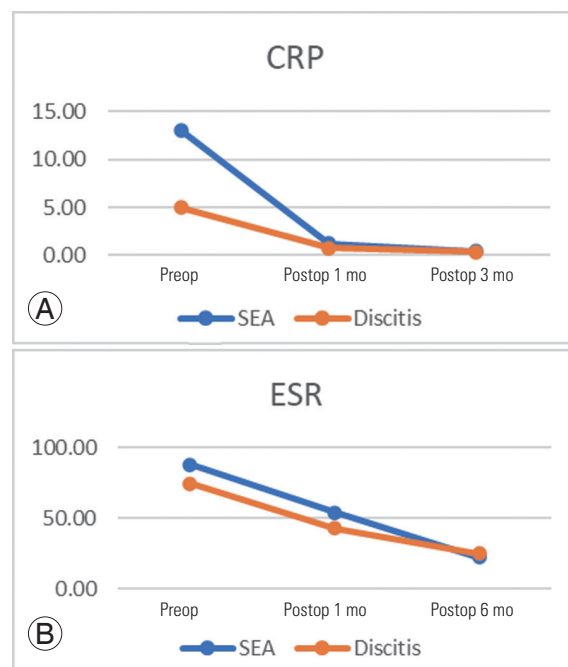
**Introduction:** Percutaneous endoscopic surgery is proven to be less invasive but as effective as traditional open surgery in treating infectious spondylodiscitis. However, the spinal epidural abscess is an uncommon clinical condition that may progress to potentially irreversible paralysis and to life-threatening sepsis. In this study, we compared the mid-term clinical outcome of treating spinal epidural abscess and infectious spondylodiscitis with percutaneous endoscopic surgery.

**Methods:** From January 2010 to September 2017, 60 patients received percutaneous endoscopic surgery due to infectious spondylodiscitis. Perioperative data and clinical outcomes were assessed by regular serologic testing, imaging studies, physical examination, and Visual Analog Scale, Oswestry Disability Index. A chart review was conducted to evaluate the locations, comorbidity, intraoperative blood loss, and surgical or anesthesia complication. All patients underwent a plain film follow-up at 3, 6, 9, 12, 18, and 24 months after surgery. A telephone interview was applied twice per year in the following 3 years.

**Results:** In total 43 patients were retrospectively enrolled in this study: 21 of them had an epidural abscess (group A);

22 of them did not (group B). Both groups shared similar patient characteristics including age, sex, location, American Society of Anesthesiologists, and Charlson comorbidity index. There were pathogens identification rate had no significant difference (6 vs. 6,  $p > 0.866$ ). Appropriate intravenous antibiotics for the identified pathogens isolated from infected tissue biopsy cultures were administered to patients for at least 30 days. No surgery or anesthesia-related complications. Although group A had significantly higher preoperative C-reactive protein level (group A: 13.02 vs. group B: 4.96,  $p = 0.005$ ), both decreased soon after the surgical intervention. Group B returned to normal range within 1 month while group A takes longer duration. All patients reported satisfactory relief of pain and neurological symptoms after surgery (Figs. 1, 2).

**Conclusions:** Percutaneous endoscopic surgery is an effective alternative to traditional open surgical decompression for the treatment of infectious spondylodiscitis as along as spinal epidural abscess.



**Fig. 1.** Comparison of C-reactive protein (CRP) (A) and erythrocyte sedimentation rate (ESR) (B) between the two groups. SEA, spinal epidural abscess; Preop, preoperative; Postop, postoperative.

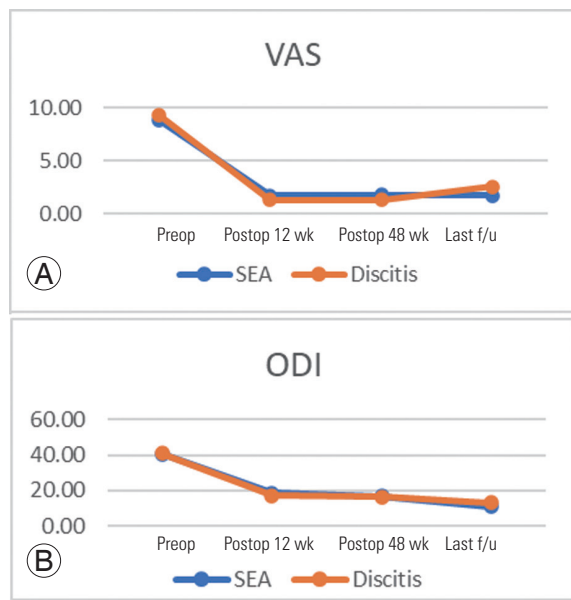


Fig. 2. Comparison of Visual Analog Scale (VAS) (A) and Oswestry Disability Index (ODI) (B) between the two groups. SEA, spinal epidural abscess; Preop, preoperative; Postop, postoperative; f/u, follow-up.

290

## Characteristics of L1 Slope in Thoracolumbar Sagittal Parameters of Degenerative Spondylosis

Yongsoo Choi

Department of Orthopaedic Surgery, Kwangju Christian Hospital, Kwangju, South Korea

**Introduction:** Thoracic kyphosis (TK), a thoracolumbar sagittal parameter, was hard to precisely identify the upper part criteria of the thoracic parameters because of the shoulder girdle and rib cage overlap.

**Purpose:** To find out the characteristics of L1 slope in thoracolumbar sagittal parameters of degenerative spondylosis by comparison of healthy young people.

**Methods:** Thirty-six patients who had chronic back pain and lower back pain as group I and 20 healthy people were classified as group II. The average age of the group I was  $72.00 \pm 10.00$  years, and group II was  $29.3 \pm 4.97$  years. Radiographic parameters including C7 sagittal vertical axis (SVA), TK, lumbar lordosis (LL), T1 slope, sacral slope (SS), pelvic tilt (PT), pelvic incidence (PI), and L1 slope was measured on standing lateral radiographs of the whole spine X-rays. We analyzed relationships between L1 slope and other parameters.

**Results:** There was a significant difference between the

two groups, and the mean L1 slope was  $2.70^\circ \pm 12.66^\circ$  in group I and  $12.24^\circ \pm 4.08^\circ$  in group II ( $p=0.000$ ). In the healthy young group, T1 slope and TK had a positive correlation with L1 slope ( $R^{T1 \text{ slope}}=0.448$ ,  $R^{TK}=0.537$ ). In the degenerative spondylosis group, L1 slope had a positive correlation with TK, LL, and SS ( $R^{TK}=0.480$ ,  $R^{LL}=0.774$ ,  $R^{SS}=0.385$ ) and a negative correlation with C7-SVA ( $R^{C7-SVA}=-0.529$ ). In total subjects, L1 slope had a positive correlation with TK, LL, and SS ( $R^{TK}=0.466$ ,  $R^{LL}=0.790$ ,  $R^{SS}=0.409$ ) and a negative correlation with C7-SVA and PT ( $R^{C7-SVA}=-0.608$ ,  $R^{PT}=-0.364$ ).

**Conclusions:** In degenerative spondylosis, LL may decrease, which leads to a decrease in the TK, an increase in the C7-SVA, and a decrease in L1 slope. These results suggest that the L1 slope could be helpful to understand the thoracolumbar sagittal alignment.

315

## Clinical Outcome of Intra-Articular Lumbar Facet Joint Steroid Injection in Patients with Lumbar Facet Joints Arthropathy

Li Loong Loh

Sultan Ahmad Shah Medical Centre @IIUM (International Islamic University Malaysia), Kuantan, Malaysia

**Introduction:** Facet joints arthropathy is a common source of chronic back pain, accounting for 15%–45% of low back pain. Facet joint injection with local anesthesia with steroids is known to have optimistic results with this technique. Our study aimed to evaluate the efficacy of the treatment response for the patients who were clinically diagnosed with lumbar facet joints syndrome by using the Oswestry Disability Index scoring (ODI) and Visual Analog Scale (VAS) as the standard assessment tool. Patients were evaluated before and after 6 months of treatment. We further look in the correlation between body mass index (BMI) and vitamin D status with the treatment outcome.

**Methods:** This is a quasi-experimental one-group time-series study where 36 patients with the clinical diagnosis of lumbar facet joints syndrome recruited from 2018–2019 and lumbar facet joints injections performed on a day-care basis by a senior spine surgeon in Sultan Ahmad Shah Medical Centre @IIUM (International Islamic University Malaysia), Kuantan. The diagnosis of lumbar facet joint arthropathy was established through a clini-

cal approach where the detailed history of back pain and physical examination by using “Revel’s criteria” (five or more of the seven clinical characteristics: pain relieved by recumbent position, age more than 65 years old, absence of pain exacerbation by coughing, absence of pain exacerbation by rising up from flexion, forward flexion, hyperextension, and extension-rotation) with the evidence of plain radiograph with the features of facet joints space narrowing, subchondral erosion/sclerosis, and presence of osteophytes. ODI and VAS scores were documented pre- and post-6 months after the the procedure. Serum vitamin D and BMI were documented prior to procedure. Statistical analysis of parametric data was performed by using descriptive analysis. Pearson correlation was used to determine the strength and direction between two continuous data. A paired t-test is used to compare between two-time points for the same patient (pre- and post-6 months of procedure for ODI percentage score). The inferential analysis was done using one-way analysis of variance (ANOVA) for the mean difference of ODI percentage score of pre- and post-6 months of lumbar facet joints injection. A p-value of  $<0.05$  is considered to indicate a statistically significant difference. Further analysis using post-hoc test was used for the significant result under one-way ANOVA.

**Results:** Patients’ outcomes were assessed using ODI and VAS showed improvement after the treatment. We failed to demonstrate a positive correlation between the BMI and the ODI scoring by using one-way ANOVA analysis ( $F [2.33]=3.003, p=0.063$ ). However, we noticed a significant improvement based on ODI scoring for the patients with normal weight. There is a positive correlation between vitamin D status and ODI scoring by using one-way ANOVA analysis ( $F [2.33]=3.294, p=0.049$ ). Dunnett T3 post-hoc test further exploited and revealed that the optimal category of vitamin D patients has shown to have a good outcome after the treatment.

**Conclusions:** Patient selection in the aspect of BMI and vitamin D status may serve as an important predictor of the success of the treatment. Normal BMI and optimal vitamin D status has a good clinical outcome after facet joint injection.

334

## The Feasibility and Efficacy of Computer-Assisted Screw Inserting Planning in the Surgical Treatment for Severe Spinal Deformity: A Prospective Study

Yong Hai

*Beijing Chaoyang Hospital, Capital Medical University, Beijing, China*

**Introduction:** Severe rigid adult deformities are composed of the characteristics of the complexity of anatomy, rigidity, and severe kyphosis or scoliosis, with or without neurological dysfunction, which may lead to physical disability or even death. The treatment strategy for such severe deformities is comprehensive. Different levels of spinal osteotomy have been developed and applied rapidly with good correction outcomes. However, due to the complex anatomy of the spine structure, the screw insertion, vertebrae osteotomy, correction, and decompression procedures increase the incidence of intra- or postoperative neurological complications significantly. This study is to report the preliminary outcomes utilizing individualized preoperative digital planning and three-dimensional (3D) printing guidance templates in the treatment of severe and complex spinal deformities.

**Methods:** After being approved by the Institutional Review Board of Beijing Chaoyang Hospital, eight adult patients with severe rigid kyphoscoliosis were included. Based on the preoperative radiological data, the surgery planning was simulated by software, and screw insertion and osteotomy guidance templates were designed and manufactured utilizing 3D printing techniques. The designed osteotomy and correction surgeries were performed utilizing the guidance templates. The perioperative, and radiological parameters and complications were collected and analyzed, including surgery duration, estimated blood loss, pre- and postoperative Cobb angle, trunk balance, the ratio of osteotomy simulation and execution, screw accuracy, and so forth.

**Results:** Of the eight patients, the primary pathology consisted of two adult idiopathic scoliosis, four congenital scoliosis, one ankylosing spondylitis, and one kyphosis secondary to tuberculosis. There are five kyphoscoliosis and two kyphosis regarding deformity characteristics. The pedicle subtraction osteotomy in three patients and vertebral column resection osteotomies in five patients were

performed with the application of the guidance templates. The average surgical duration is 361.25 minutes, average blood loss of 800 mL, and no surgery and instrument-related complications occurred. The main Cobb angle was corrected from 99.33° to 34.17°, and the kyphosis was corrected from 110.00° to 42.00°. The match ratio of osteotomy simulation and execution was 94.67%. The average screw accuracy rate was 93.04% in the cohort.

**Conclusions:** The clinical application of individualized digital surgical planning and the precise execution and 3D printing guidance templates in the treatment of severe adult rigid deformity is feasible, effective, and easy to promote. The preoperative osteotomy simulation is executed with high precision by utilizing the described guidance templates. It could be used to reduce the surgical risk and difficulty of screw placement and high-level osteotomy.

---

**338**

## Halo-Pelvic Traction Combine with Staged Posterior Correction for Severe Rigid Kyphoscoliosis of More Than 140 Degrees

Yong Hai

*Beijing Chaoyang Hospital, Capital Medical University, Beijing, China*

**Introduction:** Severe and rigid spinal deformities are real challenges for us with unfavorable correction and a high rate of complications. To evaluate the efficacy and safety of halo-pelvic traction (HPT) combined with staged corrective surgery in the treatment of extremely severe and rigid scoliosis (Cobb's angle >140°), a retrospective study was conducted.

**Methods:** Twelve consecutive cases of extremely severe rigid kyphoscoliosis were treated with one-stage HPT traction and a staged posterior procedure was included in the study. There were five males and seven females with an average age of 24.3 years. All underwent staged correction surgery. The patient had a major coronal curve or kyphosis >140° and flexibility <30%. The patient's height, main curve, height difference between the two shoulders, the height difference between the two iliac, and C7 plumb line (C7PL)–center sacral vertical line (CSVL) distance were evaluated before traction, after HPT, as well as after correction surgery.

**Results:** All patients underwent HPT traction and posterior surgery safely. The average time for HPT traction was

13.2 weeks. None of the patients underwent high-grade osteotomy. The main curve or kyphosis was improved from (162.5°±17.3°) before the operation to (75.7°±14.3°) after HPT, and to (57.7°±16.1°) after correction surgery. The corrective rate was 64.5%. The height, shoulder height difference, and C7PL–CSVL distance of patients after HPT and correction surgery were also significantly improved compared with those before traction. One patient developed C5 root palsy during traction, one patient developed skin ulceration infection, one patient developed cerebrospinal fluid leakage during correction surgery, and one patient developed transient lower extremity paralysis. Complications in all patients were relieved after treatment.

**Conclusions:** The combination of HPT and correction surgery is a safe and effective method for the treatment of extremely severe rigid scoliosis with Cobb's angle >140°, with less severe complications, and can avoid high-grade osteotomy during the procedure.

---

**363**

## Effects of Teriparatide Alone versus Percutaneous Vertebroplasty on Pain Control and Radiographic Outcomes after Osteoporotic Vertebral Compression Fracture: A Matched Cohort Study

Po-An Chen

*Department of Orthopaedic Surgery, Chang Gung Memorial Hospital, Yunlin, Taiwan*

**Introduction:** Vertebroplasty has become common for osteoporotic vertebral compression fracture (OVCF) because of fast relief of pain and improvement of the quality of life. However, complications including refracture or subsequent spine fracture may be expected. Treatment with teriparatide (TPD) has been applied to enhance fracture healing. However, the efficacy of TPD on acute OVCF is not clear. The aim of this study was to investigate the efficacy of 3-month TPD and compare this treatment with vertebroplasty in terms of clinical and radiographic outcomes.

**Methods:** This is a retrospective matched cohort study. Patients who received conservative treatment with a back brace, analgesic agents, and at least 3-month TPD treatment (20 mcg/daily, subcutaneous) for OVCF with at

least 1-year follow-up were included. Each enrolled TPD case was matched with two vertebroplasty cases using age and gender. Thirty TPD cases and 60 vertebroplasty cases were enrolled. Patient-reported pain scores, Numeric Pain Rating Scale, were obtained at diagnosis and 1, 3, and 6 months after diagnosis. Radiographic parameters including middle body height, posterior body height, wedge angle, and kyphotic angle were measured at diagnosis and 6 months after diagnosis. Fracture non-union and subsequent vertebral fractures were evaluated at 6 months after OVCF was diagnosed.

**Results:** TPD treatment showed inferior pain relief to the vertebroplasty group at 1 month but it did not show the difference at 3 and 6 months after diagnosis. In TPD cases, progression of vertebral body collapse was noted in terms of middle body height and wedge angle at the final follow-up but only wedge angle reached statistical significance ( $p=0.00$ ). Instead, both middle body height ( $p=0.00$ ) and wedge angle ( $p=0.00$ ) increased significantly after the operation in the vertebroplasty group. Four TPD patients were diagnosed with fracture non-union (4/30, 13.3%) but only one patient received vertebroplasty due to persistent back pain. Subsequent vertebral fracture within 6 months was significantly higher in the vertebroplasty group (12/60, 20%) than in the TPD group (1/30, 3.3%).

**Conclusions:** In acute OVCF, 3-month TPD treatment alone showed comparable pain improvement and less subsequent spine fracture than vertebroplasty. Thus, this study suggested that 3-month TPD treatment could be a treatment option for OVCF.

---

**370**

## Concomitant Atlantoaxial and Atlanto-Occipital Rotatory Dislocation in Children: Radiological Features, Diagnostic Pitfalls, and Long-term Outcome

Paul Koljonen

*The University of Hong Kong, Hong Kong*

**Introduction:** While the pathological manifestation of atlantoaxial rotatory dislocation has been well described in the medical literature, the combined dislocation of the atlantoaxial and atlanto-occipital joints, or occipital-atlantoaxial rotatory dislocation (OAARD) is a condition which has been poorly elucidated and probably underdiagnosed.

We believe that the pathogenesis of combined atlantoaxial and atlanto-occipital dislocation is most likely a result of untreated atlantoaxial rotatory dislocation leading to chronic secondary compensation measures occurring at the occiput-C1 joints. Unique clinical and radiological features lead to difficulty in diagnosis, and conventional treatment algorithms may not apply. This paper describes a combination of clinical and radiological features which can help clinicians correctly diagnose and treat OAARD.

**Methods:** A case series of pediatric occipital atlantoaxial rotatory dislocation is presented in this abstract. Three-dimensional (3D)-reconstructed computer tomography images and 3D printed models of the cervical spine are used to illustrate the deformity as well as dysplastic changes occurring in the dislocated occipital condyles, C1 and C2 facet surfaces. X-ray and dynamic computed tomography scans for rotational deformity are discussed in detail, including the introduction of 2 novel radiological signs termed the “trapezoidal anterior C1 shadow” and “isolated C1 spin-out” sign, which are pathognomonic of dislocation of the C1 ring. Diagnostic pitfalls, surgical techniques, and long-term outcomes are presented.

**Conclusions:** Concomitant occiput-atlantoaxial dislocation is a unique condition that is probably underdiagnosed in common daily practice. We emphasize the need for clinicians to exercise a high index of suspicion in children presenting with neck pain and torticollis. Early diagnosis and aggressive treatment of isolated atlantoaxial dislocation may help prevent chronic secondary dislocation at the occiput-C1 level. This paper describes a combination of clinical and radiological features which can help clinicians correctly diagnose and treat OAARD. More research is required on the long-term outcome following upper cervical spinal fusion in children.

---

**373**

## Knowledge Gaps in Biophysical Changes after Powered Robotic Exoskeleton Walking by Individuals with Spinal Cord Injury: A Scoping Review

Paul Koljonen

*The University of Hong Kong, Hong Kong*

**Introduction:** In addition to helping individuals with spinal cord injury (SCI) regain the ability to ambulate, the rap-



idly evolving capabilities of powered robotic exoskeletons provide an array of secondary biophysical benefits which can reduce the complications resulting from prolonged immobilization. This scoping review seeks to provide an overview of the known effects of overground exoskeleton use, on the prevention of secondary health complications, changes to the quality of life, and their effect on the independence of SCI individuals in the community settings. Moreover, the intent of the review is to identify gaps in the literature currently available and to make recommendations on focus study areas and methods for future investigations.

**Methods:** The reporting of methods and results in this scoping review follow the Preferred Reporting Items for Systematic reviews and Meta-Analyses extension for Scoping Reviews (PRISMA-ScR) guidelines. The framework by Arksey and O'Malley has been referenced for the protocol of this scoping review. PubMed, Cochrane, and EMBASE were searched for relevant articles from database inception to June 19, 2021; the bibliographies of included articles were screened. The search term used included "exoskeleton," "spinal cord injury," and related keywords, both as the free-text keywords and controlled vocabulary of their respective databases (e.g., MeSH for PubMed and Cochrane Library). The refinement of the protocol was done after the initial search, with a focus placed on a defining eligibility criterion with specific attention to the list of biophysical characteristics to include. The final selection of studies was separated into individual groups based on the type of biophysical characteristic that was evaluated; studies that measured more than one biophysical characteristic were included more than once across different tables. Data extraction templates were generated a priori, with minor modifications done after the initial search, and the data elements extracted included: study, intervention, number of training sessions, American Spinal Cord Injury Association grade, number of subjects, time-points during the trial when specific relevant measurements were taken, outcome metrics used in the study, and the presence of any control arms.

**Results:** A total of 654 articles were found in the initial search, 231 of which were found to be duplicates; 329 articles were excluded during the screening of the titles and abstracts, and a further 52 were eliminated after screening the full texts. In the final analysis, 42 papers were included from the initial search, combined with an additional eight from scanning through the reference lists of relevant stud-

ies. 50 unique studies were included in the charting process. Detailed results will be presented in this abstract.

**Conclusions:** This scoping review is the most robust systematic review performed on this topic to date. It has identified various focus areas in need of further investigation, such as cardiovascular health, bone mineral density, body composition changes, and independence and functional applications for exoskeletons. Detailed analysis of each domain was performed and presented. We have identified pitfalls, such as heterogeneous methodologies, disparate study populations, and dissimilar training programs, which need to be overcome in future studies.

---

374

## Length of Cervical Stenosis, Admission American Spinal Cord Injury Association Motor Scores, and Brain and Spinal Injury Center Scores Are Predictors of Recovery Rate Following Central Cord Syndrome

Paul Koljonen

*The University of Hong Kong, Hong Kong*

**Introduction:** Controversy remains about whether central cord injury syndrome (CCS) should be managed conservatively or by early surgical decompression. It is essential to understand how clinical and radiological parameters correlate with neurological deficits and how they predict recovery trajectories. This retrospective cohort study aims to determine whether quantitative magnetic resonance imaging (MRI) parameters and radiological scoring systems could be used as a reliable assessment tool for predicting neurological recovery trajectory following acute traumatic CCS.

**Methods:** We identified patients with CCS admitted between 2011 and 2018 with a minimum of 1-year follow-up. Cervical MRIs were analyzed for cord/canal dimensions, Brain and Spinal Injury Center (BASIC) scores, and sagittal grading as ordinal scales of intraparenchymal cord injury. Japanese Orthopaedic Association (JOA) recovery rates (>50% as good, <50% as poor) were analyzed against these variables by logistic regression and receiver operator characteristic curves. Additionally, we evaluated American Spinal Injury Association motor scale (AMS) scores/recovery rates.

**Results:** Sixty patients were included, of which 30 were managed conservatively and 30 via surgical decompression. The average follow-up duration for the entire cohort was  $51.1 \pm 25.7$  months. Upon admission, sagittal grading correlated with AMS and JOA scores ( $p < 0.01$ ,  $\beta = 0.48$ ). Volume of the C2 to C7 canal and axial cord area over the site of maximal compression correlated with AMS and JOA scores, respectively ( $p = 0.04$ ,  $\beta = 0.26$ ;  $p = 0.01$ ,  $\beta = 0.28$ ). We determined admission AMS more than 61 to be a clinical cut-off for a good recovery (area under the receiver operating curve [AUC], 0.74; 95% confidence interval [CI], 0.61–0.85; sensitivity=80.9%, specificity=69.2%;  $p < 0.01$ ). Radiological cut-offs to identify patients with poor recovery rates were length of cervical spinal stenosis more than 3.9 cm (AUC, 0.76; 95% CI, 0.63–0.87; specificity=91.7%, sensitivity=52.2%;  $p < 0.01$ ), BASIC score of more than 1 (AUC, 0.69; 95% CI, 0.56–0.81; specificity=80.5%, sensitivity=51.1%;  $p = 0.02$ ). Surgical decompression performed as a salvage procedure upon plateau of recovery did not improve neurological outcomes.

**Conclusions:** Clinical and radiological parameters upon presentation were prognosticative of neurological recovery rates in CCS. Surgery performed beyond the acute post-injury period failed to improve outcomes.

385

### Outcome Analysis of Anterior-Only Fixation for Three-Column Injury of the Sub-Axial Cervical Spine without Neurologic Deficit: Series of 16 Cases with Minimum 1-Year Follow-up

Bhaskar Sarkar

All India Institute of Medical Sciences Rishikesh, Rishikesh, India

**Study Design:** Retrospective case series.

**Purpose:** Our primary objective is to assess the outcome of anterior-only fixation in patients having 3-column cervical spine injury without neurological deficit at presentation.

**Overview of Literature:** Three-column sub-axial cervical spine injuries are inherently unstable. Current literature is divisive among different approaches, though a complete reduction of the facets seems imperative in most published series. We present the clinico-radiologic outcome of patients with such injury treated with anterior-only sta-

bilization and fusion in our center.

**Methods:** Patients with three-column cervical spine injury with intact neurology and treated with anterior-only fixation at our Level 1 Trauma Center, between January 2019 to July 2021, were included. Patients were followed up at monthly intervals for the initial 3 months and then at 3 monthly intervals till fusion. The outcome was measured by Neck Disability Index, Visual Analog Scale posterior neck pain, Spinal Cord Independent Measure III, segmental kyphosis, global sagittal cervical alignment, translation, sagittal vertical axis, and subsidence. Patients who could be followed up for a minimum of 1 year were included.

**Results:** A total of 20 patients with three-column injury and American Spinal Cord Injury Association Impairment Scale E for neurology were treated with anterior-only stabilization. Sixteen patients could complete the required minimum follow-up; hence, were available for final analysis. Mean segmental kyphosis was  $2.61^\circ \pm 0.85^\circ$  preoperatively which got corrected to  $-1.63^\circ \pm 1.18^\circ$  at the final follow-up. The mean translation was  $3.77 \pm 0.41$  mm preoperatively which was completely corrected post-surgery in all patients.

**Conclusions:** Anterior-only fixation yields satisfactory clinico-radiological outcomes in three-column sub-axial cervical injuries without neurological deficit, providing the sagittal balance of the spine is adequately restored. Selected patients with persistent unilateral facet dislocation may benefit from additional anterior foraminotomy obviating the need for supplemental posterior surgery.

392

### Spinopelvic Sagittal Parameters and Persistent Symptom after Transforaminal Lumbar Interbody Fusion in Lumbar Degenerative Disc Disease

Ghanshyam Kakadiya

Topiwala National Medical College & Bai Yamunabai Laxman Nair Hospital, Mumbai, India

**Introduction:** The most common cause of low back pain (LBP) in old age is lumbar degenerative disc disease (LDD). The prevalence of back pain increases with age and lifetime recurrence is as high as 85% with chronic LBP being the most common cause of disability. The study aims to investigate the change in spinopelvic sagit-

tal parameters and clinical outcomes after transforaminal lumbar interbody fusion (TLIF) in patients with LDD.

**Methods:** A Retrospective study of 60 consecutive patients with LDD operated with conventional TLIF were enrolled. All patients was divided into two groups according to their symptoms: group A (symptomatic patients) and group B (asymptomatic patients). The chief complaint was pain. Clinical and radiological data were collected and analyzed. We used Surgimap software to calculate sagittal spinopelvic parameters including lumbar lordosis (LL), segmental lordosis, sacral slope (SS), pelvic incidence (PI), and pelvic tilt (PT). Preoperative and postoperative data were recorded. Clinical and functional outcome was assessed on Visual Analog Scale and Oswestry Disability Index (ODI). Spinopelvic parameters and functional outcomes were compared between these groups.

**Results:** The mean age was  $65.62 \pm 5.84$  years in the symptomatic group and  $64.97 \pm 5.80$  years in the asymptomatic group. There was no significant difference in clinical and operative characteristics. ODI had improvement significant postoperatively in both groups. A SS and sagittal vertical axis offset did not show any significant difference. The mean PT in the asymptomatic group was  $16.1^\circ \pm 5.4^\circ$  which was significantly lower than symptomatic patients at  $19.1^\circ \pm 5.2^\circ$ . The mean PI in the asymptomatic patients was  $49.0^\circ \pm 8.7^\circ$  which was lower than symptomatic patients ( $51.0^\circ \pm 9.4^\circ$ ). The mean LL measured in the symptomatic group was  $42.2^\circ \pm 9.6^\circ$  which was significantly lower than asymptomatic patients ( $44.0^\circ \pm 11.0^\circ$ ).

**Conclusions:** The spinopelvic parameters are directly correlated with postoperative outcomes. Poor surgical planning is likely to lead to a mal-correction of spinal alignment. TLIF restores PT and global and segmental LL and provides a satisfactory outcome in symptomatic LDD. Insufficient restoration of PT was an independent factor for symptoms.

426

## Should Pedicle Subtraction Osteotomy Be Always Needed for Iatrogenic Flat Back Syndrome?: Comparison between Lateral Lumbar Interbody Fusion and Pedicle Subtraction Osteotomy

Hyung-Youl Park

*Department of Orthopaedic Surgery, Eunpyeong St. Mary's Hospital, College of Medicine, The Catholic University of Korea, Seoul, South Korea*

**Introduction:** Pedicle subtraction osteotomy (PSO) has been reported to be effective in correcting regional and global malalignment for fixed sagittal deformity. Recently, minimally invasive surgery techniques have been widely introduced to spine surgery, even in revision surgery. The purpose of this study was to compare the PSO with lateral lumbar interbody fusion (LLIF) for iatrogenic flat back deformity.

**Methods:** Among the patients who had undergone revision surgery for fixed sagittal deformity between 2012 and 2017, instrumented fusion surgery ending at the lumbar region with a minimum 2-year follow-up was included in this study. Twenty patients treated with LLIF were included in the LLIF group, while 13 patients undergoing PSO were included in the PSO group. Radiologic outcomes included spinopelvic parameters and sagittal alignments such as lumbar lordosis (LL) and sagittal vertical axis (SVA). In addition, the prevalence of optimal correction and proximal junctional kyphosis (PJK) were also assessed. Clinical outcomes included the numeric rating scale for back pain and leg pain and the Oswestry Disability Index. Complications and reoperations were also compared between the two groups.

**Results:** Although patient demographics including previous fusion levels were similar between the groups, the total level of fusion and use of iliac screws were significantly greater in the PSO group. Estimated blood loss and admission to the intensive care unit were significantly lower in the LLIF group. Regarding the radiological outcomes, the correction of LL and SVA was significantly greater in the PSO group ( $35.4^\circ \pm 13.7^\circ$  vs.  $9.0^\circ \pm 9.7^\circ$ ,  $p=0.000$  for LL;  $-85.6 \pm 60.0$  mm vs.  $-41.4 \pm 37.5$  mm,  $p=0.014$  for SVA). However, the prevalence of PJK and reoperations was significantly greater in the PSO group compared with the

LLIF group (69.2% vs. 15.0%,  $p=0.003$  for PJK; 38.5% vs. 5.0%,  $p=0.025$  for revision surgery), which resulted in significant loss of correction and similar clinical outcomes at last-follow-up.

**Conclusions:** PSO compared with LLIF was more effective to correct fixed sagittal malalignment after spinal surgery. However, PSO was associated with a greater possibility of morbidity and revision surgery. Therefore, treatments for fixed sagittal deformity should be tailored according to the individual case considering the degree of malalignment and patients' underlying condition.

428

## The Important Perioperative Predictor for Survival Rate Following Surgical Treatment for Metastatic Spine

Sung Tan Cho

Department of Orthopaedic Surgery, Inje University Ilsan Paik Hospital, Goyang, South Korea

**Introduction:** Metastatic lung cancer in the spine is one of the most difficult types to treat because of its rapid progression with unfavorable outcomes. And surgical intervention is needed in case of neurological compromise or structural instability. However, it is difficult to determine whether to perform the additional surgical intervention, as patients at the end stage of lung cancer often have low-performance status with significant atrophy of muscles. Furthermore, other prognostic factors related to survival rate after the surgery of metastatic spine lung cancer are not well understood. Therefore, the purpose of this study is to demonstrate the prognostic factors after spine surgery in metastatic spine lung cancer, especially focusing on the relationship between the atrophy of paraspinal muscles and the survival rate.

**Methods:** A total of 65 patients who underwent spine surgery for lung metastasis were reviewed. Patients were divided into two groups based on the survival period after surgery ( $\leq 6$  months;  $n=33$ , and  $>6$  months;  $n=32$ ). Based on computed tomography or magnetic resonance imaging, the quantity and quality of paraspinal muscles (psoas major, quadratus lumborum, erector spinae, and multifidus) at L3 vertebrae were analyzed by image J program. The factors included in the spinal instability neoplastic score, Karnofsky performance scale, and Bilsky grade were

evaluated. In addition, the survival period, the number of vertebrae involved in metastasis, preoperative intervention (embolization and radiotherapy), and surgery-related factors including the type of surgery, operative time, and blood loss were compared between the two groups.

**Results:** The survival period was significantly shorter in  $\leq 6$  months group ( $2.7 \pm 1.7$  months) than  $>6$  months group ( $22.6 \pm 16.0$ ,  $p < 0.001$ ). The cross-sectional area/height<sup>2</sup> of erector spinae was higher in  $>6$  months group ( $11.5 \pm 2.8$  cm<sup>2</sup>/m<sup>2</sup>) than  $\leq 6$  months group ( $10.0 \pm 2.3$  cm<sup>2</sup>/m<sup>2</sup>,  $p=0.013$ ). The quality and quantity of other paraspinal muscles including psoas major, quadratus lumborum, and multifidus were not significantly different between the two groups. The proportion of patients who could ambulate preoperatively ( $\leq 6$  months group: 17/33 [51.5%] vs.  $>6$  months group: 26/32 [81.3%];  $p=0.011$ ), multiple spinal metastasis patients ( $\leq 6$  months group: 27/33 [81.8%] vs.  $>6$  months group: 18/32 [56.3%];  $p=0.026$ ), and vertebral collapse ( $\geq 50\%$ /collapse,  $<50\%$ /no collapse;  $\leq 6$  months group: 15/15/3 vs.  $>6$  months group: 11/9/12;  $p=0.023$ ) were significantly different between two groups. During surgery, the amount of blood loss ( $p=0.042$ ) and transfusion ( $p=0.021$ ) were higher in  $\leq 6$  months group (blood loss:  $978.2 \pm 1,958.5$  mL and transfusion:  $748.5 \pm 1,103.0$  mL) than  $>6$  months group (blood loss:  $362.8 \pm 348.4$  mL and transfusion:  $298.4 \pm 546.9$  mL). The multiple logistic regression analysis showed that the number of vertebrae involved in metastasis was the most important prognostic factor after metastatic spine lung cancer surgery ( $p=0.038$ ; odds ratio, 0.238).

**Conclusions:** Atrophy of preoperative paraspinal muscles, especially erector spinae, could be used as a predictor of a short survival rate after spine surgery in metastatic spine lung cancer patients. Furthermore, in case of multiple spinal metastases with more collapsed vertebrae, the surgery should be determined carefully as a poor prognosis is expected. Finally, when the spine surgery is performed, controlling the amount of bleeding during surgery is very important for the patient's prognosis.

457

## Movement of the Sacroiliac Joint: A Cadaver Study

Dai-Soon Kwak

Department of Orthopaedic Surgery, College of Medicine, The Catholic University of Korea, Seoul, South Korea

**Introduction:** The dysfunctional sacroiliac joint (SIJ) was considered a source of lower back pain. Several researchers investigated the anatomy and biomechanics of the SIJ to understand the relationship between lower back pain and the SIJ. Many studies concluded the SIJ has little movement. However, some of the studies using spinopelvic parameters mentioned high pelvic incidence (PI) change. Moreover, with the development of imaging techniques such as EOS system and vertical computed tomography (CT)/magnetic resonance imaging, interest in sacroiliac joint movement and sagittal balance is increasing. Therefore, in this study, the movement characteristics of the sacroiliac joint were investigated by constructing an environment that could be measured and controlled more precisely than in past experiments.

**Methods:** We used six fresh cadavers (male [n=1], female [n=5]). The mean age was 85.25 years (range, 81–92 years) and the mean height was 152.47 cm (range, 142–161 cm). The pelvis was harvested by dissection. The hip bone, sacrum, coccyx, and ligaments between the hip bone and sacrum were preserved. Patient-specific spacer blocks for fixation of the sacrum were designed with CT images and printed by a three-dimensional (3D) printer. 3D-printed patient-specific spacer blocks were fixated at the anterior and posterior surface of the sacrum, and the sacrum with the spacer blocks was fully fixated. The external load was applied in superior (+) and inferior (-) directions at pubic symphysis (Fig. 1). Hip bone tilt angle, the movement of the pubic symphysis, and posterior superior iliac spine (PSIS) were measured with the applied load. For these measurements, 13 optical markers and four motion capture cameras were used.

**Results:** We observed the remarkable SIJ movements in the female pelvis in five of six samples (group B). However, only small movements were observed (-1.25° and 1.90° at ±200 N, respectively; group A) in one male sample. In the sample where the movement was observed (group B), the hip bone tilt angle was  $3.93^{\circ} \pm 0.49^{\circ}$  under +100 N and

$4.86^{\circ} \pm 0.39^{\circ}$  when applied with +200 N. The tilt angle was  $3.27^{\circ} \pm 1.42^{\circ}$  when -100 N was applied and  $5.76^{\circ} \pm 1.63^{\circ}$  applied with -200 N (Fig. 2). The movement of the pubic symphysis was small (within 0.35 mm) in all cases, and the movement of the PSIS was  $0.69 \pm 0.52$  mm,  $0.70 \pm 0.72$  mm,  $0.54 \pm 0.02$  mm,  $0.79 \pm 0.02$  mm at +100 N, +200 N, -100 N, and -200 N, respectively. Regardless of the loading direction, it showed an outward-opening behavior.

**Conclusions:** In this study, we confirmed that the SIJ is a joint with movement. This is consistent with recently published clinical papers. In particular, significant movements were observed in females. Furthermore, when the SIJ were tilted with load, the spacing of the pubic symphysis had little change, and the PSIS moved in the widen direction according to the tilt motion of the hip bone.

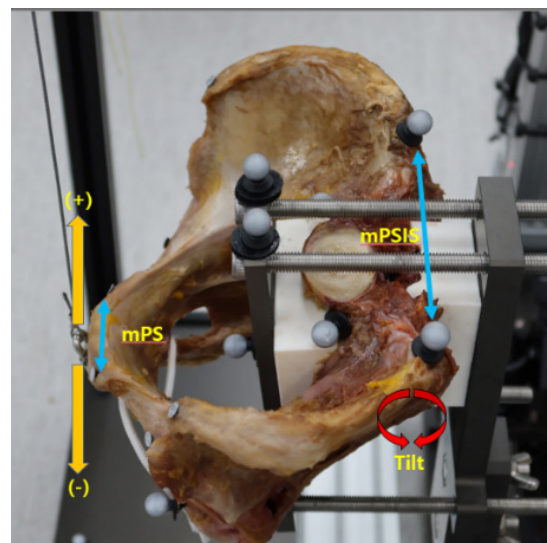


Fig. 1. Sample configuration and measurement parameters.

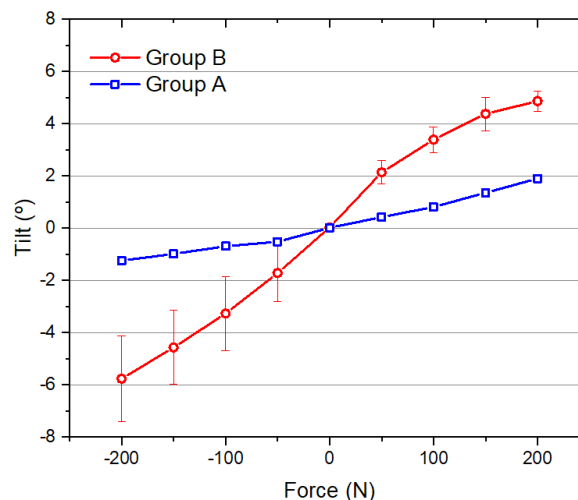


Fig. 2. Hip bone tilt angle with various load.

475

## Anterior Retropharyngeal Approach to the Upper Cervical Spine: A Corridor Familiar to the Spine Surgeon

Yuvaraja Murugan

*Pondicherry Institute of Medical Sciences, Kalapet, India*

**Introduction:** Anterior approach to the upper cervical spine (C1–C2) can be technically challenging for the young spine surgeon. The transoral approach has been the most popular access, but this entails working through the oropharyngeal cavity which is unknown territory for the young orthopedic spine surgeon. The anterior retropharyngeal approach (ARPA) provides access to C1–C2 via a corridor that is similar to the Smith-Robinson approach and can be extended to access sub-axial vertebrae if desired.

**Purpose:** To describe the application of ARPA in two challenging cases.

**Methods:** Patient 1: A 30-year-old male with a 5-month neglected type 2 odontoid fracture non-union with atlantoaxial subluxation which proved irreducible by traction underwent anterior release of fracture site and reduction by ARPA and posterior C1–2 instrumentation is a single setting. Patient 2: A 38-year-old male with achondroplasia presented with acute quadriplegia following a fall. Imaging revealed os odontoideum and narrow craniovertebral junction. He underwent posterior C1–2 wiring and iliac crest grafting by the Brooke technique. He presented at 3 months with failed arthrodesis and relapse of atlantoaxial subluxation. Revision surgery was done by ARPA. C2 ossicle was excised and C1–2 anterior cervical plating was performed.

**Results:** Patient 1 had an uneventful postoperative recovery and went on for fracture union at 3 months. Fusion and C1–2 alignment were maintained at 18-month follow-up. Pharyngeal wall violation occurred in patient 2 intraoperatively. He was kept on a nasogastric tube for 1 week and recovered uneventfully. Patient 2 expired at 2 months due to an unrelated cause.

**Conclusions:** ARPA provides an easy and safe passage to the upper cervical spine for the spine surgeon who might not be well versed in operating through the oropharyngeal cavity.

481

## Biomechanical Analysis of Long-Segment Posterior Pedicle Screw Fixation (+One Fracture Vertebrae) versus Short-Segment Posterior Pedicle Screw Fixation (+One Fracture Vertebrae) for Unstable Burst Fractures in Thoracolumbar Junction in the National Institute of Traumatology and Orthopaedics Rehabilitation: Our Experience in COVID-19 Pandemic Time

Dibakar Sarkar

*National Institute of Traumatology and Orthopaedics Rehabilitation, Dhaka, Bangladesh*

**Study Design:** Biomechanical study of instrumentation in vertebral body axial load injury pattern. It is an observational clinical study.

**Purpose:** The purpose of this study was to biomechanically evaluate long-segment posterior pedicle screw fixation (LSPF+one fracture vertebrae) vs. short-segment posterior pedicle screw fixation (SSPF+one fracture vertebrae) for unstable burst fractures in thoracolumbar junction.

**Overview of Literature:** Treatment of unstable thoracolumbar burst fractures remains controversial. This short-segment construct places a less surgical burden on the patient compared with long-segment constructs, but is less stable biomechanically, and thus has resulted in clinical failures. The addition of one screw placed in the fractured vertebral body represents an attempt to improve the construct stiffness.

**Methods:** Thirteen burst fractures from T12 to L2 were prepared in the National Institute of Traumatology and Orthopaedics Rehabilitation from January 2020 to December 2021 with an axial load fracture of at least 50% vertebral body height reduced. Titanium polyaxial pedicle screws and rods were used: SSPF+ one pedicle screw at the fractured level, and LSPF+ one pedicle screw at the fractured level. Each fixation construct was tested in flexion-extension, lateral bending, and axial rotation, and the range of motion was also recorded.

**Results:** Short-segment posterior pedicle screw fixation did not achieve stability ( $p<0.01$ ), whereas LSPF constructs were significantly stiffer than SSPF constructs and demonstrated more stiffness. The mean stiffness in flexion-extension was increased by 31% ( $p<0.03$ ). Relative

motion in terms of vertical and axial rotations was not significantly different between the two groups. The rod strain was significantly increased in LSPF compared with SSPF construct ( $p < 0.001$ ). The two groups were compared statistically by paired Student t-test.

**Conclusions:** In axial load fracture, LSPF+ one pedicle screw at fractured level I is more rigid than an SSPF+ one pedicle screw at the fractured level. Although the sample was small (due to COVID-19 pandemic), this study may help guide clinical decisions regarding burst fracture stabilization.

489

## Why Are Some Intervertebral Discs More Prone to Degeneration? Insights into Isolated Thoracic ‘Dysgeneration’

Jason Pui Yin Cheung

*Department of Orthopaedics and Traumatology, The University of Hong Kong, Hong Kong*

**Introduction:** The concept of ‘dysgeneration’ suggests a possible mechanism for earlier loss of disc signal intensity without discogenic pain. Thoracic intervertebral discs are least susceptible to painful disc degeneration (DD), and may well be a manifestation of ‘dysgeneration.’ It is unclear what factors are associated with thoracic DD occurring in isolation versus tandem, and their clinical implications.

**Purpose:** To determine the prevalence of isolated thoracic degeneration on magnetic resonance imaging, the demographic factors and imaging features associated with isolated thoracic degeneration. In addition, to determine the patient-reported quality of life outcomes (PRQoL) associated with patterns of thoracic degeneration.

**Methods:** Open recruitment included 2007 southern Chinese volunteers, not based on the presence or absence of clinical symptoms. Each disc from C2/3 to L5/S1 was measured by Pfirrmann and Schneiderman grading. Disc herniation, Schmorl’s node (SN), high-intensity zones (HIZ), and Modic changes (MC) were studied. DD was defined by Pfirrmann 4 or 5. Subjects were divided into ‘isolated thoracic degeneration’ and ‘tandem thoracic degeneration.’ The association between imaging findings and isolated thoracic degeneration was determined by multivariate logistic regression. PRQoL scores including a 36-item Short Form questionnaire and Visual Analog Scale

(VAS) for low back pain (LBP) were recorded for subjects willing to fill out the questionnaires.

**Results:** The mean age of subjects was  $50.0 \pm 0.5$  years of age and 61.4% were female ( $n=1,232$ ). Isolated thoracic degeneration had a cohort prevalence of 2.3%. Factors associated with isolated thoracic degeneration included a lower age, C6/7 HIZ, T8/9 HIZ, and T8/9 SN. Factors associated with tandem thoracic degeneration included L4/5 posterior bulge. The thoracic and lumbar tandem degeneration group had higher bodily pain, despite a lower VAS score (LBP) on the day of imaging, and higher PCS when compared to isolated lumbar degeneration.

**Conclusions:** Isolated thoracic degeneration has a prevalence of 2.3% but could be underestimated due to age-related DD. It has an earlier age of onset, mostly involving the mid-thoracic region (T5/6–T8/9), and is associated with maldevelopment like SN. Subjects with tandem thoracolumbar degeneration had less severe lumbar DD and lower VAS scores for LBP, but higher bodily pain and higher PCS as compared with isolated lumbar degeneration. This paints the picture of ‘dysgeneration’ occurring in the thoracic spine accompanied by the lumbar spine. Future work should study longitudinally the incidence and onset of thoracic DD in young subjects with thoracic SN.

490

## Impact on Patient-Perceived Quality of Life between Chronic Non-specific Low Back Pain and Axial Spondyloarthritis: Propensity-Matched Comparison

Jason Pui Yin Cheung

*Department Of Orthopaedics and Traumatology, The University of Hong Kong, Hong Kong*

**Introduction:** Chronic non-specific low back pain (LBP) and axial spondyloarthritis (SpA) are two debilitating yet different chronic musculoskeletal disorders. To compare their burden, propensity score matching is used to control for potential confounders and match the study subjects.

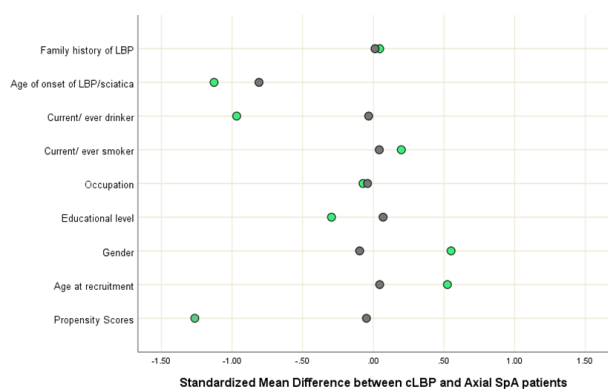
**Purpose:** To compare the burden between chronic non-specific LBP and SpA.

**Methods:** Two prospectively collected cohorts of LBP ( $n=269$ ) and SpA ( $n=218$ ) patients were studied. Out-

comes included current LBP, 36-item Short Form (SF-36) questionnaire, Oswestry Disability Index (ODI), European Quality of Life (EuroQol) 5-Dimension 5-Level (EQ-5D-5L) questionnaire, and EuroQol Visual Analog Scale (EQ-VAS). With the inherent differences between the two types of patients, propensity score matching was performed for comparing the two groups. Baseline covariates of age, gender, education level, occupation, smoking, and drinking history were selected for the estimation of propensity scores for each subject with the logistic regression model. Significant independent variables for the outcome of current back pain were included in the multivariate logistic regressions.

**Results:** A total of 127 matched pairs were identified, with 254 patients. In the matched cohort (Fig. 1), more patients with chronic LBP had current back pain (95.3%) as compared to SpA (71.7%). Patients with SpA were younger ( $p<0.001$ ), with more males ( $p<0.001$ ) and better educated ( $p=0.001$ ). There were less current back pain and higher non-steroidal anti-inflammatory drug use ( $p<0.001$ ). Most SpA patients have lower ODI than LBP patients and with low disease activity. Patients with LBP had worse outcome scores as compared to SpA patients given the same VAS. LBP patients had an 8.6 times odds ratio (95% confidence interval, 3.341–20.671;  $p<0.001$ ) of experiencing current back pain compared to SpA patients.

**Conclusions:** The disease activity of SpA patients is well-controlled. However, patients with chronic LBP have worse pain severity, disability, and health-related quality of life. This has implications for resource utilization and the necessity of advancing LBP understanding and management.



**Fig. 1.** Standardized mean difference between chronic low back pain (cLBP) (green) and axial spondyloarthritis (SpA) (grey) patients before and after matching.

## 496

### Separation Surgery Followed by Stereotactic Ablative Radiotherapy for Metastatic Epidural Spinal Cord Compression: A Systematic Review and Meta-Analysis for Local Progression Rate

Jason Pui Yin Cheung

*Department of Orthopaedics and Traumatology, The University of Hong Kong, Hong Kong*

**Introduction:** Spinal metastasis is the most common metastatic skeletal disease in cancer patients. Metastatic epidural spinal cord compression (MESCC), which occurs in 5%–14% of cancer patients, is an oncological emergency because it may cause a permanent neurological deficit. Separation surgery followed by stereotactic ablative radiotherapy (SABR), so-called “hybrid therapy,” has shown effectiveness in local control of spinal metastasis and has become an integral treatment option for patients with MESCC.

**Purpose:** We performed a meta-analysis and meta-regression analysis to clarify the local progression rate of hybrid therapy and the risk factors for local progression.

**Methods:** We searched PubMed, EMBASE, Scopus, Cochrane Library, and Web of Science databases from inception to December 2021. Meta-analyses of proportions were used to analyze the data using a random-effects model to calculate the pooled 1-year local progression rate and confidence interval. Subgroup analyses were performed using meta-analyses of odds ratio (OR) for comparisons between groups. We also conducted a meta-regression analysis to identify the factors that caused heterogeneity.

**Results:** A total of 661 patients from 13 studies (10 retrospective and three prospective) were included in the final meta-analysis. The quality of the included studies assessed using the Newcastle–Ottawa scale ranged from poor to fair (range, 4–6). The pooled local progression rate was 10.2% (95% confidence interval [CI], 7.8–12.8%;  $I^2=30%$ ) and 13.7% (95% CI, 9.3–18.8%;  $I^2=55%$ ) at postoperative 1 and 2 years, respectively. The subgroup analysis indicated that patients with a history of prior radiotherapy (OR, 5.14; 95% CI, 1.71–15.51) and lower radiation dose per fraction (OR, 4.57; 95% CI, 1.88–11.13) showed significantly higher pooled 1-year local progression rates. In the moderator analysis, the 1-year local progression rate was



significantly associated with the proportion of patients with a history of prior radiotherapy ( $p=0.036$ ) and those with colorectal cancer as the primary origin ( $p<0.001$ ).

**Conclusions:** The pooled 1-year local progression rate of hybrid therapy for MESCC was 10.2%. In subgroup and moderator analyses, a lower radiation dose per fraction, history of prior radiotherapy, and colorectal cancer showed a significant association with the 1-year local progression rate.

505

## Atrophy of the Posterior Cricoarytenoid Muscle as an Indicator of a Recurrent Laryngeal Nerve Injury History Before Revision Anterior Cervical Surgery

Sang Yun Seok

*Department of Orthopaedic Surgery, Daejeon Eulji Medical Center, Daejeon, South Korea*

**Introduction:** In our recent study, we observed more cases of symptomatic normal vocal cord motility than asymptomatic vocal cord palsy (VCP) in preoperative laryngoscopy examinations of a revision anterior cervical spine surgery (ACSS) cohort. We assumed that the intrinsic muscle atrophy caused by recurrent laryngeal nerve injury could cause vocal cord-related symptoms. Radiological examinations made prior to revision ACSS were reviewed in this present study in relation to the posterior cricoarytenoid (PCA) muscle, one of the intrinsic muscles.

**Methods:** We retrospectively analyzed 68 patients who underwent a revision ACSS for cervical pathology. Patients in this group with vocal cord-related symptoms were classified as a symptomatic group (group S,  $n=11$ ), and those without symptoms as asymptomatic (group AS,  $n=57$ ). The bilateral size and luminosity of the PCA muscles in these patients were measured in the axial view with a Picture Archiving and Communication System using preoperative vertebral arteriography computed tomography (CT) and magnetic resonance imaging (MRI) evaluations. Since the size and luminosity values were different on each image, the ratios of the ipsilateral and contralateral muscle values were determined for each modality.

**Results:** There were no abnormal findings of VCP in laryngoscopy study. However, the mean ratio of the PCA muscle size on CT was  $1.40\pm 0.37$  in group S and  $1.02\pm 0.12$

in group AS ( $p=0.007$ ). These values on the MRI were  $1.49\pm 0.45$  in group S and  $1.02\pm 0.14$  in group AS, which was also a significant difference ( $p=0.008$ ). The PCA muscle luminosity on the MRI was  $1.03\pm 0.16$  in group S and  $0.97\pm 0.18$  in group AS, which was not a significant difference ( $p=0.608$ ).

**Conclusions:** Evaluating the size of the PCA muscle before conducting a revision ACSS can predict a previous recurrent laryngeal nerve injury. Careful planning for the appropriate surgical approach should be undertaken if vocal cord-related symptoms and atrophy of PCA muscle are evident.

529

## Efficacy and Safety of Oblique Posterior Endplate Resection for Wider Decompression (Trumpet-Shaped Decompression) during Anterior Cervical Discectomy and Fusion

Sehan Park

*Department of Orthopaedic Surgery, Dongguk University Ilsan Hospital, Goyang, South Korea*

**Introduction:** Anterior cervical discectomy and fusion (ACDF) provides a limited workspace, and surgeons often need to access the posterior aspect of the vertebral body to achieve sufficient decompression. Oblique resection of the posterior endplate (trumpet-shaped decompression, TSD) could widen the workspace, enabling the removal of lesions behind the vertebral body (Figs. 1, 2).

**Methods:** A total of 333 patients who underwent ACDF for the treatment of cervical myelopathy/radiculopathy and were followed up for  $\geq 1$  year were retrospectively reviewed. Patients who underwent TSD during ACDF (TSD group) and those who underwent surgery without TSD (non-TSD group) were compared.

**Results:** Fifty-seven patients (25.1%) were included in the TSD group and 170 patients (74.9%) were in the non-TSD group. In the TSD group,  $28.2\pm 5.5\%$  of the endplate was resected, and  $26.0\pm 6.1\%$  of the region behind the vertebral body could be visualized via the TSD technique. The resection angle was  $26.9^\circ\pm 5.9^\circ$ . The fusion rate assessed did not significantly differ between the two groups. Furthermore, there were no significant intergroup differences in subsidence.

**Conclusions:** TSD widened the workspace during ACDF,

and 26% of the region posterior to the vertebral body could be accessed using this technique. The construct stability was not adversely affected by TSD as demonstrated by the similar fusion and subsidence rates among the patients who underwent TSD and those who did not. Therefore, TSD can be safely applied during ACDF when compressive lesions extend behind the vertebral body and are not limited to the disc space, enabling adequate decompression without disrupting the construct stability.

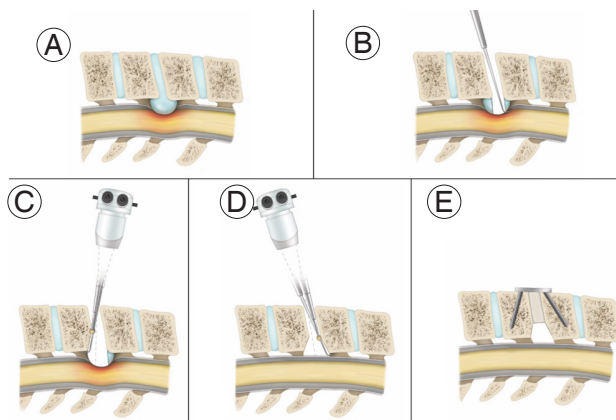


Fig. 1. (A–E) Procedures for oblique resection of the posterior endplate (trumpet-shaped decompression).

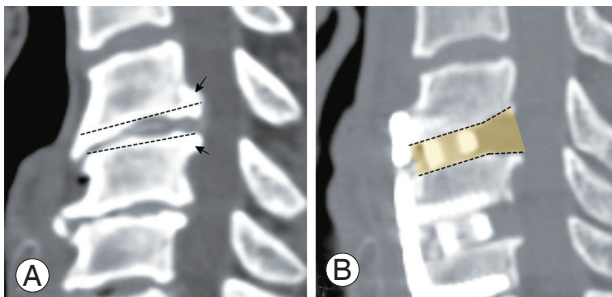


Fig. 2. (A, B) Oblique resection of the posterior endplate (trumpet-shaped decompression) (arrows).

543

## Surgical Management of Adult High-Grade Spondylolisthesis: How I do It

Md Kamrul Ahsan

Bangabandhu Sheikh Mujib Medical University, Dhaka, Bangladesh

**Introduction:** Treatment options for symptomatic high-grade spondylolisthesis (HGS) are surgery. But the surgical treatment of HGS is often difficult and related techniques are still debated.

**Purpose:** To assess the outcome of adult HGS by partial reduction, instrumentation, and circumferential fusion in a single institution.

**Methods:** This quasi-experimental study was carried out on 20 patients of HGS with various etiologies (lytic [n=14], degenerative [n=4], and dysplastic [n=2]) with mean age 43.35 years (range, 21–55 years). The diagnosis was confirmed by history, clinical examination, and radiology. Patients were evaluated clinically by Visual Analog Scale (VAS) score, functionally by Oswestry Disability Index (ODI), radiological fusion by Hackenberg criteria, and overall outcome by Inoue's criteria.

**Results:** The average follow-up was 14.6 months. All patients had low back pain (n=20), radiculopathy and claudication pain (n=16), cosmetic deformity (n=4), palpable step (n=20), hamstring tightness (n=8), SLR test positive (n=6), sensory involvement (n=16), and motor involvement in patients (n=14). Level of involvement was at L5–S1 (n=12) and L4–L5 (n=8). There were Meyerding's grade III (n=18) and grade IV (n=2) slips. Amazing changes were observed in the percentage of slip, slip angle, disc height, and spinopelvic parameters after 12 months of operation. The mean VAS reduced from 6.80 to 2.00 and the mean ODI reduced from 67.5 to 7.00. There were no pseudarthroses or significant instrumentation failures. Fusion was achieved in 20 cases (100%). Seventeen patients (85%) got satisfactory outcomes.

**Conclusions:** Partial reduction, decompression, and instrumented circumferential fusion are viable options in adult high-grade slips for relieving the symptoms and achieving stability and fusion.

570

## The Surgical Management for Subaxial Instability by Posterior Correction Fixation in Using the Cervical Pedicle Screw Method—New Method at Can Tho Central General Hospital

Huynh Thong Em

Huynh Can Tho Central General Hospital, Can Tho, Vietnam

**Introduction:** Lower cervical instability is a condition in which ligaments, tendons, and bones around the cervical spine become loose and can cause damage to the nervous system, manifesting as discomfort, numbness, paralysis,

or tetraplegia. Trauma or repetitive overuse that causes microtrauma in the ligaments surrounding the cervical spine structures may be the cause of cervical instability. Posterior cervical pedicle screws (CPSs) can treat lower cervical instability because they might give good reduction and rigid fixation.

**Purpose:** To evaluate the effectiveness of decompression, reduction, and fixation of the lower cervical instability and the accuracy of pedicle screw insertion by using a specially designed angle measurer and the perioperative fluorescent radiology in an oblique position.

**Methods:** This study was designed as a prospective clinical study. All of the patients were diagnosed with cervical instability and met our study criteria. This study was conducted at Can Tho Central General Hospital in 2020–2022. Forty-three cases, including 33 trauma and 10 pathological spinal disorders, were operated on at the Center for Trauma and Orthopedics, Can Tho Central General Hospital. The patients were allowed to sit up and walk as soon as possible on postoperative day 1. The postoperative and long-term survey of the C2–C7 angle was realized at 1 week, 1 month, and 3 months. The data to assess the accuracy of the pedicle screw insertion was analyzed by multislice spiral computed tomography scan with contrast following the classification of Dae-Jean Jo.

**Results:** The series included 41 men and two women. The mean age was 52.81 years (range, 20–74 years), and the number of CPS insertions was 308 screws. The mean surgical time was 211.8 minutes (range, 120–370 minutes), and the mean perioperative blood loss was 235.8 mL (range, 70–500 mL). Immediately after surgery, the mean C2–C7 angle was  $17.05^{\circ} \pm 1.25^{\circ}$  and at final follow-up, the mean C2–C7 angle was  $15.91^{\circ} \pm 0.75^{\circ}$ . Accuracy of CPSs insertion according to the classification of Dae Jean Jo was 92.2% (grade 0: 80.51% and grade 1: 11.68%; misplaced CPS in 7.8% [grade 2: 6.49% and grade 3: 1.22%]). There was no postoperative infection. There were no perioperative neurovascular complications. There were no mechanical complications at follow-up (loose, broken, dislodged, or broken rod), and the mean follow-up was 17.73 months (range, 3–30 months).

**Conclusions:** Utilizing pedicle screws is one of the most effective surgical procedures for treating lower cervical instability. Good neurological recovery findings were obtained. The rigid fixation permits the maintenance of a physiological cervical spine position and decreases postoperative complications. A posterior CPS is one of the

most successful treatment options for traumatic or degenerative cervical instability due to its low complication rate and lack of severe nerve and artery damage.

573

## Difficulty in Head Control and Horizontal Gaze Caused by Cervical Spinal Imbalance after Neuromuscular Scoliosis Correction Surgery: Chin-To-Sky Deformity

Dong-Ho Kang

*Department of Orthopaedic Surgery, Seoul National University Hospital, Seoul, South Korea*

**Introduction:** Neuromuscular scoliosis (NMS) can occur in a variety of neuromuscular disorders and often results in the gradual weakening of neck muscles. After NMS correction by surgery, some patients experienced posterior head drop during neck extension and could not restore to a position for horizontal gaze. In this study, this phenomenon was referred to as chin-to-sky deformity, due to the characteristic position of the chin pointing towards the sky.

**Purpose:** To evaluate the demographic, physical, surgical, and radiological factors that may contribute to the occurrence of the chin-to-sky deformity after NMS correction surgery.

**Methods:** This is a retrospective case series study from a single tertiary hospital. This study enrolled patients who underwent posterior spinal deformity correction surgery for NMS. The outcome measures of this study were chin-to-sky deformity risk concerned with demographic data, chin-brow vertical angle (CBVA), and perioperative radiographic parameters associated with sagittal balance. Demographic data, CBVA and perioperative radiographic parameters, cervical lordosis, thoracic kyphosis (TK), lumbar lordosis, C2–C7 sagittal vertical axis (SVA), C7–S1 SVA, and T1 slope (T1S) were reviewed from medical records. Linear-by-linear association, Pearson's chi-square test, and multivariate logistic regression analysis were used to determine the factors associated with the chin-to-sky deformity.

**Results:** Sixty patients were enrolled and divided into two groups according to the occurrence of chin-to-sky deformity. There were no significant differences in the demographic data between the two groups. However, as

the preoperative T1S were smaller, the postoperative chin-to-sky incidence was significantly higher ( $p=0.041$ ). The occurrence of the chin-to-sky deformity was also significantly higher in smaller postoperative TK, CBVA, T1S, C2–C7 SVA, and C7–S1 SVA ( $p=0.034, 0.006, 0.001, 0.006,$  and  $0.004$ , respectively). The odds ratios, calculated via logistic regression, of chin-to-sky deformity according to preoperative T1S, postoperative T1S, CBVA, and C7–S1 SVA were 0.955, 0.887, 0.917, and 0.975, respectively (Table 1).

**Conclusions:** Correction of NMS requires special consideration of sagittal balance and head position. In patients with smaller preoperative T1S, attention should be paid to avoid postoperative chin-to-sky deformity. Optimal correction of T1S, CBVA, and C7–S1 SVA is essential to prevent such phenomena after surgery.

**Table 1.** Logistic regression for risk of chin-to-sky phenomenon

Variable	B	p-value	Odds ratio (95% confidence interval)
Preoperative			
T1 slope	-0.046	0.041	0.955 (0.913–0.998)
Postoperative			
T1 slope	-0.120	0.006	0.887 (0.814–0.967)
Chin-brow vertical angle	-0.086	0.012	0.917 (0.857–0.982)
C7–S1 sagittal vertical axis	-0.025	0.009	0.975 (0.957–0.994)

Statistically significant results are marked in bold.

598

## Surgery of Complex Pediatric Spinal Deformity: Where Intraoperative Neurodeficit Is an Issue

Anowarul Islam

Bangabandhu Sheikh Mujib Medical University, Dhaka, Bangladesh

**Introduction:** One of the greatest challenges encountered by spine surgeons is the preservation of neurology during the different corrections of deformities of the pediatric group. As the spinal cord and the nerve roots are already compromised by the deforming force, perioperative manipulation may cause further damage to the neural structures. An expert surgeon in a well-equipped operation theater may avoid some sort of complications, but the chance of intraoperative neurodeficit is always an issue for the treating surgeons.

**Purpose:** To evaluate the neurological outcome of surgical procedures that are performed to correct the complex pediatric spinal deformity.

**Methods:** This prospective interventional study included 15 cases of complex pediatric spinal deformity was carried out in the Spine Surgery Division of the Orthopaedic Surgery Department of Bangabandhu Sheikh Mujib Medical University, Dhaka and other private hospitals in Dhaka city, Bangladesh, from January 2012 to July 2022. Among the patients included in this study, six patients had Lanke type 4, 5, and 6 complex scoliotic curves, five patients had post-tubercular kyphotic deformity, and four patients had congenital hemivertebra. All the patients had neurological impairment. The scoliotic group underwent correction by axial translational technique, the kyphotic group underwent pedicle subtraction osteotomy with long segment posterior stabilization and the patients with congenital hemivertebra underwent vertebral column resection. Pre- and postoperatively, neurological assessment was done by the modified Nurick grading system, scoliosis and kyphosis angle was measured by Cobb's angle measurement method, and overall functional assessment was measured by modified Odom's score.

**Results:** The total number of patients was 15. The average age was 14 years (range, 9–17 years). In our series 11 patients had improved their neurological status by at least 1 Nurick grade, two patients remained unchanged, and two patients deteriorated. The average kyphotic correction was  $15^{\circ} \pm 3.25^{\circ}$  and scoliosis correction was  $36^{\circ} \pm 14.19^{\circ}$ . Overall, 54% of patients had excellent, 28% had good, 10% had fair, and 8% had poor outcomes.

**Conclusions:** Surgery in the complex deformed pediatric spine is a matter of great concern for spinal surgeons and is often associated with deterioration of neurological status. However, careful surgery by a highly efficient spine surgeon in a well-equipped center and perioperative use of neuromonitor may lessen the incidence of intraoperative neurodeficit.

603

## Effect of Osteoporosis on the Clinical and Radiological Outcomes Following One-Level Anterior Cervical Discectomy and Fusion with Plating

Chul Gie Hong

*Department of Orthopaedic Surgery, Kangwon National University Hospital, Chuncheon, South Korea*

**Introduction:** A graft-related problem such as cage subsidence or plate migration following anterior cervical discectomy and fusion (ACDF) is frequently reported. However, few studies have analyzed surgical outcomes after ACDF according to bone quality. We aimed to evaluate the impact of osteoporosis on the clinical and radiological outcomes of single-level ACDF with plate augmentation and to confirm the efficacy and stability of anterior plate augmentation in osteoporosis patients.

**Methods:** A total of 101 non-osteoporotic (T-score  $\geq 1.0$ , group A) and 25 osteoporotic (T-score  $\leq -2.5$ , group B) patients who underwent one-level ACDF with plating were followed up for more than 2 years. Visual Analog Scale (VAS) for neck pain and arm pain and Neck Disability Index (NDI) were assessed for clinical outcomes. Fusion success was identified with the interspinous motion on dynamic flexion-extension radiographs and extra-graft bridging bone on computed tomography. Plate migration and cage subsidence were also evaluated. The clinical and radiological parameters were compared between groups A and B. Subgroup analysis was performed according to the presence of cage subsidence or plate migration.

**Results:** Although clinical outcomes such as VAS scores for the arm ( $2.0 \pm 2.3$  vs.  $2.4 \pm 2.9$ ,  $p=0.490$ ) and neck pain ( $1.4 \pm 1.9$  vs.  $1.8 \pm 2.2$ ,  $p=0.343$ ) and NDI ( $7.7 \pm 7.1$  vs.  $9.9 \pm 7.5$ ,  $p=0.225$ ) were slightly higher in group B, there was no statistically significant difference. Cage subsidence (13.9% vs. 16.0%,  $p=0.755$ ) and plate migration rates (7.9% vs. 8.0%,  $p=1.000$ ) did not differ between the two groups. The fusion rate at 1 year postoperatively was higher in group A than in group B (80.3% vs. 68.2%,  $p=0.139$ ), and slightly increased in both groups (94.6% vs. 86.4%,  $p=0.178$ ) at the final follow-up. As a result of subgroup analysis, the final fusion rate was higher in the non-subsidence group than in the subsidence group (66.7% vs. 98.1%,  $p<0.001$ ) and the proportion of males

was higher in the cage subsidence group. Also, the change of disc height ( $2.9 \pm 1.6$  vs.  $2.1 \pm 1.1$ ,  $p=0.055$ ) was higher in patients with plate migration.

**Conclusions:** ACDF with plate fixation did not show a significant difference in the incidence of graft-related problems in the non-osteoporosis group and the osteoporotic group. Thus, plate augmentation provides relatively good stability even in patients with poor bone quality. Because cage subsidence can significantly affect the fusion rate, it is recommended to consider plate augmentation to increase the fusion rate in patients with a high risk of cage subsidence.

637

## Evaluation of Radiation Exposure during Minimally Invasive Spine Surgery: How High Is the Exposure Dose? A Cadaveric Study

Kazuta Yamashita

*Tokushima University, Tokushima, Japan*

**Introduction:** Most physicians use fluoroscopy to generate real-time images of a patient's body to view the internal anatomy. The fluoroscopic images provide physicians with valuable information that helps determine the appropriate and effective intervention. The use of C-arm fluoroscopy for spine surgery has rapidly increased because of the increase in minimally invasive procedures such as percutaneous pedicle screw insertion, full-endoscopic spine surgery, and lateral interbody fusion. However, medical staff and patients are exposed to direct and scatter radiation because of the high frequency and long duration of fluoroscopy use and their close proximity to the fluoroscope. Some reports revealed industrial accidents occurred to spine surgeons such as basal cell carcinoma and cataract.

**Methods:** We quantified radiation exposure sustained by the patient and surgeon during the use of C-arm fluoroscopy with the X-ray source in different positions (under the table, over the table, and laterally). Seven fresh cadavers were irradiated for 1, 3 minutes with C-arm fluoroscopy using standard X-ray and pulsed and collimated X-ray beams. Radiation exposure doses were measured using optically stimulated luminescence dosimeters at different simulated areas such as the center of the irradiation area, and the surgeon's eye, hand, and thyroid gland (Fig. 1).

**Results:** The risk of direct and scatter radiation exposure

was the greatest with the lateral position, which increased by more than 200 times and more than 30 times, respectively, compared with that from a position under the table. Direct radiation was attenuated to less than one-hundredth after passing through the body of the cadaver. All radiation exposure doses were positively correlated with total exposure time. The radiation exposure doses associated with the use of pulsed fluoroscopy (8 times per second) were reduced by approximately 30% for the patient and by approximately 70% for the surgeon's hand and thyroid gland as compared with those associated with the use of continuous fluoroscopy. The radiation exposure doses associated with the use of collimated beams were reduced to approximately 65% for these organs as compared with those associated with the use of non-collimated fluoroscopy.

**Conclusions:** The surgeon should evaluate the exposure dose with every procedure and protect their hand and eye using appropriate shielding. By being cognizant of the radiation exposure risks, the action taken by the surgeon can positively affect many lives by minimizing the effects of ionizing radiation not only on the surgeon but also on the patient and the rest of the operating room personnel. Surgeons can minimize radiation exposure by understanding the physics of radiation and maximizing the use of safety techniques offered by their specific fluoroscopy units. In particular, the use of pulsed fluoroscopy and collimation can reduce radiation exposure to themselves.

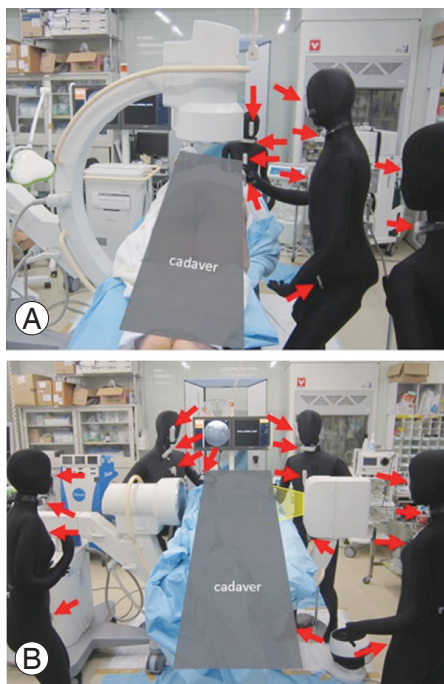


Fig. 1. (A, B) Measurement of radiation exposure doses (arrows).

730

## How Helpful Is the Halo Gravity Traction in Severe Spinal Deformity Patients: A Systematic Review and Meta-analysis

Jianqiang Wang

Beijing Chaoyang Hospital, Beijing, China

**Introduction:** Severe spinal deformity usually refers to a coronal or sagittal deformity with a Cobb angle  $>100^\circ$ . Despite the continuous progress in surgical techniques, the severe spinal deformity has always been a challenge for spinal surgeons. Because more segments need to be released in patients with severe spinal deformities, it is easier to damage the neurological function during the operation. Besides, such patients are often associated with cardiopulmonary dysfunction, which further increases the risk of surgery. As a reliable and lasting solution for those challenges, preoperative traction has been used widely in the clinical treatment of severe spinal deformity, and Halo gravity traction (HGT) has currently become the focus of the preoperative preparation and necessary treatment for severe spinal deformity. However, the correction effect that HGT can achieve is not clear at present, and some studies proposed that HGT itself could not increase the correction rate or significantly improve severe curves without surgical release. So, the use of HGT is still in dispute. Besides, no meta-analysis has been conducted to synthesize these data in the recent 5 years. Therefore, to evaluate the correction effect of HGT in severe spinal deformity, as well as the improvement of pulmonary function and nutritional status, a meta-analysis and systematic review was performed to evaluate the effect of HGT in the treatment of severe spinal deformity and provide information for clinical practice, which is the first meta-analysis to synthesize the data of nutritional status.

**Purpose:** This study sought to evaluate the complications and clinical outcomes in radiographic parameters, pulmonary function, and nutritional status of HGT in the treatment of severe spinal deformity.

**Methods:** Embase, PubMed, Cochrane, and Web of Science databases were searched comprehensively for relevant studies from inception to February 2021 by using combined text, and MeSH terms and English language restrictions were used. The data, including radiographic parameters, pulmonary function (forced vital capacity,

FVC%), and nutritional status (body mass index, BMI), was extracted from included studies. All meta-analyses were conducted using random or fixed effects models according to the between-study heterogeneity, which was estimated with  $I^2$ .

**Results:** A total of 446 studies were identified, and 12 studies with a total of 372 patients were included in this review. Compared with pre-traction values, there was a reduction in Cobb angle of 28.12° (95% confidence interval [CI], 22.18 to 34.18), a decrease in thoracic kyphosis of 26.76° (95% CI, 20.73 to 32.78), improvements in spine height (standardized mean difference=-0.89; 95% CI, -1.56 to -0.21), and in coronal balance (weighted mean difference [WMD]=-0.03; 95% CI, -1.56 to -0.21;  $p=0.84$ ) with preoperative HGT for severe spinal deformity patients. Besides, our pooled analysis showed an improvement in pulmonary function (FVC%) (WMD=-9.56; 95% CI, -1.56 to -0.21) and an increase in nutritional status (BMI) (WMD=-0.50; 95% CI, -1.56 to -0.21).

**Conclusions:** Partial correction can be achieved by preoperative HGT, thereby reducing the difficulty of the operation and the risk of neurologic injury caused by excessive correction. Moreover, preoperative HGT can improve pulmonary function and nutritional status and, thus, increase patients' tolerance to surgery.

747

## Diagnostic Accuracy of Motor Evoked Potentials to Detect Neurological Deficit during Scoliosis Correction: A Case Series in Bangladesh

Shah Alam

*Bangladesh Spine & Orthopedic Hospital, Dhaka, Bangladesh*

**Background:** A significant number of scoliosis need surgical intervention. Revolutionary design and capability of spinal instruments have drastically changed the principle of scoliosis correction. The use of intraoperative neurophysiological monitoring of spinal cord function has been shown to reduce the risk of motor deficit or paraplegia and is now standard and recommended by the Scoliosis Research Society and the American Academy of Neurology.

**Methods:** From February 2009 to July 2022, 161 cases underwent surgery; 93 were female and 68 were male;

and age ranged from 14–38 years. The pedicle is a power nucleus of the vertebra and offers a secure grip on all three columns. Pedicle screw instrumentation ensures rigid fixation with improved three-dimensional correction. Accurate placement of screws is important to reduce possible irreversible complications. All cases were corrected by transpedicular screws and rods, and one case was stabilized by sublaminar wiring. And 152 cases were managed by only the posterior approach and nine cases required both anterior releases, costoplasty, posterior stabilization as well. Fusion was done in selected segments. Total follow-up time was about 10 years (range, 6 months to 7 years). All patients were assessed by deformity correction, cosmesis, and functional outcome. The use of neuromonitoring is an excellent and effective method for the prevention of postoperative neurodeficit

**Results:** Seventy-one patients had an average coronal plane Cobb's angle measuring about 70° preoperatively and 17.12° immediate postoperative period. Eight patients (5%) developed neurodeficit. Three regained complete, but others regained their neurological deficit very slowly. There was malposition of screws in 21 (13.04%), painful prominence of screws in 17 (10.56%), and superficial infection in 7 (4.35%). And 80% of patients improved cosmetically. No neurodeficit was observed intraoperative and postoperative periods when intraoperative neuromonitoring was done.

**Conclusions:** Intraoperative neuromonitoring is a highly sensitive and specific test for predicting neurological deficits in patients undergoing corrective spinal surgery for scoliosis.

748

## Risk Factors of Early Revision Surgery for Adjacent Segment Disease in Comparison with Late Revision Surgery after Lumbar Fusion Surgery

Jeong-Seok Kim

*Department of Orthopaedic Surgery, Inha University Hospital, Incheon, South Korea*

**Introduction:** Adjacent segment disease (ASD) is a significant long-term complication after spinal fusion, requiring revision surgery. A previous study reported that the rate of revision surgery after multi-level lumbar fusion was

16.5% at 5 years after surgery. Although the rate of revision surgery for ASD increases as the follow-up period is increasing, some patients experienced revision surgery earlier than others.

**Purpose:** Our study is to evaluate the risk factors of early revision surgery compared to late revision surgery for ASD.

**Methods:** From January 2009 to January 2021, a total of 100 patients who underwent revision surgery for ASD were retrospectively reviewed. All surgeries were performed by the same surgeon. The patients were divided into two groups: early revision (within 5 years after primary surgery, n=26) and late revision (more than 5 years, n=74). Clinical and radiological data were evaluated and compared between the two groups. Exclusion criteria were non-degenerative spinal disorders such as trauma, tumor, and infection. Inclusion criteria were patients whose fusion level was limited to the lumbar spine, excluding fusion to the thoracic spine.

**Results:** The mean time to revision surgery was  $37.2 \pm 15.1$  months after primary surgery in the early group and  $182.4 \pm 20.5$  months in the late group. Postoperative lumbar lordosis (LL) after primary surgery was significantly different in the two groups, which was  $27.6^\circ \pm 14.9^\circ$  in the early group and  $38.1^\circ \pm 15.1^\circ$  in the late group ( $p=0.003$ ). Other radiological parameters including pelvic tilt, pelvic incidence (PI), PI-LL, sagittal vertical axis, proximal junctional kyphosis angle, the kyphotic angle at the revision area, and sacral slope showed no statistical differences between the early and late group. There was a statistical difference in bone mineral density (BMD) between the two groups ( $p=0.047$ ):  $-1.74 \pm 1.25$  in the early group and  $-1.05 \pm 1.53$  in the late group. There were no differences in the clinical parameters, including patients' age, sex, and body mass index.

**Conclusions:** Lower BMD and postoperative lower LL can be risk factors for early revision surgery for ASD. Restoration of LL is important to delay revision surgery for ASD.

753

## Clinical and Radiological Findings of Foraminal Disc Herniation

Jong-Won Kim

*Department of Orthopaedic Surgery, National Police Hospital, Seoul, South Korea*

**Introduction:** Whereas the caudal root is compressed in ordinary disc herniation, in foraminal disc herniation, the root compressed is the cephalad one. It is difficult to find reports of foraminal disc herniation in Korea; therefore, this situation has been regarded to be rare. Correct discrimination of compressed root is very important for proper decompression. This is a retrospective study about clinical features and diagnostic efficacy of clinical and radiological tools in foraminal disc herniation.

**Methods:** From February 2015 to January 2018, 102 discectomies were performed in Chungbuk National University Hospital, and From June 2020 to January 2022, 28 were in National Police Hospital. Among them, 20 (15%) were foraminal disc; three more patients were diagnosed with foraminal disc herniation, but they refused operative treatment. They were nine women and 14 men, and the mean age was 60.4 years. Medical records, simple X-rays, and magnetic resonance imaging (MRI) of each patient were reviewed. Findings of physical examination and MRI were carefully evaluated to document the diagnostic efficacy retrospectively. Each image of MRI was graded according to the author's 4 ranks of diagnostic efficacy. Clinical outcomes and postoperative complications were also investigated.

**Results:** Among the 23 patients, there were 12 cases of L4-5 foraminal disc herniations, five cases of L5-S1, and six cases of L3-4. Among the 12 cases of L4-5 cases, nine showed positive reverse straight leg raise (SLR) test. In the other three cases (25%), a reverse SLR test could not be done because of severe pain which made the prone position impossible. Knee jerk was diminished in all eight patients except four patients with bilateral hyporeflexia. Among various images of MRI, the body-cut axial image was the most effective diagnostic image compared to routine cut axial images which showed the least efficacy. Coronal images were are very helpful. Most cases achieved satisfactory clinical results.

**Conclusions:** Foraminal disc herniation seemed not to



be so rare. For an accurate diagnosis of this condition, a thorough physical evaluation to find out the compressed root seemed very important. And when this condition is suspected, MRI images of the body-cut axial and coronal image are strongly recommended.

---

**760**

## Hinged Roof Reconstruction of Anterior Iliac Crest after Harvesting Bicortical Strut Graft for Anterior Cervical Fusion

Myoung Yeol Shin

*Department of Orthopaedic Surgery, National Police Hospital, Seoul, South Korea*

**Introduction:** The strut iliac bone graft has been widely used to achieve fusion in various anterior cervical spinal surgeries but often remains some complications such as pain and gross deformity. Considering these, we designed a new technique to restore the iliac ridge utilizing the outmost part of the iliac crest. We aim to assess the efficacy of our new restoration technique of the iliac ridge after harvesting strut bone graft for anterior cervical fusion. Clinical and radiological outcomes of our hinged roof method were evaluated.

**Methods:** A retrospective review was done for 29 patients who underwent hinged roof reconstruction of the iliac ridge after harvesting a bicortical strut bone graft for anterior cervical fusion using a cervical plate system. The clinical outcome for pain and gross appearance and radiological results were evaluated.

**Results:** After 3 months after the operation, pain on the donor site became minimal or absent in all cases. At 1-year follow-up, no patient-reported pain and palpable discomfort such as step-off on the donor site. Final X-ray and follow-up computed tomography revealed incorporation of the reconstructed iliac ridge to both margins.

**Conclusions:** By showing good clinical and radiological outcomes, the authors' hinged roof reconstruction of the iliac crest after harvesting strut bone graft seemed to be a simple and effective technique that can reduce complications such as pain and deformity on the donor iliac crest.

---

**771**

## Relationships between Clinical Status and Gait Parameters in Ankylosing Spondylitis

Tae Sik Goh

*Department of Orthopaedic Surgery, Busan National University Hospital, Busan, South Korea*

**Introduction:** This study aimed to identify the relationship between gait parameters and health-related quality of life (HRQOL) in patients with ankylosing spondylitis (AS).

**Methods:** The study group comprised 134 patients with AS and 124 patients were enrolled as controls. All subjects underwent instrumented gait analysis and completed the clinical questionnaires. The kinematic parameters of gait were walking speed, step length, cadence, stance phase, single support, double support, phase coordination index (PCI), and gait asymmetry (GA). For each subject, a Visual Analog Scale (VAS: 0–10) score was used to assess the back pain, and a Short Form-36 (SF-36) questionnaire was administered to evaluate the HRQOL and Bath Ankylosing Spondylitis Disease Activity Index (BASDAI) was calculated. Using kinematic parameters and questionnaires, statistical analyses were done to reveal the significant differences between each group. Interrelationships of gait kinematic data and questionnaires of clinical outcome were also studied.

**Results:** Among the 134 patients with AS, 35 were women and 99 were men. In the control group, 40 were women and 84 were men. The patients in AS and control groups had significant differences in terms of walking speed, step length, single support, PCI, and GA. However, such differences were not observed in cadence, stance phase, and double support ( $p > 0.05$ ). In correlation analyses, gait kinematic parameters and clinical outcomes were significantly related to each other. To find out the predictive factors for clinical outcomes, multiple regression analysis was utilized. Walking speed was proved to predict VAS, and walking speed and step length were found to predict the BASDAI and SF-36 scores.

**Conclusions:** Patients with and without AS had significant differences in the gait parameters. Correlation analysis showed a significant correlation between the gait kinematic data and clinical outcomes. In particular, walking speed and step length were revealed to successfully predict the clinical outcomes in patients with AS.

780

## Primary Spinal Tumors Treated in a Tertiary Hospital in Nepal: Case Series

Rohit Pokharel

*Institute of Medicine, Tribhuvan University Teaching Hospital, Kathmandu, Nepal*

**Introduction:** Primary spinal tumors are rare neoplastic lesions. Its incidence varies among the reports because of differences in sample size and classification of the tumors. Irrespective of its type, the common presentation is features of the space-occupying lesion: distal neurological deficits, back pain, and radicular pain. A high index of suspicion and interpretation of relevant investigations are key for reaching to diagnosis. The purpose of the study was to find out the relative frequency of various primary spinal tumors presenting to our hospital, their management, and outcomes.

**Methods:** This is a retrospective study done at the Department of Orthopaedics and Trauma Surgery (Spine Unit), Tribhuvan University Teaching Hospital, Nepal over a period of 11 years from January 2010 to December 2020. All primary spinal tumor cases (with neurological deficits) operated on and have histopathological reports are included in the study. Primary bony tumors of the spine are excluded.

**Results:** A total of 76 patients with primary spinal tumors arising in the spinal canal encroaching the neural tissues were operated on. The patient's age ranged from 7 to 65 years with a mean of 49.5 years; there was slight male predominance (male-female ratio of 42:34=1.2:1). The anatomical location of the tumors was cervical (n=6), thoracic (n=29), thorocolumbar (n=21), and lumbo-sacral (n=20). There were 3 (3.9%) primary spinal extradural lymphomas. The majority 62 (81.6%) were intradural extramedullary (IDEM): Schwannoma (n=30), meningioma (n=18), neurofibroma (n=9), dermoid cysts (n=3), lipoma (n=1), and primary mesenchymal chondrosarcoma (n=1). Seven (9.2%) were intradural intramedullary; 5 (6.6%) were myxopapillary ependymomas and two astrocytomas; and four were dumbbell tumors (three neurofibromas and one Schwannoma). The mean follow-up was 16 months (range, 6 weeks to 60 months). All patients improved both neurologically and functionally after surgery except three. One elderly with conus medullaris ependymoma did not

improve; out of two cases with anteriorly located Schwannoma at T4–5 level, one developed incomplete neurology and another had complete neurological deficit after the surgery. One case of Schwannoma and two cases of ependymoma had a recurrence of the tumor after an average of 1.8 years of the index surgery and were re-operated.

**Conclusions:** Primary spinal canal tumors are uncommon lesions and should be one of the differentials of any spinal lesions. IDEM tumors are common with the highest frequency of Schwannoma followed by meningioma. Early diagnosis and total excision surgical intervention have a very good result.

820

## Clinical Results of Primary Sacral Tumors

Hitoshi Tonomura

*Department of Orthopaedics, Kyoto Prefectural University of Medicine, Kyoto, Japan*

**Introduction:** Primary sacral tumors are rare lesions and their oncological prognosis is poor. Sacral neuroanatomy increases difficulties in neurological function in patients with sacral tumors. Their management is determined by multiple factors, including the pathology, extent of the disease, and presentation of neurological symptoms. Optimal decision-making is essential to obtain the best outcome in terms of maximizing disease control while attempting to minimize neurological dysfunction.

**Purpose:** Our study presents the results of a group of patients with primary sacral tumors who were treated by the same multidisciplinary team at our institution.

**Methods:** Between 2013 and 2020, 15 patients with primary sacral tumors (10 men and five women) were treated. The mean age was 53 years, and the mean follow-up period was 39 months. The diagnosis included chordoma in four patients, Ewing's sarcoma and plasma cell tumor in two patients each, and osteosarcoma, chondrosarcoma, fibrosarcoma, malignant peripheral nerve sheath tumor (MPNST), malignant germ cell tumor, osteoid osteoma, and giant cell tumor in one patient each. The lesion site of each tumor was classified into 1 of 4 types [3]. Type 1 had its upper extent at S3, type 2 had its upper extent at S2, type 3 had its upper extent at S1, and type 4 extended to the iliac bone. We evaluated the outcome in terms of local disease control and residual neurological dysfunction.

**Results:** All cases of chordoma were administered irradiation including carbon-ion radiotherapy regardless of the extent of the disease, cases of type 2 and 3 plasma cell tumors were administered radiation treatment, and the case of type 4 giant cell tumor was administered denosumab. Local recurrence occurred and bladder dysfunction appeared in one case of chordoma. The other cases did not present neurological dysfunction; all patients lived despite the disease. Four cases of osteosarcoma, chondrosarcoma, fibrosarcoma, and MPNST were classified as type 3 or 4 and were administered chemotherapy and irradiation without surgery. All these cases presented loss of bladder and bowel control; all patients died due to the disease. Two cases of Ewing's sarcoma and 1 case of malignant germ cell tumor were classified as type 1 or 2 and underwent partial sacrectomy after preoperative chemotherapy. A partial sacrectomy was performed at the S2–3 level via bilateral S-2 and unilateral S-3 nerve preservation. Local recurrence occurred in one of Ewing's sarcomas. This case presented loss of bladder and bowel control; the patient died due to the disease. The remaining two cases were continuously disease-free and showed no worsening of neurological function.

**Conclusions:** Radiotherapy and denosumab treatment were useful in obtaining sufficient local control of sacral tumors depending on the histopathology. Partial sacrectomy with preservation of the unilateral S-3 nerve may prove beneficial in providing certainty of retaining neurological functions such as bladder and bowel control. This surgery gives the best chance of disease management and should be the surgery of choice for all malignant primary sacral tumors involving lower segments.

823

## Analysis of Risk Factors Associated with Proximal Junctional Kyphosis Following Long-Instrumented Fusion from L1 to Sacrum

Joonghyun Ahn

*Department of Orthopaedic Surgery, Bucheon St. Mary's Hospital, Bucheon, South Korea*

**Introduction:** There have been consistently opposing reports regarding the selection of the uppermost instrumented vertebra (UIV) at a thoracolumbar junction

in long spinal fusion. However, some recent literature claimed thoracolumbar junction could be considered selectively as UIV for long spinal fusion without certain potential risk factors. There has been a paucity of studies investigating the risk factors associated with proximal junctional kyphosis (PJK) following long-instrumented spinal fusion from L1 to the sacrum.

**Purpose:** This study aimed to investigate the incidence and risk factors of PJK following spinal instrumented fusion from L1 to the sacrum in patients with mild to moderate sagittal imbalance.

**Methods:** This retrospective study recruited consecutive patients undergone instrumented fusion from L1 to the sacrum for degenerative lumbar disease between June 2006 and November 2019 in a single institution. Inclusion criteria were as follows: (1) etiology of spinal stenosis, spondylolisthesis, or adjacent segment disease following previous spinal fusion; (2) completion of a long-segment spinal instrumented fusion surgery from L1 vertebra to the sacrum; and (3) with a minimum follow-up period of 2 years. Exclusion criteria were as follows: (1) C7 sagittal vertical axis more than 15 cm; (2) history of pedicle subtraction osteotomy or other equivalent procedures; and (3) early postoperative (within 1 year) complications requiring revision for index surgery. The patients' preoperative clinical data, muscle status at T12–L1 on magnetic resonance images, and sagittal spinopelvic parameters on radiographs at preoperative, immediate postoperative, and regular postoperative visits were collected and analyzed. PJK was defined if the postoperative proximal junctional angle (made by T11 upper endplate and L1 lower endplate) was  $>20^\circ$  or increased more than  $10^\circ$  compared to the baseline. Univariate analysis was used to compare clinical and radiographic data between PJK and non-PJK patients. Logistic regression analysis was used to investigate the independent risk factors for PJK.

**Results:** A total of 41 patients were included in the study cohort. The mean age at surgery was 67.3 years and the mean follow-up period was 37.3 months. Seven were male and 34 were female. PJK developed in 17 (41.5%) out of 41; of these patients, 15 (88.2%) developed PJK within postoperative 1 year. On univariate analysis between PJK and non-PJK patients, the PJK group showed more frequent osteoporosis, lower body mass index, smaller cross-sectional area, and more fat infiltration (FI) in erector spinae muscle at T12–L1, larger preoperative TLK and PT with statistical significance ( $p < 0.05$ ). On logistic regres-

sion analysis, severe (>50%) FI in erector spinae muscle (odds ratio [OR], 43.60; 95% confidence interval [CI], 4.10–463.06;  $R^2_{N=0.730}$ ,  $p=0.002$ ) and osteoporosis (OR, 20.49; 95% CI, 1.58–264.99;  $R^2_{N=0.730}$ ,  $p=0.021$ ) were statistically significant.

**Conclusions:** In a review of minimum 2 years, most (88.2%) of PJK developed within postoperative 1 year. Preexisting severe (>50%) fat infiltration in erector spinae muscle and osteoporosis were significant independent risk factors associated with PJK following instrumented fusion from L1 to the sacrum. To avoid the early-onset PJK, consideration of these factors is important before planning long-instrumented spinal fusion from L1 to the sacrum for patients with the degenerative lumbar disease.

---

**826**

## Anterior Cervical Debridement and Fusion for Cervical Pyogenic Spondylodiscitis: Is Use of Anterior Cervical Plating Possible?

Sung Kyu Kim

*Department of Orthopaedic Surgery, Chonnam National University Medical School and Hospital, Gwangju, South Korea*

**Introduction:** Due to concerns about bacterial seeding on the foreign material after instrumentations in pyogenic infections, the safety and efficacy of anterior cervical plating for cervical pyogenic spondylodiscitis (CPS) are still undetermined and controversial. Little information is available about the safety and efficacy of anterior cervical plating to manage CPS. We sought to evaluate the safety and efficacy of anterior cervical plating in anterior cervical debridement and fusion (ACDF) for patients with CPS.

**Methods:** Twenty-three patients who underwent ACDF with (n=12) or without (n=11) plating for CPS were included. The mean age was 62.6 years. Medical records were reviewed and radiological parameters including segmental height, segmental angle, C2–C7 angle, and fusion status were analyzed. The mean follow-up period after surgery was 21.3 months.

**Results:** After ACDF with plating, segmental height, segmental angle, and C2–C7 angle were significantly improved compared with preoperative conditions and remained well-maintained at the last follow-up. After ACDF without plating, three radiological parameters were also initially improved compared with the preoperative condi-

tion, but significantly deteriorated to preoperative levels at the time of the last follow-up. The fusion rate was higher in the ACDF with the plating group compared with the ACDF without the plating group (90.9% vs. 63.6%,  $p<0.01$ ). One patient who received ACDF with plating and four patients who received ACDF without plating underwent revision surgery due to nonunion or bone graft dislodgement. No recurrence of pyogenic spondylodiscitis occurred in either group.

**Conclusions:** ACDF with plating showed better surgical outcomes compared with ACDF without plating for CPS. We recommend the use of anterior cervical plating, which can provide biomechanical stability, for better healing of CPS. To our knowledge, this is the largest surgical case series of CPS.

---

**938**

## Incidence and Risk Factors of Central Venous Catheter-Related Thrombosis after Scoliosis Correction Surgery

Zhipeng Tu

*Department of Orthopaedic Surgery, First Affiliated Hospital, Air Force Medical University, Xi'an, China*

**Introduction:** Patients undergoing scoliosis correction surgery may benefit from central venous access to provide intraoperative monitoring and fluid resuscitation, as well as suffer from central venous catheter-related thrombosis. The short-term incidence and risk factors of central venous catheter-related thrombosis after scoliosis correction surgery remain unknown.

**Purpose:** To study the incidence of thrombosis and its influencing factors after intraoperative deep vein catheterization in patients with scoliosis.

**Methods:** A retrospective analysis was made of patients in our group who were admitted to the hospital from October 2017 to October 2020 and underwent correction surgery for scoliosis and underwent deep vein catheterization during the operation. According to the inclusion and exclusion criteria, a total of 64 cases were included. The parameters included in the study were: gender, age, osteotomy or not, intraoperative blood loss, and indwelling time of deep venous catheter. Outcomes were classified as no thrombus, vessel wall roughness, and mural thrombus, based on the report of ultrasound before deep vein cath-

eter removal. The data were analyzed to compare the differences in various parameters in patients with different outcomes, and to evaluate the incidence and influencing factors of thrombosis.

**Results:** When the deep vein catheter was removed, 54.7% of the patients had no thrombus, 18.8% of the patients had rough vessel walls, and 26.6% of the patients had mural thrombus. There was no significant difference in the gender distribution and age distribution of the patients in the no thrombus group, the rough vessel wall group, and the mural thrombus group. There was a significant difference in operation time among the groups ( $p < 0.05$ ). The mean operation time of the mural thrombus group was  $452 \pm 113$  minutes, the operation time of the rough vessel wall group was  $399 \pm 183$  minutes, and the operation time of the non-thrombotic group was  $305 \pm 123$  minutes. There were no significant differences between the groups in terms of intraoperative osteotomy and intraoperative blood loss. There were differences in the catheterization time among the groups. The catheterization time of the non-thrombotic group was  $1.2 \pm 0.5$  days, the catheterization time of the rough vessel wall group was  $1.3 \pm 0.49$  days, and the catheterization time of the wall thrombus group was  $1.9 \pm 1.6$  days, but the difference was not statistically significant ( $p = 0.13$ ).

**Conclusions:** The incidence of mural thrombosis in patients with scoliosis after intraoperative deep vein catheterization was 26.6%. Thrombosis was not related to the patient's gender, age, intraoperative blood loss, and whether or not to undergo osteotomy, but was positively related to the duration of surgery. Deep vein thrombosis indwelling time may be positively correlated with thrombosis, and further research is needed.

953

## Trends And Strategies of Proximal Junctional Failure after Spinal Reconstruction Surgery for Adult Spinal Deformity in Our Institution

Shinya Nakagawa

Takamatsu Red Cross Hospital, Takamatsu, Japan

**Introduction:** Kyphosis of the proximal end after spinal reconstruction in adult spinal deformity may cause back pain and/or neurological deficiency. In this study, we investigated the tendency and strategies of proximal junc-

tional failure (PJF) after spinal reconstruction including the pelvis performed for adults with spinal deformity at Takamatsu Red Cross Hospital.

**Methods:** Between 2012 and 2020, 36 patients who underwent spinal reconstruction including the pelvis at our hospital were compared using pre- and post-surgical X-ray images of the whole spine. PJF was defined as an angle of  $10^\circ$  or more between the caudal endplate of the upper instrumented vertebra (UIV) and the cranial endplate of the two superior vertebrae than the UIV, and the degrees increased more than  $10^\circ$  after surgery. The incidence of PJF and sagittal parameters of adult spinal deformity at the plane radiograph were investigated. We also investigated the relevance of PJF to 30 cases in which young adult mean (YAM) values were measured.

**Results:** PJF was observed in 15 cases (41.7%; three males, 12 females). The average YAM (%) was  $77.9 \pm 9.4$  in the PJF group and  $68.9 \pm 14.0$  in the non-PJF group. The average number of fusions of intervertebral spaces was  $10.3 \pm 1.7$  in the PJF group and  $11.6 \pm 2.3$  in the non-PJF group. There was no significant difference in the above results. Three patients (8%) underwent PJF who complained of muscle weakness in the early postoperative period.

**Conclusions:** The incidence of PJF in adult spinal deformity surgery is 17%–39% within 2 years after surgery, of which 15%–55% require reoperation. However, the number of cases in this study was small, and no significant difference was found between the two groups. It has been reported that administration of teriparatide before surgery and reinforcement of the proximal end of fixation with polyethylene tape are effective for the prevention of PJF. Three cases of PJF were caused by anterior slippage associated with fractures of the fixed superior vertebrae. In recent cases, we attempted to prevent slippage by fastening the UIV+1 and UIV+2 vertebral arches and the superior end of the implant with polyethylene tape.

954

## Influence of Pelvic Parameter on Postoperative Spinal Alignment in Adolescent Idiopathic Scoliosis Lenke Type 5 Patient

Takahiro Kitagawa

Department of Orthopaedic Surgery, Keio University School of Medicine, Tokyo, Japan

**Introduction:** Previous studies for adolescent idiopathic scoliosis (AIS) mainly focused on coronal alignment and only few studies have been discussed about sagittal alignment. Thus, the treatment strategy for AIS is considered based on the coronal curvature and the influence of sagittal parameters on the surgical outcome has not been clarified. In the present study, we divided AIS Lenke type 5 patients by pelvic sagittal parameter and evaluated the difference in spinal alignment before and after the surgical correction.

**Methods:** A total of 69 AIS Lenke type 5 patients, who received posterior correction surgery from 2013 and followed up for 2 years, were included. Patients were divided into two groups by pelvic incidence (PI >45°, high-PI group; PI <45°, low-PI group). Pre- and postoperative spinal alignments were measured and compared for the two groups. Additionally, the occurrence of postoperative hyper thoracic kyphosis (hyper-TK, thoracic kyphosis >40°) was compared between the two groups.

**Results:** Preoperative coronal alignment was similar between the high-PI group and the low-PI group. Meanwhile, TK and thoracolumbar kyphosis (TLK) were significantly smaller in the high-PI group compared with the low-PI group (preoperative TK: high-PI group, 16.4°±7.1° vs. low-PI group, 22.2°±10.6°;  $p<0.01$ ; preoperative TLK: high-PI group, 2.3°±9.0° vs. low-PI group, 12.3°±6.6°;  $p<0.01$ ). This indicated that the high-PI group tended to show a flat back, whereas the low-PI group show kyphotic alignment above the thoracolumbar region. Postoperative coronal alignment did not differ between the two groups. In contrast, parameters of sagittal alignment showed a significant difference between the two groups. The kyphotic change by correction was observed at the thoracic area in both groups (postoperative TK: high-PI group, 20.3°±7.8° vs. low-PI group, 28.9°±8.9°;  $p<0.01$ ). The rate of hyper-TK was significantly higher in the low-PI group (high PI group, 0% vs. low-PI group, 15.2%;  $p=0.015$ ).

**Conclusions:** The pelvic parameter was related to sagittal alignment in AIS Lenke type 5 patients. Low-PI patients tend to have kyphotic alignment before surgery compared with high-PI patients and showed a risk to result in a hyper-TK after the posterior correction surgery.

970

## Postoperative Progression of Thoracic Kyphosis at the Fusion Level Can Influence the Surgical Outcome after Posterior Decompression and Fusion for Patients with Thoracic Ossification of the Longitudinal Ligament

Hiroshi Takahashi

University of Tsukuba, Tsukuba, Japan

**Introduction:** Posterior decompression with instrumented fusion (PDF) surgery has been reported as a relatively safe and feasible surgical procedure for patients with thoracic myelopathy due to ossification of the longitudinal ligament (T-OPLL). However, the influence of postoperative sagittal alignment on the surgical outcome, including the change in thoracic kyphosis, remains unclear.

**Purpose:** This retrospective observational study investigated the relationship between the postoperative change in thoracic kyphosis and surgical outcomes after PDF surgery for patients with T-OPLL.

**Methods:** From 2014 to 2020, 18 consecutive patients who underwent posterior instrumented decompression and fusion surgery for thoracic OPLL at our hospital were included in this study. Intraoperative intentional correction of kyphosis was not performed in all patients. The thoracic kyphotic angle over the range of fusion levels and the kyphotic angle at the maximum spinal cord compression level were measured using computed tomographic sagittal reconstruction before surgery, 1 week after surgery, and 1 year after surgery. The relationship between the radiographic parameters and recovery based on the Japanese Orthopaedic Association (JOA) score was investigated. Patients were divided into two groups: the K group in which the kyphotic angle over the range of fusion levels progressed >5° between 1 week and 1 year postoperatively (5 patients), and the M group in which the kyphotic angle over the range of fusion levels progressed <5° between 1

week and 1 year postoperatively (13 patients). The recovery rate based on the JOA score in the two groups was compared.

**Results:** The body mass index of the entire sample was  $32.3 \pm 7.1$  kg/m<sup>2</sup>, indicating obesity. The number of fusion levels was  $8.4 \pm 2.4$ . The thoracic kyphotic angle over the range of fusion levels was  $22.5^\circ \pm 10.4^\circ$  before surgery,  $27.5^\circ \pm 10.1^\circ$  1 week after surgery, and  $30.1^\circ \pm 8.6^\circ$  1 year after surgery. The angle at the maximum spinal cord compression level was  $7.49 \pm 4.2$  before surgery,  $7.99 \pm 4.3$  1 week after surgery, and  $7.75 \pm 4.3$  1 year after surgery. Gradual progression of the kyphotic angle over the range of fusion levels occurred despite relative maintenance of the angle at the site of maximum compression for 1 year postoperatively. The recovery rate based on the JOA score 1 year after surgery was  $49.0 \pm 18.5$  in the K group and  $79.5 \pm 18.1$  in the M group which showed significantly poor neurological recovery in the K group ( $p=0.021$ ).

**Conclusions:** In PDF for patients with T-OPLL, the progression of postoperative thoracic kyphosis over the range of fusion levels for 1 year postoperatively resulted in poor neurological recovery.

---

988

## Finite Element Analysis of Three Kinds of Pedicle Screw Designs

Bin Ye

*Department of Orthopedics, Xijing Hospital, Air Force Medical University of PLA, Xi'an, China*

**Introduction:** Posterior pedicle screw fixation is the most common surgery for thoracolumbar (TL) fractures, including three main types of pedicle screws, such as mono-planar pedicle screw (MPPS), polyaxial pedicle screw (PAPS), and fixed-axis pedicle screw (FAPS). However, most biomechanical experiments of the three screws are only analyzed on animal models or machines to compare the biomechanical stability but the stress distribution patterns were not elucidated. The aim of this study was to compare the stress distribution difference among three kinds of pedicle screws.

**Methods:** A TL spine (T11–L3) finite element model (FEM) was established with L1 simulated as fractured vertebrae, and MPPS, PAPS, or FAPS were bilaterally inserted in T12 and L2 pedicles. The redistributed range

of motions (ROMs) of T12–L2, the von Mises stress of instrumentation, adjacent intervertebral discs, and fractured vertebrae were measured and compared among different fixation models during simulated spinal movement.

**Results:** In any direction of motion, the ROM of MPPS and FAPS models were smaller than that of PAPS. The maximum values of von Mises stress of instruments and adjacent intervertebral discs in MPPS and FAPS models were higher than those in PAPS model, respectively. However, the maximum values of von Mises stress of fractured vertebral body of MPPS model and FAPS model were lower.

**Conclusions:** This study developed models to simulate stable TL burst fractures. Compared with PAPS, the finite element results of MPPS were more similar to those of FAPS, especially in the sagittal plane. MPPS provided greater mechanical stiffness than PAPS in the FEM.

---

991

## Benefit of the 360-Degree Stabilization in Oncological Spine Cases: A Matched Pair Analysis

Maximilian-Niklas Bonk

*Department For Neurosurgery, University Hospital Augsburg, Augsburg, Germany*

**Introduction:** Spinal metastases may present with different degrees of mechanical instability. The Spinal Instability Neoplastic Score (SINS) was developed to assess spinal neoplastic-related instability. This study aimed to compare the quality of life and the overall survival between patients following surgical instrumentation and radiotherapy and radiotherapy alone for spinal metastases.

**Methods:** This study aimed to compare the quality of life and the overall survival between patients following surgical instrumentation and radiotherapy and radiotherapy alone for spinal metastases. The study design was a matched-pair analysis according to the SINS, the sex, the age, the histology, and the “Karnofsky Performance Index.”

**Results:** Thirty-five patients per group were identified. The median age was  $66 \pm 14$  years and 60% were female. The most common histology was breast cancer and was seen in 38% followed by bronchial cancer in 14% of cases. Unstable and potentially unstable fractures were seen in

74% and 26%, respectively. The overall survival was 57% and 75% in the radiotherapy and the surgery and radiotherapy groups, respectively. Analyzing the quality of life, we choose walking ability as a main feature. Ninety-two percent in the interventional group are still able to walk, in contrast to 80% in the conservative group ( $p=0.24$ ).

**Conclusions:** Tailored surgical approach according to the SINS score results in longer overall survival and higher rates of preservation of walking ability in patients with spinal metastases.

997

## Long-term Clinical and Radiographical Results of Posterior Instrumentation Surgery for Pediatric Patient with Atlantoaxial Dislocation

Kota Watanabe

*Department of Orthopedic Surgery, Keio University School of Medicine, Tokyo, Japan*

**Introduction:** Although many pediatric patients with atlantoaxial subluxation (AAS) are treated with posterior instrumentation and fusion because of paralysis or radiographical abnormalities, the long-term outcome of the treatment is still unclear.

**Methods:** Twenty-three cases (nine boys and 14 girls) underwent posterior instrumentation and fusion for AAS under 18 years at the time of surgery and were followed up for more than 10 years were included. The mean age at surgery was 9.8 years (range, 2–16 years), and the mean follow-up was 12.8 years (range, 10.8–19 years). The treatment strategy was C1 lateral mass screw (LMS)+C2 pedicle screw (PS; vertebral root screw) fixation if the patient was large enough to have C1 LMS and C2 PS placed (five cases), Magerl+Brooks procedure if the patient was smaller (five cases), and Magerl+posterior bone grafting was used (10 cases) if there was no space between the C1 posterior arch and the C2 vertebral arch. When placement of implants in C1 was difficult, occipital fixation (C0–3 fixation, 1 case; C0–2 fixation, 2 cases) was used.

**Results:** Bone fusion was achieved in all cases. Perioperatively, there was one case of postoperative pneumonia, one case of tracheotomy, one case of postoperative infection, and one case of vertebral artery injury. Two patients (2 and 3 years old) had implant dislocation and required

revision surgery. Three patients had C2/3 spontaneous fusion, and one patient who underwent revision surgery had bony fusion to C0–5. The mean range of motion at the final follow-up was 46° (30°–68°). Eleven patients had preoperative motor deficits in the upper and lower extremities. Except for two patients with preoperative tetraplegia, all patients had improved upper and lower extremity function at the last follow-up, and none of them had obvious activities of daily living impairment. There was one death at 12 years postoperatively.

**Conclusions:** Although there were correction loss and implant failures in patients under 3 years of age, the range of motion was well maintained. The long-term prognosis of posterior instrumentation surgery for pediatric patients with subluxation of the atlantoaxial vertebrae was generally good.

1050

## 15-Year Survivorship Analysis of an Interspinous Device in Surgery for Single-Level Lumbar Disc Herniation

Jong-Beom Park

*Department of Orthopaedic Surgery, College of Medicine, The Catholic University of Korea, Seoul, South Korea*

**Introduction:** Lumbar disc herniation (LDH) is the most common cause of surgery for degenerative lumbar diseases. Despite the development of various surgical techniques for LDH, postoperative recurrence is an unavoidable complication and often requires reoperation. The reoperation rate can vary greatly depending on surgical techniques. Interspinous devices have been introduced as alternatives to decompression or fusion in surgery for degenerative lumbar diseases. In addition, promising results of biomechanical testing for interspinous device as a concept of dynamic stabilization have been reported. The Device for Intervertebral Assisted Motion (DIAM) is a relatively new interspinous device and restricts segmental motion, such as extension and flexion, but allows a full range of axial rotation and lateral bending at the level of implantation. Therefore, promising results of biomechanical testing for DIAM as a concept of dynamic stabilization have been reported. However, detailed biomechanical testing to predict DIAM survival for at least 10 years of *in vivo* use has not been performed. This study aimed to investigate



15-year survivorship and risk factors for reoperation of a DIAM in surgery for 1-level LDH.

**Methods:** A total of 94 patients (54 men and 40 women) underwent discectomy and DIAM implantation for 1-level LDH, with a mean follow-up of 12.9 years (range, 6.3–15.3 years). The mean age was 46.2 years (range, 21–65 years). Sixty-two patients underwent DIAM implantation for L4-5, 27 for L5-6, and 5 for L3-4. Reoperations due to any reason associated with DIAM implantation level or adjacent levels were defined as failure and used as the end point of determining survivorship.

**Results:** During the 15-year follow-up, eight patients (four men and four women) underwent reoperation due to recurrence of LDH at the DIAM implantation level, with a reoperation rate of 8.5%. The mean time to reoperation was 6.5 years (range, 0.8–13.9 years). Kaplan-Meier analysis showed a cumulative survival rate of the DIAM implantation of 97% at 5 years, 93% at 10 years, and 92% at 15 years after surgery; the cumulative reoperation rate of the DIAM implantation was 3% at 5 years, 7% at 10 years, and 8% at 15 years after surgery. The mean survival time was predicted to be 14.5 years (95% confidence interval, 13.97–15.07). The log-rank test and Cox proportional hazard model showed that age, sex, and location did not significantly affect the reoperation rate of DIAM implantation.

**Conclusions:** Our results showed that DIAM implantation significantly decreased the reoperation rate for LDH in the 15-year survivorship analysis. We suggest that DIAM implantation could be considered a useful intermediate-step procedure for LDH surgery. To the best of our knowledge, this is the longest follow-up study in which surgical outcomes of interspinous device surgery were reported.

1057

## Resurgence of Role of Computed Tomography Myelogram in the Era of Magnetic Resonance Imaging for Surgical Decision Making of Lumbar Degenerative Disc Disorder

Keyur Akbari

*Apollo Hospital, Chennai, India*

**Introduction:** Since the introduction of magnetic resonance imaging (MRI) into clinical practice in the mid-1980s, the role of computed tomography myelography

(CTM) becomes less important in spinal diagnostics but it remains a method that is probably even superior to MRI for special clinical issues. The study aims to ascertain the role of CTM as an adjunct to MRI in surgical decision-making for degenerative lumbar disc disorders.

**Methods:** Twenty patients who presented with the symptomatic lumbar degenerative disorder but with MRI findings that did not correlate with the clinical features were included. These patients underwent CTM as an additional imaging technique to aid preoperative surgical decision-making. Both imaging modalities were compared for the identification of the impinging pathology as well as the number of levels of compression.

**Results:** MRI revealed compression/impingement at 38 levels whereas CTM revealed 29 levels. Eighteen out of 20 patients underwent surgery and a total of 29 levels were decompressed as localized in the CTM. The Visual Analog Scale for back pain and leg pain at baseline were  $6 \pm 0.7$  and  $7 \pm 0.4$  and at 6 months post-intervention (surgical/conservative) were  $2 \pm 0.8$  and  $0.3 \pm 0.1$ , respectively. Oswestry Disability Index at baseline and 6 months post-intervention was  $56 \pm 6.9$  and  $18 \pm 4.2$ , respectively ( $p < 0.0001$ ). There was agreement on the number of levels between MRI and CTM in 10 cases (50%). MRI overestimated the number of involved levels in nine cases (45%) whereas, in the remaining one case (5%), MRI underestimated the number of involved levels. The weighted kappa value for agreement between MRI and CTM on the number of levels involved in necessitating decompression was 0.4 (95% confidence interval, 0.18 to 0.77;  $p = 0.0009$ ).

**Conclusions:** CTM is a crucial supplemental study to formulate an effective management plan in cases where MRI correlates with the clinical findings and shows a multilevel involvement to reduce postoperative morbidity.

1066

## Efficacy, Safety, and Reliability of Surgery on the Lumbar Spine under General versus Spinal Anesthesia: An Analysis of 64 Cases

Sharif Ahmed Jonayed

*National Institute of Traumatology & Orthopaedic Rehabilitation (NITOR), Dhaka, Bangladesh*

**Introduction:** Surgery on the lumbar spine is the commonest surgical procedure among all spinal surgical practices.

Both general anesthesia (GA) and spinal anesthesia (SA) are shown to be suitable techniques for performing surgery safely. GA is used most frequently. But SA became increasingly more popular because it allows the patient to self-position thereby reducing various complications associated with GA in a prone position. The purpose of this quasi-experimental study was to compare intra- and postoperative parameters, surgeons' satisfaction, and cost-effectiveness between GA and SA on patients undergoing surgery in the lumbar spine.

**Methods:** A total of 64 patients from June 2016 to July 2019 who underwent either discectomy, laminectomy, or lamino-foraminotomy for herniated lumbar disc or canal stenosis in 1 or 2 levels were included. During the study period, 32 patients were non-randomly selected for each of the GA and SA groups. The heart rate (HR), mean arterial pressure (MAP), blood loss, total anesthetic time, surgeons' satisfaction, analgesic requirements, cost of the procedure, and hospital stay were recorded and compared.

**Results:** In the context of demographic characteristics, baseline HR, or MAP, no significant differences were noted between SA and GA groups. Mean anesthetic time, mean post-anesthesia care unit time, mean doses of analgesic requirement, cost of anesthesia, and the surgeon's satisfaction were significantly lower in the SA group ( $p < 0.05$ ). The blood loss, duration of operation, and hospital stay were not significant too. No major intra- and postoperative complications were reported nor were significant differences found in either series.

**Conclusions:** The safety and efficacy of SA in comparison to GA were similar for patients undergoing surgery on the lumbar spine. Notable advantages of SA include shorter anesthesia duration, fewer drug requirements, relative cost-effectiveness, and fewer complications rate. Successful surgery can be performed using either anesthesia type.

1067

## Single Stage Posterior Vertebral Column Resection for the Correction of Rigid and Severe Kyphotic Deformity: An Analysis of 22 Cases

Sharif Ahmed Jonayed

*National Institute of Traumatology & Orthopaedic Rehabilitation (NITOR), Dhaka, Bangladesh*

**Introduction:** Treatment of a severe and rigid spinal deformity due to any cause is always challenging for the treating spine surgeon. Nevertheless, vertebral column resection (VCR) has evolved over the past century to become a viable last resort for the correction of the most challenging spinal deformities through a single, posterior approach. The hypothesis of this study is that single-stage posterior vertebral column resection (PVCR) is insufficient to correct the rigid and severe kyphotic deformity.

**Methods:** This is a prospective case series of 22 patients either with a severe (Cobb angle  $> 60^\circ$ ) or rigid kyphotic deformity who underwent treatment for correction of deformity by a single-stage PVCR from July 2016 to September 2019.

**Results:** The mean age of the patient was 30.2 years with a mean follow-up time of 27 months. The average operating time was 420 minutes (range, 320–760 minutes). Overall final postoperative kyphotic Cobb angles correction ranged from  $30.4^\circ$  to  $55.9^\circ$ . Oswestry Disability Index improved from  $58.6 \pm 6.5$  to  $10.5 \pm 3.2$ . Visual Analog Scale was improved from  $6.7 \pm 0.5$  to  $1.7 \pm 0.8$ . Neurologic recovery was noted in seven patients. Most frequent complications observed in our series were massive blood loss with a mean of 740 mL (range, 560–1,380 mL), dural tear (8%), thoracic root pain (4%), and neurological deterioration (four cases: three transient and one late onset). The mean recovery period for neurological recovery was 3 months. Surgical site infection rates range from 2.9% to 3.7%.

**Conclusions:** Although the PVCR is highly technically demanding, exhaustingly lengthy, and associated with a variety of complications but can be performed safely with proper training and patience for correcting severe and rigid spinal deformity for a satisfactory outcome. Single-stage PVCR is an effective method for correcting the rigid and severe kyphotic deformity.

1068

## Efficacy, Safety, and Reliability of Using Single Anterior Approach for Subaxial Cervical Spine Dislocation

Sharif Ahmed Jonayed

*National Institute of Traumatology & Orthopaedic Rehabilitation (NITOR), Dhaka, Bangladesh*

**Introduction:** Though there is a controversy regarding the best treatment modality for cervical spine dislocation (CSD), anterior cervical surgery is gaining popularity with relatively a better outcome than any other method.

**Purpose:** This prospective case series aims to evaluate the efficacy, safety, and reliability of the anterior approach as a single maneuver for the treatment of subaxial CSD.

**Methods:** Patients with subaxial CSD undergone for surgical stabilization by using a single anterior approach were included. Most of the CSD were reduced and treated by anterior cervical discectomy and fusion. Unreduced dislocations were treated by anterior cervical corpectomy and fusion. The neurological status and radiological and functional outcomes were measured. IBM SPSS ver. 25.0 was used for statistical analysis.

**Results:** The total number of the operated case was 64 with a mean follow-up period of  $42 \pm 8$  months. The mean age was  $34.50 \pm 11.92$  years. The most common level of injury was C5/C6 (57.8%). The reduction was achieved in 92.2% of cases, and only 7.8% of cases needed a corpectomy. However, the state of anatomical reduction and accurate imaging measures did not correlate significantly to self-reported outcome measures. The mean operative time was  $97.6 \pm 19.2$  minutes with a mean blood loss was  $112.2 \pm 25.3$  mL. All cases except American Spinal Cord Injury Association Impairment Scale-A were improved neurologically (87.63%). The mean Neck Disability Index was  $9 \pm 8.34$  and the preoperative mean Visual Analog Scale was improved to  $2.05 \pm 0.98$  ( $p < 0.005$ ) at the last follow-up. Fusion was achieved in all cases. Transient dysphagia (23.4%) was the most common complication. None of the patients had worsening of neurological deficits.

**Conclusion:** The single anterior approach is a relatively easy, safe, and effective method for the treatment of the subaxial CSD with a good radiological, neurological, and functional outcome.

1070

## Efficacy, Safety, and Reliability of High versus Low Dosages form of Tranexamic Acid Used in Adolescent Idiopathic Scoliosis Surgery

Sharif Ahmed Jonayed

*National Institute of Traumatology & Orthopaedic Rehabilitation (NITOR), Dhaka, Bangladesh*

**Introduction:** Tranexamic acid (TXA) is a synthetic lysine-analog antifibrinolytic agent that is used for the reduction of intraoperative blood loss. Its routine use in adolescent idiopathic scoliosis (AIS) surgery has already been documented. However, the dosing regimens vary widely, and the optimal dose has not been yet established.

**Purpose:** This study aimed to quantify blood loss and transfusion requirements for high-dose and low-dose TXA dosing regimens in pediatric patients undergoing spinal fusion for correction of idiopathic scoliosis.

**Methods:** It was a quasi-experimental study in which of 92 patients of AIS from July 2015 to June 2020 were included. Patients were selected by purposive sampling and allocated into two equal groups ( $n=46$ ). Group A (high dose) received 50 mg/kg of TXA administered over 30 minutes before skin incision and continued at the rate of 5 mg/kg/hr until the end of the procedure and group B (low dose) received 10 mg/kg of TXA over 30 minutes before skin incision and continued at the rate of 1 mg/kg/hr until the end of the procedure. Estimated blood loss and transfusion requirements were compared between the two-dosing group.

**Results:** Patient characteristics were nearly identical between the two groups. Compared with the low-dose TXA group, the high-dose TXA group had decreased estimated blood loss (540 mL vs. 875 mL,  $p=0.01$ ), and a decrease in both intraoperative (0.2 vs. 0.8 units,  $p=0.01$ ) and whole hospitalization (0.3 vs. 1.0 units,  $p=0.04$ ) red blood cell transfusion requirements. The higher-dose TXA was associated with decreased intraoperative ( $p=0.01$ ), and whole hospital transfusion ( $p=0.01$ ) requirements, even after risk adjustment for potential confounding variables. No complications or side effects from TXA use were noted.

**Conclusion:** High-dose TXA is more effective than low-dose TXA in reducing blood loss and transfusion requirements in idiopathic scoliosis patients undergoing surgery. Further investigation is required regarding the safety of

TXA before it can be generalized in the use of idiopathic scoliosis surgery.

1071

## Spinal Giant Cell Tumor with Paraparesis: A Case Report with an Overview of Current Treatment Modality

Sharif Ahmed Jonayed

National Institute of Traumatology & Orthopaedic Rehabilitation (NITOR), Dhaka, Bangladesh

**Introduction:** The anatomical characteristics of spinal giant cell tumor (GCT) have historically been regarded as an extremely unpredictable bone tumor and still present challenges to surgeons. Controversy remains regarding the proper treatment of patients with spinal giant cell tumor (SGCT). Although advancements in surgical techniques and adjuvant therapies have provided new options for treatment, evidence-based algorithms are lacking. Complete surgical resections of SGCT resulted in the lowest recurrence rates. However, the morbidity of *en-bloc* resections is high. Several recent advancements in adjuvant therapy may hold promise for decreasing SGCT recurrence, specifically stereotactic radiotherapy, selective arterial embolization, and medical therapy using denosumab and interferon.

**Case Report:** A 21-year-old previously healthy woman presented with a 4-month history of continuous progressive back pain and weakness of the lower limb. She denied a history of injury and any underlying diseases. Physical examination showed that she was systematically well in appearance. She was found to have a motor weakness (Medical Research Council scale: right, 3/5; left, 1/5) in the lower limb and was bed retained with intact bowel and bladder function. The plain radiograph showed a pathological fracture of L1. Computed tomography and magnetic resonance imaging of the spine revealed significant bone destruction and pathological fracture of L1, secondary spinal canal stenosis, and extensive paravertebral soft tissue mass around L1. Routine laboratory studies were almost within the normal range. Considering the large volume of the mass and soft tissue invasion, wide local excision including vertebral component resection through posterior approach and chemical cauterization was designed. Posterior spinal canal decompression, in-

ternal fixation, and reconstruction with a cylindrical cage were performed. Peri- and postoperative recovery were uneventful. She was allowed to ambulate with orthosis postoperatively. The postoperative pathology confirmed a GCT. She has then received the treatment with subcutaneous injections of 120 mg denosumab with loading doses on days 8 and 15 of cycle 1 and will continue for a total of 12 months. Daily supplements of vitamin D and calcium supplement are prescribed orally to avoid hypocalcemia. No major complications were associated with surgical treatment and denosumab administration. She is on our regular follow-up for evaluation of her symptoms, physical examination, and radiological imaging assessments.

**Conclusions:** Complete surgical resection of SGCT should be the goal, when possible, particularly if a neurologic impairment is present. A combination of surgical treatment and denosumab treatment can be a definite therapy of choice in treating large GCTs at challenging anatomical locations, such as the spinal regions. These tumors should be approached as a case-by-case problem, as each presents unique challenges. Collaboration of spine surgeons, radiation oncologists, and medical oncologists is the best practice for treating these difficult tumors. Our case highlights the significance of early diagnosis and proper treatment of GCT of the spine with soft tissue invasion has not been previously well reported.

1075

## The Machine-Vision Image-Guided Surgery System Reduces Fluoroscopy Time, Ionizing Radiation, and Intraoperative Blood Loss in Posterior Spinal Fusions for Scoliosis

Kevin Lim

KK Women's & Children's Hospital, Singapore

**Introduction:** Two-dimensional (2D) fluoroscopy has been commonly used as an adjunct in pedicle screw implantation in posterior spinal fusion (PSF). However, radiation exposure from fluoroscopy remains a significant concern. The advent of surgical navigation systems that do not utilize ionizing radiation could significantly improve the safety of the surgical patient and all personnel in the operating room. The aim of this study is to determine if the novel 3D machine-vision image-guided surgery (MvIGS) system can reduce radiation exposure while improving

surgical outcomes when compared to 2D fluoroscopic navigation.

**Methods:** The clinical and radiographic records of patients with severe scoliosis who underwent PSF between 2017 and 2021, utilizing either MvIGS or 2D fluoroscopy, were retrospectively reviewed and analyzed.

**Results:** In this series, there were 128 patients who underwent PSF with pedicle screws using 2D fluoroscopy or the MvIGS system. Age, gender, body mass index, and scoliosis etiology were equivalent between the two groups. Compared to 2D fluoroscopy, MvIGS reduced fluoroscopy time ( $37.86 \pm 15.95$  seconds vs.  $19.16 \pm 7.19$  seconds,  $p < 0.001$ ), radiation exposure ( $127.27 \pm 115.35$  cGycm<sup>2</sup> vs.  $52.91 \pm 38.17$  cGycm<sup>2</sup>,  $p < 0.001$ ), change in the largest Cobb angle ( $33.72^\circ \pm 12.99^\circ$  vs.  $40.00^\circ \pm 11.63^\circ$ ,  $p = 0.005$ ), and estimated blood loss ( $870.25 \pm 616.57$  mL vs.  $553.75 \pm 434.32$  mL,  $p < 0.001$ ). Overall, the average navigation time for the MvIGS system was  $114.07 \pm 51.88$  minutes, and  $5.79 \pm 3.15$  minutes per screw implanted. The number of levels fused, number of pedicle screws implanted, pre- and postoperative Cobb angles, operative time, and length of hospital stay were not significantly different between the two groups.

**Conclusions:** The use of the MvIGS as an adjunct for pedicle screw placement in PSF has contributed to a significant reduction in fluoroscopy time, intraoperative radiation exposure, and estimated blood loss. Exposure to radiation was significantly associated with intraoperative blood loss. The MvIGS holds much promise in improving the overall safety for our young patients with scoliosis undergoing instrumented PSFs.

1090

## Vertebral Artery Injury

Min-Woo Kim

*Department of Orthopaedic Surgery, Busan Medical Center, Busan, South Korea*

**Introduction:** Vertebral artery (VA) injuries during cervical spine surgery are rare with a reported incidence of 0.3% to 0.5%. The VA enters the vertebral foramen most commonly at C6 and courses from anterior and lateral to medial and posterior with respect to the vertebral body up to C3. The VA has a more variable course in the atlantoaxial region. VA injury can be a catastrophic iatrogenic

complication of cervical spine surgery. Although the incidence is rare, it has serious consequences including fistulas, pseudoaneurysm, cerebral ischemia, and death. It is therefore imperative to be familiar with the anatomy and the instrumentation techniques when performing anterior or posterior cervical spine surgeries.

**Purpose:** To provide a review of VA injury during common anterior and posterior cervical spine procedures with an evaluation of the surgical anatomy, management, and prevention of this injury. To discuss and share our experience of VA injury.

**Methods:** A systematic review of medical articles related to VA injury in cervical spine surgery was conducted up to and including journal articles published until 2021.

**Results:** Overall, the risk of VA injury during cervical spine surgery is low. In anterior cervical procedures, lateral dissection puts the VA at the most risk, so sound anatomical knowledge and constant reference to the midline are mandatory during dissection. With the development and rise in popularity of posterior cervical stabilization and instrumentation, recognition of the dangers of posterior drilling and insertion of transarticular screws and pedicle screws is important. Anomalous vertebral anatomy increases the risk of injury and preoperative magnetic resonance imaging and/or computed tomography scans should be carefully reviewed. If a VA injury occurs, rapid action is required to prevent exsanguination or catastrophic neurologic injury. Every attempt should be made to repair the VA because the contralateral artery may not provide sufficient blood flow in spondylotic population. If repair is not possible and contralateral circulation is deemed adequate, endovascular coiling or primary ligation should be performed. Tamponade should be avoided as the definitive treatment because of well-known complications.

**Conclusions:** VA injury during cervical spine surgery is a rare but serious complication. It can be prevented by careful review of preoperative imaging studies, having a sound anatomical knowledge, and paying attention to surgical landmarks intraoperatively. When a VA injury occurs, prompt recognition and management are important.

1096

## Prevalence, Risk Factors, and Complications of Blood Transfusion in Lumbar Spinal Fusion Surgery: A Nationwide Population-Based Study

Taewook Kang

*Department of Orthopaedic Surgery, Cheil Orthopedic Hospital, Seoul, South Korea*

**Introduction:** The incidence of lumbar spinal fusion has increased significantly. However, the effects of blood loss that require a blood transfusion after lumbar spinal fusion remain an important issue. Blood transfusions are used commonly in cases of significant blood loss in lumbar spinal fusion but are associated with adverse effects and increased cost.

**Purpose:** To assess the rate of blood transfusion and the associated risk after lumbar spinal fusion from 2013–2018.

**Methods:** In this nationwide population-based cohort study, the Korean Health Insurance Review and Assessment Service database was reviewed retrospectively from 2013–2018. Data were extracted from patients who underwent lumbar spinal fusion without a history of lumbar spinal surgery in the preceding year. The primary outcome was the rate of blood transfusion within 1 week after surgery. In addition, the risk factors for blood transfusion and the rate of postoperative infection were evaluated.

**Results:** A total of 188,581 patients underwent lumbar spinal fusion between 2013 and 2018. A significant decline in blood transfusions was observed during the study period (56.38%–47.51%). The presence of comorbidities was associated with an increased risk of blood transfusion. Patients who underwent the posterior approach were more likely to receive blood transfusion than patients who underwent the anterior or anterior and posterior approach. Receiving a blood transfusion was associated with postoperative infection.

**Conclusions:** In the present study, the prevalence, risk factors, and postoperative infection associated with blood transfusion in lumbar spinal fusion were identified. Spine surgeons should consider these risk factors in patients at high risk of blood transfusion.

1100

## Single Position Prone Oblique Lateral Interbody Fusion: Technique Review and Early Lessons

Mun Chun Lai

*Tan Tock Seng Hospital, Singapore*

**Introduction:** Oblique lumbar interbody fusion (OLIF) is an effective surgical technique in treating various spine conditions. However, this technique requires additional time and resources since the patient is required to change from a lateral to a prone position. Multiple studies have explored the efficacy of single-position surgeries. In this presentation, we will describe the surgical technique of the prone oblique lateral interbody fusion and share the early lesson, including pearl and pitfall encounters.

**Methods:** The patient is positioned prone on Jackson table. The disc spaces are identified under fluoroscopic guidance. The retroperitoneal space is accessed via finger dissection. The anterior margin of the psoas was identified and mobilized posteriorly, followed by the guide wires and retractor placement. This approach can reduce surgical timing by avoiding the need to reposition the patient and help to achieve better segmental lordosis. In addition, this technique allows surgeons to address multiple-level pathologies (2–3 levels) and to perform direct decompression when indicated. However, this technique has limitations, which we will explain further.

**Results:** Pre- and postoperative radiological imaging with alignment parameters, operative approach, patient outcomes, and complications are described.

**Conclusions:** Our experience with single position-prone OLIF demonstrated shorter operative time by avoiding the need to reposition the patient. This technique also has multiple benefits, including allowing the surgeon to address multiple levels of spine pathologies and allowing posterior decompression and instrumentation when appropriate.

1119

## Fusion Rate with Stand-Alone Mini-open Lateral-Anterior Lumbar Interbody Fusion

Jiaming Cui

*The First Affiliated Hospital, Sun Yat-sen University, Guangzhou, China***Study Design:** Retrospective radiographic analysis.**Purpose:** The objective of this study was to assess the fusion rate of stand-alone mini-open lateral-anterior lumbar interbody fusion (LaLIF) for degenerative lumbar diseases.**Background:** Early clinical reports of stand-alone LaLIF have shown reliable mid-term clinical outcomes and an acceptable complication profile when compared to traditional lateral lumbar interbody fusion (LLIF).**Methods:** We studied patients who underwent standardized LaLIF surgery with implants packed with demineralized bone matrix allograft without recombinant human bone morphogenetic protein-2 (BMP-2). Each patient was assessed clinically and radiologically at each follow-up visit using standard methods. Fusion was determined the bridging bone on the computed tomography scan.**Results:** The participants were patients who underwent LaLIF surgery under the diagnosis of degenerative lumbar diseases between April 2016 and April 2020. All 33 cases involving 67 levels were performed LaLIF surgery: 1 level in 21 cases (63.6%) and 2 levels in 13 cases (39.4%). We achieved a 91.0% (61 of 67 levels) fusion rate using instrumented allograft.**Conclusions:** The fusion rate for levels of LaLIF surgery reached 91.0% which is comparable to those for conventional LLIF. Several factors may have contributed to the fusion rate in LaLIF: (1) LaLIF steps and instruments, (2) precise surgical indications, (3) occurrence and timing of cage subsidence, and (4) abandoned BMP-2.

1190

## Efficacy of Lateral-Anterior Lumbar Interbody Fusion Combined with Second-Stage Posterior Fixation versus One-Stage Posterior Spinal Canal Decompression and Internal Fixation Fusion in the Treatment of Degenerative Lumbar Scoliosis

Jiaming Cui

*The First Affiliated Hospital, Sun Yat-sen University, Guangzhou, China***Introduction:** This study aims to analyze the difference in efficacy between lateral-anterior lumbar interbody fusion (LaLIF) combined with second-stage posterior transmuscular space lumbar internal fixation surgery for degenerative lumbar scoliosis and first-stage posterior spinal canal decompression internal fixation fusion surgery.**Methods:** A retrospective study of the clinical data of 41 patients with degenerative lumbar scoliosis admitted to our department from October 2015 to September 2021, of whom 19 were treated with a combined anterior and posterior approach and 22 were treated with a one-stage posterior approach. The selected evaluation indexes included surgery-related indexes (surgery time, intraoperative bleeding loss, postoperative drainage, postoperative bed rest time, and hospital stay), survival quality-related scale indexes (Visual Analog Scale [VAS] for postoperative low back pain, postoperative Oswestry Disability Index [ODI]), imaging indexes (lumbar anterior convexity angle, lumbar lateral convexity Cobb angle, sagittal balance [sagittal vertical axis, SVA], coronal balance [coronal vertical axis, CVA], disc height [DH]), and postoperative complications.**Results:** In the combined anterior-posterior group, the mean operative time of patients was (88.00±2.06 minutes)+(70±2.12 minutes), the mean intraoperative bleeding loss was (50±1.36 mL)+(57±1.34 mL), the mean postoperative drainage was (38±1.54 mL)+(88±2.55 mL), the mean postoperative bed rest time was (1.6±0.54 days)+(1.5±0.35 days), the mean hospital stay was 10.00±1.47 days, and the mean follow-up time was 11.68±2.70 months. In the one-stage posterior approach group, the mean operative time of patients was 185.23±11.33 minutes, the mean intraoperative bleeding loss was 336.92±13.30 mL, the mean postoperative bed rest time was 5±0.60 days, the mean hospital stay

was  $8.42 \pm 1.17$  days, and the mean follow-up time was  $12.06 \pm 1.38$  months. In the combined anterior-posterior group, the operative time was shorter, intraoperative bleeding loss and postoperative drainage were less, and the postoperative bedtime was shorter, but the hospital stay was longer. The VAS score and ODI of low back pain in both groups were significantly lower than those before surgery ( $p < 0.05$ ), but the difference between the two groups was not statistically significant ( $p > 0.05$ ). After surgery, the anterior lumbar convexity angle, lumbar lateral convexity Cobb angle, sagittal balance (SVA), coronal balance (CVA), and interbody height (DH) were significantly improved in both groups ( $p < 0.05$ ). However, the one-stage posterior group had an advantage in restoring the anterior lumbar convexity angle, lumbar scoliosis Cobb angle, and coronal and sagittal balance of the spine ( $p < 0.05$ ). Complications occurred in three cases in the combined anterior-posterior group and five cases in the one-stage posterior group, and the overall complication rate was slightly lower in the combined anterior-posterior group (15.79%) than in the one-stage posterior group (22.73%), with no statistically significant difference ( $p > 0.05$ ). No serious postoperative complications occurred in both groups.

**Conclusions:** The combined anterior and posterior approach has the advantages of minimally invasive and less bleeding loss than the one-stage posterior approach for the treatment of degenerative lumbar scoliosis, especially for the elderly with various chronic diseases and complications, which can be better tolerated and reduce the risk of surgery, and the postoperative clinical results of both groups are comparable.

## 1200

### Factors Affecting Time from Admission to Surgery for Thoracolumbar AO Type A Fractures

Yong Yao Tan

Department Of Orthopaedic Surgery, Changi General Hospital, Singapore

**Introduction:** Most of spinal injuries involve the thoracolumbar region, with Arbeitsgemeinschaft für Osteosynthesefragen (AO) type A fractures accounting for most of the injuries [1]. In selected cases, surgical intervention can aid with early mobilization, pain control, correction

or prevention of kyphotic deformity as well as the decompression of the spinal cord and nerve roots [2]. Early surgery within 72 hours has been reported to result in fewer complications [3]. The aim of this retrospective study was to identify factors resulting in surgery after 72 hours from admission.

**Methods:** All patients admitted via the emergency department and underwent single-stage instrumentation for AO type A thoracolumbar vertebrae fractures from February 2020 to August 2022 at our institution were included in this study. Polytrauma patients were excluded. Variables of interest included patient factors (age, gender, comorbidities) and hospital factors (preoperative inpatient referrals to other specialties and weekend admission). Shapiro-Wilk test for normal distribution was performed. As the data did not have a normal distribution, univariate analysis was performed with Mann-Whitney *U* test and chi-square test. Multivariate analysis was performed with logistic regression. All significance tests were two-tailed, with  $p < 0.05$  representing statistical significance. Data analysis was performed with Stata ver. 13.0.

**Results:** Thirty-eight patients underwent single-stage instrumentation. Fifteen patients were male (39.5%). The median age was 72.5 years (range, 16–90 years). The median age for females was 78 years (range, 16–87 years) while the median age for males was 70 years (range, 19–90 years). There was a statistically significant difference in the ages between the genders ( $z = 2.08$ ,  $p < 0.05$ ). The median duration from admission to surgery was 6 days (range, 0–29 days). Thirteen patients had surgery within 72 hours of admission. The median age was 63 years (range, 16–81 years). The other 25 patients had surgery after 72 hours and the median age was 75 years (range, 40–90 years). There was a statistically significant difference in the ages between the two groups ( $z = 2.77$ ,  $p < 0.05$ ). There were 18 patients with a history of hypertension and one had surgery within 72 hours. Among the 20 patients who did not have a past history of hypertension, 12 had surgery within 72 hours. There was a statistically significant difference between the two groups ( $\chi^2 [1, n=38] = 12.477$ ,  $p < 0.05$ ). Gender, other comorbidities (ischemic heart disease, previous myocardial infarction, hyperlipidemia, chronic kidney disease, diabetes mellitus, previous cerebrovascular accident or transient ischemic attack, malignancy), preoperative inpatient referrals and weekend admission did not have a significant effect on surgery being performed after 72 hours. Binomial logistic regression was done to



evaluate the effects of age and hypertension on whether a patient had the surgery within 72 hours of admission. Results demonstrated hypertension as an independent factor ( $p < 0.05$ ) while age was not.

**Conclusions:** A past medical history of hypertension is an independent factor that predicted surgery taking place after 72 hours from admission. More research must be done to investigate how a past medical history of hypertension influences the time from admission to surgery and what can be done to mitigate this.

1255

## Usefulness of Expandable Cage in Transforaminal Lumbar Interbody Fusion

Gen Mori

Japan

**Introduction:** The purpose of this study was to compare the pre- and postoperative results of a static cage (titanium three-dimensional printing) and expandable cage in minimally invasive surgery (MIS)-transforaminal lumbar interbody fusion (TLIF).

**Methods:** Forty-one patients underwent one intervertebral TLIF and were followed up for at least 1 year after surgery. The mean age was 71.2 years. Eleven patients had L4/5 cages and 30 had L5/S cages. Eighteen patients in the static cage group (S group) and 23 patients in the expandable cage group (E group) were compared. The clinical evaluation included the Japanese Orthopaedic Association Back Pain Evaluation Questionnaire (JOABPEQ) preoperatively and at 1 year postoperatively, and the imaging evaluation included the local kyphosis angle, lumbar kyphosis angle, and disc height (average of anterior and posterior margins) on X-ray taken preoperatively, at 1 week postoperatively, and at 1 year postoperatively. Bone fusion was evaluated by X-ray and computed tomography images at 1 year postoperatively.

**Results:** The local kyphosis angle was 11.8° preoperatively, 12.4° at 1 week postoperatively, and 11.6° at 1 year postoperatively in the S group. And the local kyphosis angle was 11.9° preoperatively, 16.0° at 1 week postoperatively, and 15.4° at 1 year postoperatively in the E group. Postoperatively, the kyphosis angle was significantly improved in group E compared with group S and was significantly

maintained at 1 year postoperatively. There was no significant difference in lumbar kyphosis angle between the S and E groups. The disc height was 5.5 mm preoperatively, 8.2 mm at 1 week postoperatively, and 7.9 mm at 1 year postoperatively in the S group, and 5.5 mm preoperatively, 9.8 mm at 1 week postoperatively, and 8.8 mm at 1 year postoperatively in the E group. Postoperatively, disc height improved significantly in group E compared to group S. At 1 year postoperatively, both groups experienced a slight loss of correction, and there was no significant difference between the two groups. The bone fusion rate was 55.6% in the S group and 47.8% in the E group at 1 year postoperatively, with no significant difference between the two groups. The JOABPEQ was improved in each group, but there was no significant difference between the two groups.

**Conclusions:** Expandable cages gained significantly more kyphosis angle and improved disc height postoperatively compared to static cages. At 1 year postoperatively, there was no significant difference in disc height, but the kyphosis angle remained significant. One patient in group E had intervertebral instability and required reoperation. The importance of spinal sagittal alignment, especially lower lumbar kyphosis, is now recognized, and it is important to correct kyphosis as much as possible at L4/5 and L5/S. In MIS-TLIF, posterior shortening may be difficult because the posterior component including the unilateral intervertebral joint is preserved as much as possible. Therefore, the raising of the anterior intervertebral space is more important to obtain kyphosis. The results of this study suggest that expandable cages in L4/5 and L5/S TLIF may be useful.

1281

## Clinical Outcomes of Ultrasound Guided Transforaminal Root Block in Cervical Spondylotic Radiculopathy due to Osteophyte

Chang Su Kim

Department of Orthopaedic Surgery, Kosin University Gospel Hospital, Kosin University College of Medicine, Busan, South Korea

**Introduction:** This study aimed to investigate the follow-up progress and the usefulness of treating transforaminal nerve root block using ultrasound in patients with cervical radiculopathy caused by osteophytes of spondylosis.

**Methods:** From January 2016 to January 2021, among 140 patients who presented with cervical radiculopathy, 73 who did not improve with conservative treatment for 3 weeks were treated with ultrasound-guided transforaminal nerve root block. These comprised 46 confirmed cases of spondylotic radiculopathy due to osteophyte and 27 cases of soft disc herniation. Surgical treatment was performed if the pain did not improve by more than 50% at the 2-week follow-up. If 50% or more improvement was achieved, additional procedures were performed an extra 2–3 times, at the patient's discretion. To evaluate the effectiveness of the procedure, the degree of pain and functional improvement were investigated before, after, and three months after the procedure. The safety of the procedure was evaluated by examining the side effects that occurred during, immediately after, and the day after the procedure. Additional procedures or surgeries were checked at the last follow-up of more than 1 year.

**Results:** Among the 46 patients with cervical spondylotic radiculopathy, 29 were men and 17 were women. The average age was 65.9 years, 9.4 years older than the soft disc herniation patients, who had an average age of 56.5 years. The visual pain scale, which evaluated the degree of pain improvement, showed improvement from 6.16 to an average of 2.80. By the final follow-up, 36 patients (78.0%) had improved without surgery, and 24 received additional conservative treatment. Sixteen patients (32.0%) showed symptom recurrence, and the average recurrence duration was 17.41 weeks.

**Conclusions:** In patients with cervical spondylotic radiculopathy due to osteophyte, transforaminal root block showed no significant difference in pain improvement compared to soft intervertebral disc herniation, but the recurrence of symptoms and the rate of surgical treatment was higher. As such, ultrasound-guided transforaminal root block can be considered as one of the conservative treatment methods for patients with cervical spondylotic radiculopathy due to osteophyte.

1283

## The Efficacy and Accuracy of Ultrasonography-Guided Sacral Nerve Block

Chang Su Kim

*Department of Orthopaedic Surgery, Kosin University Gospel Hospital, Kosin University College of Medicine, Busan, South Korea*

**Introduction:** Selective nerve root block under fluoroscopy is an effective procedure in radiating patients. But, S1 foraminal block is more difficult than the lumbar nerve root block on fluoroscopy. The sacral foramen is small and is confused by abdominal gas and bony shadow (ventral sacral foramen). There are more disadvantages such as the exposure to radiation, the large-sized equipment, and the discomfort of access.

**Purpose:** This study is the outcomes 1-year follow-up of ultrasound-guided S1 block compared with fluoroscopy-guided block. And we checked the acute complication and accuracy of the injection.

**Methods:** From February 2012 to December. 2018, we divided patients into two groups (fluoroscopy-guided group [n=20] and ultrasound-guided group [n=29]) they were selected from those, who have lumbar spinal disc herniation causing S1 radiating pain, which could be noticed at magnetic resonance imaging or computed tomography. The effect of the block was assessed by the degree of radiating pain in the lower legs using the Visual Analog Scale and patients' functional score (Oswestry Disability Index) and used C-arm fluoroscopy for the accuracy of an ultrasound-guided block.

**Results:** There were significant improvements and accuracy of over 90% in the two groups. In the ultrasound-guided block, the average time for intervention is 5.5 minutes (range, 3.1–6.7 minutes), had no significant difference with the fluoroscopy group. The complication is one case in fluoroscopy, and he had a metallic taste and dizziness for injection. Vascular injections were seven cases in the fluoroscopy group and 11 cases in the ultrasound group. Ultrasonography-guided sacral nerve root block is an effective and accurate method in sacral radiating pain.

**Conclusions:** Ultrasonography-guided sacral nerve root block is an effective and accurate method in sacral radiating pain. For the risk of intravascular injection, we must use low-dose anesthetics and non-particulate steroids.

1288

## Preoperative Compression Ratio of the Spinal Cord Using Quantitative Magnetic Resonance Imaging in the Surgically Treated Degenerative Cervical Spondylotic Myelopathy

Ronald Tangente

*Davao Doctors Hospital, Davao, Philippines*

**Introduction:** Degenerative cervical spondylotic myelopathy (CSM) evaluation remains a challenge as far as surgical decision-making is concerned. There is a myriad of magnetic resonance imaging (MRI) parameters and cut-off values that are being used in the definition of cervical cord compression and its association with the development of myelopathic symptoms.

**Purpose:** The purpose of the study is to determine which among the MRI parameters namely the transverse area (TA), anterior-posterior canal diameter (AP), and compression ratio (CR) of the spinal cord would be the most significant and valuable in the surgical decision-making of the degenerative (CSM).

**Methods:** This was a descriptive and retrospective study that included all surgically managed degenerative CSM patients admitted to Davao Doctors Hospital from January 2012 up to December 2018. The inclusion criteria were degenerative CSM and a modified Japanese Orthopaedic Association score of less than 15. The preoperative 1.5 Tesla MRI of those included in the study was quantitatively measured using TA, AP, and CR defined as AP diameter/transverse diameter of the spinal cord.

**Results:** A total of 30 patients were included in the study. The narrowest area observed in the study was at C5–C6 intervertebral disc space. The TA range was 15.65–62.7 mm<sup>2</sup>. The mean TA was 34.58 mm<sup>2</sup> (median of 34 mm<sup>2</sup>). And the standard deviation was 10.69 mm<sup>2</sup> (95% confidence interval [CI], 3.89). The range was wide but the maximum diameter coincided with Kadanka and his colleagues that a TA of <70 mm<sup>2</sup> may be the threshold for the development of symptoms in CSM. The mean was much lower than in the study of Okada and his colleagues. The AP range was 1.75–7.3 mm<sup>2</sup> with a mean of 5.22 mm<sup>2</sup> (median, 5.05 mm<sup>2</sup>). The standard deviation was 1.3 mm<sup>2</sup> (95% CI, 0.47). The standard deviation was closer to zero, meaning the values were homogenous. The CR range was

0.1–0.725. The mean was 0.39 (median, 0.375). The standard deviation was 0.11 (95% CI, 0.04). CR of the spinal cord was the most precise and reliable among the three MRI parameters collected. The CR of 0.39 falls within the CR <0.40 as the cut-off for the development of symptoms of CSM as described in the studies.

**Conclusions:** The study showed that among the MRI parameters quantitatively measured, CR determination was the most precise and reliable way of determining the development of symptoms in degenerative CSM. In addition to other measures, CR may also be used in surgical decision-making. Prospective analysis can still strengthen their correlation to symptoms and increase the significance of the surgical decision. In addition, standardization of the measurements remains to be a challenge with regard to reproducibility.

1289

## Accuracy and Safety of a Pedicle Screw Using the Freehand Technique in Minimally Invasive Scoliosis Surgery

Yunjin Nam

*Department of Orthopaedic Surgery, Korea University Guro Hospital, Seoul, South Korea*

**Introduction:** The safety and clinical usefulness of minimally invasive scoliosis surgery (MISS) have been reported in various studies. However, freehand pedicle screwing in MISS remains technically challenging. The purpose of this study is to evaluate the accuracy and safety of pedicle screw placement using the freehand technique in adolescent idiopathic scoliosis (AIS) patients treated with MISS compared to conventional open scoliosis surgery (COSS).

**Methods:** We included 76 patients who underwent deformity correction for AIS. Computed tomography scans were used to assess screw violations divided into two groups according to the surgical technique: MISS or COSS. Anterior violations were classified into grade 0, grade 1 (no contact with internal organs), and grade 2 (contact with internal organs). Medial and lateral violations were classified into grade 0, grade 1 (<2 mm), and grade 3 (≥2 mm). Grade 2 were considered critical violations.

**Results:** A total of 630 and 1,174 pedicle screws were inserted in the MISS and COSS groups, respectively. The

overall critical violation rates of the MISS and COSS groups were 16.8% (106 screws) and 14.0% (165 screws) ( $p=0.116$ ). Medial critical violations on the left side in the middle thoracic region frequently occurred in the MISS group compared to the COSS group ( $p=0.003$ ). There were no statistical differences in the complications (Fig. 1).

**Conclusions:** Pedicle screw placement using the freehand technique in MISS for AIS patients provided similar accuracy and safety compared to COSS. Pedicle screws inserted on the left side of the middle thoracic region exhibited more medial critical violations in the MISS group.

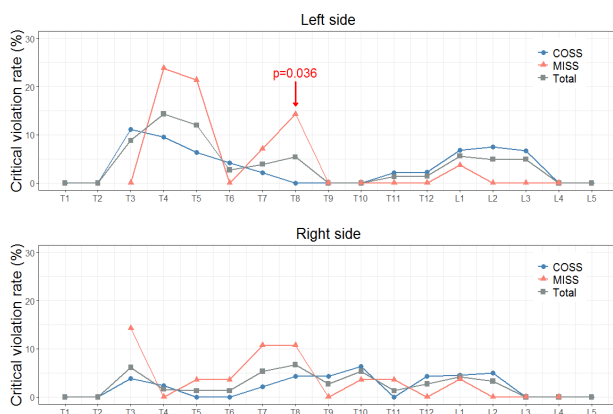
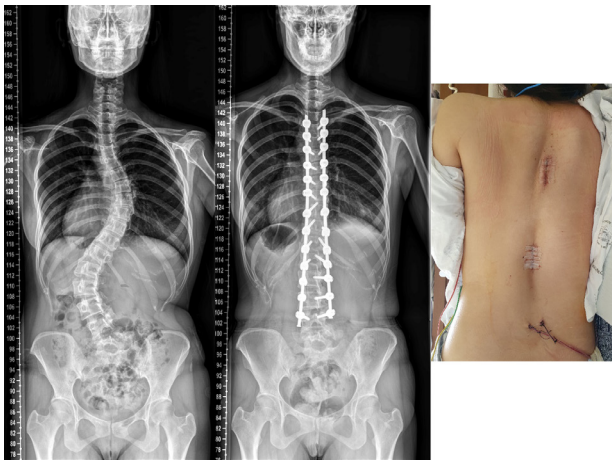


Fig. 1.

1300

## Clinical Characteristics of Culture-Positive Pyogenic Vertebral Osteomyelitis

Akihiro Kakuta

Seikeikai Hospital, Sakai, Japan

**Introduction:** The Infectious Diseases Society of America published clinical practice guidelines for the diagnosis and treatment of vertebral osteomyelitis in 2015, there are still no treatment guidelines in Japan. Our study aimed to report the characteristics of culture-positive pyogenic vertebral osteomyelitis and our clinical outcomes.

**Methods:** Of 98 patients treated with vertebral osteomyelitis in our hospital between 2012 and 2021, 63 patients with causative organisms were identified by blood culture and biopsy. Age, sex, onset type, blood tests at initial diagnosis (hemoglobin, albumin, estimated glomerular filtration rate, C-reactive protein [CRP]), status of diabetes mellitus, culture results, and status of surgery were evaluated.

**Results:** Forty-two patients were male, and 21 were female. The mean age was 69.3 years (range, 37–90 years). As for the types of onset, 36 patients had acute onset, and 27 patients had subacute or insidious. As for the types of causative organisms, 16 patients had methicillin-susceptible *Staphylococcus aureus*, 11 patients had methicillin-resistant *Staphylococcus aureus*, nine patients had *Escherichia coli*, and six patients had streptococcus agalactiae. Surgical intervention was performed on 18 patients. CRP levels were elevated in all patients with a median of 15.2 mg/dL (range, 0.5–40.5 mg/dL). The mean time required for CRP to return to normal was 81 days (range, 13–239 days).

**Conclusions:** We need to know clinical characteristics of culture-positive pyogenic vertebral osteomyelitis in order to explain this to patients and treat effectively.

1308

## Preoperative Pain Sensitivity Predicts Postoperative Pain Severity and Analgesics Requirement in Lumbar Fusion Surgery: A Prospective Observational Study

Ajoy Prasad Shetty

*Ganga Medical Centre and Hospital Pvt. Ltd., Coimbatore, India*

**Introduction:** The goal of postoperative pain management is to facilitate the patient's return to normal activity and decrease the detrimental effects of acute postsurgical pain. In order to provide more tailored and successful pain treatment, it is necessary to identify individuals who are at a high risk of experiencing severe postoperative pain. The most precise way to assess pain sensitivity is by determining the pain pressure threshold and heat pain threshold by objective methods using a digital algometer and neurotouch, respectively. So, we aim to study the correlation between preoperative pain sensitivity, postoperative pain, and analgesic requirements after single-level lumbar fusion surgeries.

**Methods:** This prospective, observational study included 60 patients who underwent single-level lumbar fusion surgeries. Pressure pain threshold measurements with the help of a digital algometer, thermal component by neurotouch instrument, Pain Sensitivity Questionnaire (PSQ), psychological assessment by Hospital Anxiety and Depression Scale (HADS), and functional assessment by Oswestry Disability Index (ODI) were done. All the patients were assessed by Visual Analog Scale (VAS) preoperatively at three instances of needle prick (phlebotomy, glucometer blood sugar, intradermal antibiotic test dose) and during the range of movements of the lumbar spine region. Postoperative VAS score and postoperative breakthrough analgesic requirements were recorded in all of these patients from day 0 to day 3.

**Results:** The average age of the patients was  $51.11 \pm 13.467$  years and 70% were females. Females had lower mean algometry values ( $72.14 \pm 7.56$ ) compared to males ( $77.34 \pm 6.33$ ). Patients with higher HADS ( $p < 0.0016$ ), higher PSQ ( $p < 0.001$ ), higher ODI scores ( $p < 0.001$ ), and female gender significantly correlated with a lower algometer average. Patients with lower preoperative VAS scores and with higher neurotouch scores showed lower postoperative VAS scores at different time periods. Preop-

erative VAS scores, algometer average scores, neurotouch scores, and HADS scores were considered as independent variables (predictors) for postoperative VAS at a 6-hour period as the dependent variable (outcome). By the multivariate analysis, factors like preoperative VAS scores, algometer average scores, and HADS scores were found to be statistically significant ( $p < 0.05$ ). There was a significant correlation between algometer average scores ( $p < 0.000$ ) and thermal neurotouch scores ( $p < 0.05$ ) with the breakthrough analgesics.

**Conclusion:** Preoperative assessment of pain sensitivity can predict postoperative analgesic requirements and aid in recovery. Patients with a lower pain threshold should be counseled preoperatively and receive a better titration of analgesics perioperatively.

1310

## A Survival Probability Tool Based on 10,537 Patients with Spinal Metastases in Hong Kong Using a Machine Learning Based Model

Kenny Yat Hong Kwan

*The University of Hong Kong, Hong Kong*

**Introduction:** Spinal metastasis is a common scenario in cancer affecting 30% of patients. An accurate survival estimate is essential for the spinal care team to decide the most appropriate treatment for this heterogeneous group of patients. Commonly used scoring systems developed in the 1980s have now proven to be inaccurate given advances in oncologic treatment. The aim of the study is to construct a Spinal Metastasis Estimation Widget (SMEW)—an online survival probability tool to support clinicians' decisions on treatment intensification for spinal metastases condition based on the territory-wide evolutionary polynomial regression of Hong Kong using a machine learning algorithm.

**Methods:** The retrospective study cohort consisted of cancer patients who had received palliative radiation therapy between January 2005 to December 2018 for symptomatic spinal metastases from 6 cancer centers of the Hong Kong Hospital Authority. A light gradient boosting machine was used as a prediction model. Data was divided into two parts: 80% of the data for model training and 20% for model testing with 10-fold cross-validation.

**Results:** With objective indicators, our machine learning model performance was accurate statistically, with an area under curve score of 87.8%. The model trained with the top 15 features was developed into a web application. The app prediction results will be anonymized, encrypted, and stored for subsequent evaluation.

**Conclusions:** A novel survival probability tool (SMEW) for patients suffering from spinal metastases that are personalized to the patient's own data has been developed with a high predictive value.

---

**1335**

## A Case of Dural Injury Caused by the Drainage Tube after Lumbar Spinal Stenosis Surgery

Shinji Tanishima

*Division of Orthopedic Surgery, Department of Sensory and Motor Organs, School of Medicine, Faculty of Medicine, Tottori University, Yonago, Japan*

**Introduction:** Few studies have reported complications associated with postoperative drainage of the spine. In this study, we report a case of dural damage caused by a suction drainage tube.

**Case Report:** A 74-year-old woman diagnosed with cervical spondylotic myelopathy and lumbar spinal stenosis underwent cervical laminoplasty and lumbar laminectomy with longitudinal split spinous processes. In the lumbar spine, the dura mater was thinning, but no obvious dural injury occurred. The surgery was completed without any problems, the patient's preoperative leg pain disappeared, and her progress was good. However, the next morning after the surgery, she developed right lower-extremity pain the moment she went to bed. Analgesic drugs did not relieve the pain, and it was difficult to control. An epidural hematoma was suspected; thus, magnetic resonance imaging (MRI) was performed, which revealed a mass at the L4/5 level that appeared to be an epidural hematoma. Emergency surgery was performed on the same day. After removing the epidural drain in the operating room, surgery was started. Intraoperative findings revealed an epidural hematoma and an indentation on the dura mater that appeared to be caused by the epidural drain; a portion of the dura mater was missing, exposing the cauda equina nerve. The dural injury from the drain and the damage to the cauda equina nerve were considered causes

of the leg pain, and the mass on the dorsal surface of the L4/5 dura seen on MRI was a part of the drain. The caudal nerve was returned, the dura mater was repaired, and the wound was closed. After the reoperation, the patient's leg pain disappeared, and the leg paralysis did not recur, but dysuria remained.

**Conclusions:** In this case, possible causes include the presence of dural damage that did not become apparent during the surgery, dural damage caused by the drain, and thinning dura mater damaged by increased abdominal pressure due to standing movements on the day after surgery, causing the dura mater and cauda equina to become entrapped in the drain. In this case, a slit-type drain was used; although it has excellent blood collection, the slit portion may have pinched the dura mater, posing a risk of damage. When the MRI before reoperation was reviewed, the drain appeared to have become entrapped in the dura mater, suggesting that the drain was placed directly over the dura mater, and following abdominal pressure or direct dural injury caused by body movements, the drain slit aspirated the cauda equina nerve, leading to the sudden onset of leg pain. Drainage tubes placed postoperatively can cause dural or cauda equina injuries, depending on their location and conditions.

---

**1338**

## Boomerang-Shaped Spinal Cord Compression and the C-Sign: Risk Factors for Complications following the Posterior Approach for Ossification of the Posterior Longitudinal Ligament in the Cervical Spine

Jun-Hao Tan

*National University Hospital, Singapore*

**Introduction:** While posterior cervical procedures for ossification of the posterior longitudinal ligament (OPLL) confer satisfactory clinical outcomes at long-term follow-up, perioperative complication rates are significantly higher than that of other surgeries for degenerative cervical conditions.

**Purpose:** The purpose of this study is to investigate clinical, surgical, and radiological risk factors of complications following open-door laminoplasty (LP) and laminectomy with instrumented fusion (LF) for symptomatic cervical OPLL.

**Methods:** This was a retrospective cohort study, conducted at a single tertiary hospital. All consecutive patients who underwent posterior cervical decompression for OPLL with a minimum of 2-year follow-up were included. Logistic regression analysis was performed to identify risk factors for complications.

**Results:** Eighty-eight patients, 77.3% of whom were male, with a mean overall patient age of  $60.6 \pm 10.0$  years were analyzed. No statistical differences in clinical parameters were found between patients who underwent LP and LF. Twenty-three complications (26.1%) occurred in the cohort and a statistically significant difference was noted between procedures (LF 17.0%, LP 9.1%;  $p=0.034$ ). The majority of complications were neurological in nature (14.8%) with eight patients (9.1%) suffering from postoperative C5 palsy. Univariate analysis found that female gender (odds ratio [OR], 3.5;  $p=0.032$ ), LF (OR, 3.1;  $p=0.034$ ), K-line (-) OPLL (OR, 3.4;  $p=0.038$ ), boomerang-shaped spinal cord compression (OR, 4.6;  $p=0.010$ ), and presence of the C-sign (OR, 3.2;  $p=0.035$ ) were risk factors for perioperative complications. Multiple logistic regression confirmed that boomerang-shaped spinal cord compression (OR, 10.1;  $p=0.003$ ) and the C-sign (OR, 6.2;  $p=0.017$ ) were predictive of surgical complications.

**Conclusions:** Female patients, LF procedure, and K-line (-) OPLL experienced a trend towards higher complication rates. To the best of the authors' knowledge, this study is the first to describe an association between a C-sign and boomerang-shaped spinal cord on preoperative imaging with perioperative complications in patients undergoing posterior cervical surgery for OPLL.

1363

## Hirayama's Disease: Does Surgery Help?

Anindya Basu

*Institute of Neurosciences Kolkata, Kolkata, India*

**Introduction:** Hirayama disease also called as monomelic amyotrophy, juvenile amyotrophy of the distal upper extremity or cervical flexion myelopathy is a benign and self-limiting cause of compressive myelopathy, first described in 1959 by Keizo Hirayama. It predominantly affects males in their 2nd and 3rd decades and is relatively common in the Asian population. Given the rarity of the disease, lack of a standardized treatment protocol, and

a paucity of literature dealing with this entity, there are various controversies regarding the optimum treatment modality and duration, as well as indications for surgical intervention. While conservative management using the cervical collar is the mainstay of treatment given its self-limiting course, there is an increasing interest in surgical management, lately, with more literature showing good outcomes.

**Methods:** We retrospectively collected data from 17 patients treated in our institute in the last 6 years (2016–2022) with a confirmed diagnosis of Hirayama's Disease on the basis of clinical features and dynamic magnetic resonance imaging (MRI) findings. The clinical features used as inclusion criteria: (1) chronic weakness and atrophy of the distal upper limb(s); (2) insidious onset in the 2nd and 3rd decade; (3) presence of minipolymyoclonus; (4) absence of substantial sensory deficits, pyramidal signs, as well as of cranial nerve, sphincter or cerebellar involvement; and (5) progression followed by arrest of disease or relatively benign course. All patients who had clinical suspicion underwent a dynamic MRI in neutral and flexion positions of the neck. Radiological findings for the absence of disc herniations, spondylotic spurs, hypertrophy of the yellow ligaments, and segmental instability were checked. Patients who had any of these features as well as those with other causes of myelopathy, such as spinal cord tumors and vascular malformations, syringomyelia were excluded. The following features were evaluated: (1) abnormal cervical curvature, (2) asymmetric cord flattening, (3) symmetric cord flattening, (4) localized lower cervical cord atrophy, (5) T2 hyperintensity in the lower cervical cord, (6) prominent epidural flow voids, (7) enhancing epidural component in the lower cervical region, (8) thoracic extension of the enhancing epidural component, (9) loss of attachment between the posterior dural sac and subjacent lamina on flexion, and (10) anterior shifting of the posterior wall of the cervical dural canal on flexion. Out of 17 patients, three were treated surgically and 14 patients were managed conservatively with a cervical collar and regular follow-up. Of the three surgical cases, two were managed via an anterior and one via a posterior approach.

**Results:** Most conservatively managed and all surgically managed patients had near complete resolution of symptoms on final follow-up.

**Conclusions:** We recommend conservative management for patients with mild neuro-deficit and gradual progres-

sion and surgery in patients who had failed conservative management or with severe weakness and rapid deterioration of symptoms. With early diagnosis and initiation of conservative treatment, the prognosis is generally favorable.

1375

## Modified “Lift-up” Laminoplasty: A Novel Surgical Technique for Long-Segment Epidural/Intradural Tuberculoma: A Case Series

Anindya Basu

*Institute of Neurosciences Kolkata, Kolkata, India*

**Introduction:** The prevalence of tuberculosis is increasing with 10% having central nervous system involvement. Rarely they present as intradural extramedullary (IDEM) tuberculomas or spinal epidural abscess (SEA). Though antituberculosis chemotherapy is still the gold standard treatment for spinal tuberculosis, a few of them require surgical intervention. We would like to describe the technique called the modified lift-up laminoplasty, for surgical management of long-segment organized IDEM/SEA tuberculomas.

**Methods:** A retrospective review of OT records for spinal tuberculosis managed with lift-up laminoplasty in the past 2 years at our institute was done. All the relevant records and imaging of the patients were retrieved and each case has been briefed separately.

**Results:** Four patients were included in the study: two males and two females. Two patients were diagnosed with IDEM tuberculomas, one case of tubercular SEA without osseous involvement, and one case of tubercular SEA with osseous involvement. All were managed surgically with a modified lift-up laminoplasty technique. Three patients had good clinical improvement at the final follow-up.

**Conclusions:** Early imaging of magnetic resonance imaging helps in the early diagnosis of atypical spinal tuberculosis. Most of them require surgical intervention. The technique of modified lift-up laminoplasty gives the dual advantage of adequate working space and preserves the posterior tension band ligaments. It is an efficient surgical method for cases with long-segment epidural/intradural organized granulation tissue.

1427

## Deformity Angular Ratio and Its Correlation with Complications Rate

Muhammad Hamid

*Lahore General Hospital, Lahore, Pakistan*

**Introduction:** Although the literature has established that posterior vertebral column resection (PVCR) in patients with a spinal deformity has achieved excellent outcomes, still it has high risk neurologically.

**Purpose:** To identify whether the deformity angular ratio (DAR, maximum Cobb measurement divided by the number of vertebrae involved) correlates with the risk of neurological deficits and occurrence of complications after PVCR.

**Methods:** In this study, we included the PVCR patients for evaluating deformity severity and potential neurologic deficit risk. This retrospective study was done on 78 consecutive pediatric and adult patients who underwent PVCR from July 2017 to July 2019. The patients were divided into two groups based on the cut-off value of DAR, i.e., total (T)-DAR >23.5 and sagittal (S)-DAR >15.9. Both groups were further distributed in higher and lower T-DAR & S-DAR subgroups. The outcome/complications of T-DAR and S-DAR were compared.

**Results:** Both groups were significantly associated with postoperative complications. In the higher T-DAR group, total complications. The number of patients who developed complications and the total number of complications were significantly high in S-DAR. The high T-DAR group showed worsening intraoperative neurophysiologic monitoring than the high S-DAR group. The incidence of spinal cord monitoring events was 16.8%. Twelve patients developed new neurologic deficits. The higher T-DAR group had worse intraoperative spinal cord monitoring than the higher S-DAR group.

**Conclusions:** Both T-DAR and S-DAR can be used as risk factors for the prognosis of patients after PVCR regarding postoperative complications.



1527

## Ultra-Long Construct Navigated Minimally Invasive Spine Surgery Is Safe for Extensive Spinal Metastasis Patients

Panya Luksanapruksa

*Faculty of Medicine Siriraj Hospital, Mahidol University, Bangkok, Thailand*

**Introduction:** To Identify the treatment outcome of extensive spinal metastasis patients (surgical classification of spinal tumors type 7) by comparing the ultra-long construct navigated minimally invasive spine surgery (UNMISS) technique with the radiotherapy alone.

**Methods:** Extensive Spinal metastasis patients who underwent palliative spinal surgery, which involved more than 10 vertebral bodies, and patients who were planned to undergo UNMISS but denied surgery and received radiotherapy alone between January 2017 and December 2020 were included in our study. The demographic data, disease characteristics, and treatment outcome (Visual Analog Scale [VAS], survival outcome) were identified, and calculate the statistical difference.

**Results:** Twenty-three patients were included in our study. Fourteen patients underwent UNMISS, and nine patients received radiotherapy alone. There has no difference in the baseline characteristics of patients. The most extended construct in our case series involved T1 to iliac. All patients significantly improved in pain scores ( $p=0.01$ ), but those who underwent UNMISS had significantly lower post-treatment VAS than those who received radiotherapy alone. There has been no statistically significant difference in survival outcomes between groups.

**Conclusions:** The UNMISS should be considered as an alternative treatment in a patient with symptomatic extensive spinal metastasis. The primary goal of this technique is to stabilize the multiple levels of spinal metastasis and decompression of the neural element if needed. This technique is safe and has a better outcome in pain improvement than the patient who received radiotherapy alone.

1530

## Postoperative Outcomes of Subaxial Cervical Spine Metastasis: Comparison among the Anterior, Posterior, and Combined Approaches

Sirichai Wilartratsami

*Faculty of Medicine Siriraj Hospital, Mahidol University, Bangkok, Thailand*

**Introduction:** The incidence of subaxial spinal metastases increases due to longer life expectancy resulting from successful modern cancer treatments. The three most utilized approaches for surgical treatment include the anterior, posterior, and combined approaches. However, despite increasing surgical volume, data on the postoperative complication profiles of different operative approaches for this patient population is scarce.

**Methods:** The institutional databases of two large referral centers in Thailand were retrospectively reviewed. Patients with subaxial cervical spine metastasis who underwent cervical surgery from 2005 to 2015 were identified and enrolled. Clinical presentations, baseline characteristics, operative approach, perioperative complications, and postoperative outcomes, including pain, neurological recovery, and survival, were compared among the three surgical approaches.

**Results:** The 70 patients (44 with anterior approach, 14 with posterior approach, and 12 with combined approach) were enrolled. There were no statistically significant differences in preoperative characteristics, including the Charlson comorbidity index, Tomita score, and Revised Tokunashi score, among the three groups. There were no significant differences among groups for medical complications, surgical complications, neurological recovery, verbal pain score improvement, survival time, or ambulatory status improvement. However, the combined approach did show a significantly higher rate of overall perioperative complications ( $p=0.01$ ), intraoperative blood loss ( $p<0.001$ ), and operative time ( $p<0.001$ ) compared to the other two approaches.

**Conclusions:** Patients in the combined approach group had the highest rates of perioperative complications. However, although the differences were not statistically significant, patients in the combined group tended to have better clinical outcomes after follow-up and the longest survival time.

1554

## Transforaminal Lumbar Interbody Fusion: A Two-Year Disability Outcomes Study

Gaurav Dhakal

*National Trauma Center, Kathmandu, Nepal*

**Introduction:** Transforaminal lumbar interbody fusion (TLIF) is one of the most common procedures for lumbar interbody fusion. TLIF helps to decompress the neural elements and stabilize the spine. This study was done to determine the disability outcomes of TLIF surgery with the help of the Oswestry Disability Index (ODI) score in patients undergoing TLIF surgery for spinal diseases in a low-middle income patient population.

**Purpose:** To assess the disability outcome of TLIF with specific reference to improvement in ODI score.

**Methods:** The case undergoing TLIF surgery between September 2016 to September 2020 with a minimum 2-year follow-up were evaluated preoperatively and 2 years postoperatively and the ODI score was measured preoperative and postoperative and the change in ODI score was calculated.

**Results:** Among the total 34 cases, 23 (67.6%) were male and 11 (32.4%) were female and the mean age was  $50.5 \pm 10.2$  years. Among the operative cases, 21 were degenerative listhesis, and 13 were lytic listhesis. The mean ODI score of the patients preoperatively was 58.7 whereas it decreased to 20.2 at 2 years postoperatively ( $p=0.015$ ). Among the sections of improvement in ODI score, the highest improvement was observed in social life.

**Conclusions:** TLIF is an effective surgical technique and leads to significant improvement in quality of life after surgery. Social life showed the most significant improvement in the disability scale.

1605

## Prediction of Cervical Spondylosis Classification Using Deep Learning with Convolutional Neural Network

Hiroyuki Tachi

*Eniwa Hospital, Eniwa, Japan*

**Introduction:** Cervical spondylotic myelopathy (CSM) is becoming more common in the initial consultation with non-specialists because of the increasing prevalence of the disease in an aging society. Although CSM patients with progressive symptoms are recommended to undergo early surgery, it is difficult for non-specialists to determine whether surgery is necessary. Non-specialists will have a significant advantage if CSM with surgery and cervical spondylotic radiculopathy (CSR) without surgery can be classified from initial X-rays.

**Purpose:** The purpose of this study was to validate the prediction accuracy of a deep learning model for classifying CSM and CSR from the cervical spine X-ray.

**Methods:** We enrolled 150 patients who underwent surgery for CSM and 150 patients who underwent conservative therapy for CSR between January 2016 and November 2022. A deep learning algorithm (DLA) with the convolutional neural network (CNN) was configured to classify CSM and CSR from the cervical spine midline X-ray. Each of 150 X-ray images of CSM and CSR were cropped in the region around the cervical spine and used as input data for training datasets and validation datasets. In the internal validation, the DLA was validated using six-fold cross-validation. To evaluate the performance of the trained DLAs using an independent external validation dataset, 100 images including 50 CSM images and 50 CSR images were collected. The 100 images were classified into CSM and CSR by a total trained network with weight and bias of the six trained DLAs.

**Results:** The area under the curve, prediction accuracy, sensitivity, and specificity were 0.873, 0.787, 0.830, and 0.763 in the internal validation datasets, and 0.9464, 0.890, 0.940, and 0.840 in the external validation dataset, respectively. The Grad-cam (heat map) showed that DLAs mainly extracted the anterior vertebral osteophytes and the narrowing of the spinal canal as high-feature regions (Fig. 1).

**Conclusions:** The DLAs with the CNN had high accuracy

in classifying CSM with surgery and CSR without surgery, indicating that an application with the DLAs would be helpful for non-specialists. The next step is to develop an application with the DLAs to classify CSM and CSR from uncropped images by collecting a large number of images.

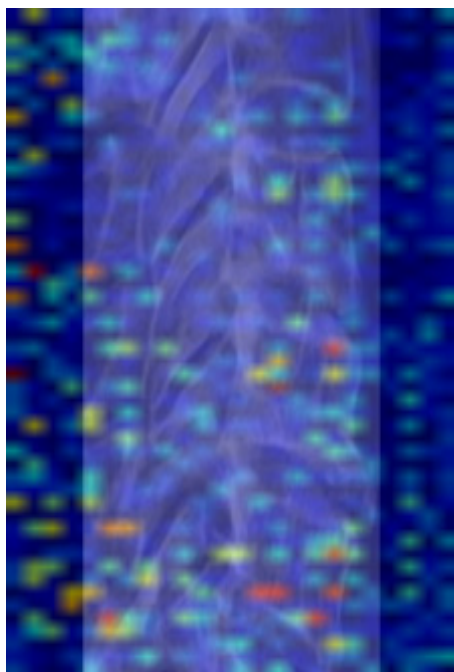


Fig. 1. Grad-cam.

1615

## Therapeutic Use of Platelet-Rich Plasma in Orthopedic and Spine Disorders: Our Experiences

Shahidul Islam

*Ad-Din Womens Medical College Hospital, Dhaka, Bangladesh*

**Introduction:** Platelet-rich plasma (PRP) is a substance thought to promote healing when injected. Plasma is a component of blood that contains special factors or proteins that help the blood to clot. It also contains proteins that support cell growth. Nowadays autologous PRP therapies have seen a dramatic widespread use for orthopedic conditions in the last 5 years.

**Purpose:** The treatment of so many conditions like frozen shoulder, avascular necrosis (AVN) of the hip joint, Perthes disease, knee osteoarthritis, ligament injury, muscle strain, tenosynovitis, and tendinopathy was less

satisfactory. Now we want to arise hope for those patients by using PRP.

**Methods:** It is an observational study. The study was conducted in the Department of Orthopedics & Spine Surgery in Ad-din Women's Medical College Hospital & Ibn Sina D lab and imaging center, Dhanmondi, Dhaka, Bangladesh during the period of August 2019 to January 2022. For the last 3 and half years, we are giving PRP on different orthopedic conditions such as knee osteoarthritis, frozen shoulder, AVN of the hip joint, Perthes disease, and Planter fasciitis. Improvement of these diseased conditions is encouraging especially for AVN of the hip, Perthes disease, and osteoarthritis of the knee joint. After taking history, clinical examination, and doing some routine investigation and imaging test (magnetic resonance imaging, computed tomography scan, X-ray), we choose patients for the PRP procedure. We are doing this procedure in the operation theater with all aseptic precautions and emergency facilities without any radiological help.

**Results:** Though these orthopedic conditions are difficult to treat with or without surgery, the result of PRP is encouraging and it reduces the morbidity of patients and gives comfort.

**Conclusions:** As PRP is a newer technique, a long study period with many cases are to be needed for the academic establishment of the benefit of PRP.

1646

## Analysis of Critical Mid-Sagittal Lumbar Canal Diameter and Its Clinical Significance in 1,491 Multiracial Asian Population

Chongyan Wang

*National University Hospital Singapore, Singapore*

**Introduction:** Current radiological measurements for lumbar stenosis are mostly determined in Caucasian populations. The aim of the study is to measure mid-sagittal lumbar canal diameters at different races, gender, and age groups in the Asian population and to identify its clinical significance in regard to subsequent decompression surgeries.

**Methods:** A retrospective study of consecutive patients who underwent a magnetic resonance imaging (MRI) lumbar spine or MRI whole spine in a single university hospital was performed. Cases with fracture, infection,

and malignancies were excluded. Demographics of the patients were recorded including age, race, and gender. Measurements for congenital lumbar spinal stenosis were obtained for vertebral levels L1 to L5, and measurements for acquired lumbar spinal stenosis were obtained for L1/2, L2/L3, L3/L4, L4/L5, and L5/S1 levels on mid-sagittal MRI T2 views. We have also recorded these cases who underwent decompression surgery within 2 years following MRI scans. Independent *t*-test and analysis of variance test were performed to compare lumbar canal diameters in different genders, races, and age groups. Multivariate logistic regression analysis was performed to identify risk factors and odds ratio for decompression surgery within 2 years. All statistical analyses were performed using the R Studio software.

**Results:** A total of 1,491 patients were included in this study (679 females and 812 males) and 169 patients (11.3%) of them subsequently had lumbar decompression surgery within 2 years after the MRI investigation. The average mid-sagittal canal diameters from L1/2 disc to L5/S1 disc levels were 14.4 mm, 13.6 mm, 12.7 mm, 11.3 mm, and 11.2 mm, respectively. The 10th percentile diameters were 10.8 mm, 9.6 mm, 8.4 mm, 7.0 mm, and 7.5 mm, respectively. The average mid-sagittal canal diameters from L1 vertebral to L5 vertebral levels were 14.5 mm, 13.6 mm, 12.8 mm, 12.5 mm, and 12.4 mm, respectively. The 10th percentile diameters were 12.4 mm, 11.3 mm, 10.4 mm, 9.7 mm, and 9.1 mm, respectively. When using 12 mm at the disc level as cut-off values for acquired stenosis and 10 mm at the vertebral level for congenital stenosis from Caucasian studies, 60.3% of our population (899/1491) were defined as acquired stenotic and 18.8% (281/1,491) as congenital stenotic. Univariate analysis showed that there was no statistically significant difference in canal diameters among different age groups, gender, and race except at L5/S1 level. Decompression surgeries were performed in two cases at L1/2 levels, four at L2/3 levels, 28 at L3/4 levels, 124 at L4/5 level, and 80 at L5/S1 levels within 2 years following the MRI scans. Multivariate regression analysis showed that surgery within 2 years following MRI scans was statistically significantly related to the mid-sagittal lumbar canal diameter, spondylolisthesis, and claudication symptoms but not axial back pain after adjusting age, gender, and race. Mid-sagittal canal size  $\leq 12$  mm at L4/5 (odds ratio, 3.2) and at L5/S1 (odds ratio, 2.1) were independent risk factors for decompression surgery.

**Conclusions:** The mid-sagittal diameter of the lumbar spinal canal is relatively narrower in the Asian population; the radiologic criteria of spinal stenosis should be reconsidered for these people.

1666

## Reduction of Radiation Exposure to Zero during Selective Lumbar Nerve Block

Ryo Kitagawa

*Saiseikai Kanazawa Hospital, Kanazawa, Japan*

**Introduction:** Fluoroscopy guidance is useful for selective lumbar nerve root block. However, it provides radiation exposure to the surgeon. A surgeon's hands have the greatest exposure risk. The author developed a novel method to minimize radiation exposure as low as reasonably achievable. This study aimed to confirm that our novel method decreased radiation exposure during selective lumbar nerve block.

**Methods:** We prospectively reviewed 61 consecutive procedures on 53 patients, 40 novel and 21 conventional methods (L1–5). In a novel method, with patients prone, an intermittent single shot image with pulse mode was obtained every 2–3 cm advance of the needle, keeping hands away from the irradiation field. After the needle tip reached the transverse process and passed the intertransversarii muscle, 2 mL of local anesthetic was administered without puncturing the nerve root and obtaining radiating pain. The fluoroscopy time and radiation dose were compared in both methods. Radiation reduction gloves were not utilized in both methods. Radiation exposure of the surgeon's hand and the entire procedure time were recorded in a novel method.

**Results:** The average fluoroscopy time and irradiation doses were significantly lower in the novel method; 5.6 seconds and 1.33 mGy in the novel method, while 76.5 seconds and 13.5 mGy in the conventional method ( $p < 0.05$ ). The radiation exposure of the surgeon's hand was undetectable with ring dosimetry, indicating substantially 0 mSv. The average time for the entire procedure of the novel method was 124.7 seconds. All patients had pain relief except two with blocks not on the responsible nerve root.

**Conclusions:** The novel method reduced radiation expo-

sure of the surgeon's hand to substantially zero during selective lumbar nerve block. The fluoroscopy time and irradiation doses of a novel method were less than one-tenth of the conventional method. The procedure was also easy because the pain was relieved without confirming radiating pain, unlike the conventional method. Therefore, our method is feasible for reducing radiation exposure, procedure time, and distress of patients.

---

**1682**

## The Comparative Morphology of Posterior Longitudinal Ligament Ossification in Asian and Caucasian Populations

Alex Quok An Teo

National University Hospital Singapore, Singapore

**Introduction:** Ossification of the posterior longitudinal ligament (OPLL) is known to occur at a higher prevalence in the East Asian population compared to the Caucasian population. Although it is known that outcomes following surgery in both populations are favorable, there have been no direct comparisons of their radiological appearances. The aim of this study was to directly compare the OPLL morphologies in two homogenous populations using computed tomography (CT) scans.

**Methods:** Consecutive patients who presented to the spine clinic at two separate tertiary spine referral centers with neck pain with or without radicular or myelopathic symptoms, and were later diagnosed with OPLL on CT scans were included. Apart from basic demographic data, morphological data were obtained from the CT scans for each patient. The collected data include the distribution of OPLL, the Hirabayashi classification (continuous, segmental, mixed, localized), the presence of the 'C'-sign, and the presence of the 'double-layer' sign. Whether the OPLL was symmetrical or not was associated with an occupying ratio of >50%. Statistical comparisons were performed using unpaired Student *t*-tests and chi-square tests.

**Results:** A total of 105 and 103 patients were included in the Asian and Caucasian populations, respectively. There was no difference in the mean age (58.6 vs. 59.4,  $p=0.6428$ ) and gender (male preponderance, 81.9 vs. 70.9%,  $p=0.0622$ ) proportions of both cohorts. There was also no difference seen in the proportions of concomitant ligamentum nuchae calcification (12.4 vs. 11.7%,

$p=0.8711$ ), yellow ligament ossification (7.6 vs. 2.9%,  $p=0.1303$ ), and diffuse idiopathic skeletal hyperostosis (16.2 vs. 12.6%,  $p=0.4610$ ). In terms of OPLL morphology, segmental OPLL was the most prevalent subtype in each group but made up a significantly higher proportion in the Caucasian population (54.4 vs. 38.1%,  $p=0.0187$ ). In contrast, the localized subtype was more prevalent in the Asian population (21.9 vs. 7.8%,  $p=0.0044$ ). The anatomical distribution of the OPLL in both patient cohorts was similar, with the highest prevalence in the mid-levels (C3–6) and tapering off cranially and caudally. In terms of morphology, the proportion of patients with asymmetrical OPLL was significantly higher in the Caucasian population (27.2 vs. 15.2%,  $p=0.0345$ ), and correspondingly there was also a higher proportion of patients with positive C-sign in the Caucasian population (44.7 vs. 7.6%). Proportions of patients who had a positive double-layer sign, and those with an occupying ratio >50% did not differ between the two cohorts.

**Conclusions:** The morphology and distribution of OPLL in Asian and Caucasian cohorts are similar overall. This is the first study to demonstrate a difference in subtype distribution between Asian and Caucasian patient cohorts, although we were unable to adjust for underlying differences in overall prevalence. The higher prevalence of asymmetrical OPLL in the Caucasian population is also novel and highlights the need for particular attention to the prevention of nerve root damage during decompressive surgery. Future work should also correlate this to the prevalence of radicular symptoms at presentation.

---

**1698**

## Morphological Analysis for Safe Placements of Guide Pin Integrated Percutaneous Pedicle Screws Only with Anteroposterior Fluoroscopy

Ryo Kitagawa

Saiseikai Kanazawa Hospital, Kanazawa, Japan

**Introduction:** Percutaneous pedicle screw fixation requires fluoroscopic image guidance. Consequently, radiation exposure is inevitable, but the radiation exposure from lateral fluoroscopy is exceptionally high. Thus, decreasing lateral fluoroscopy is essential for reducing radiation exposure for everyone in the operating room. Unlike other

devices, guide pin integrated screws can freely advance or retract a guide pin up to 25 mm, and eliminate the guide-wires or tapping. Hence, the depth of the tip of the guide pin is detectable even in anteroposterior fluoroscopy. This study aimed to evaluate the morphology of the spine for safe placement of guide pin integrated screws only with anteroposterior fluoroscopy.

**Methods:** The author retrospectively reviewed 140 pedicles (T10–L5) in randomly selected ten patients (five male and five female patients; average age, 70 years) without deformities who underwent myelography computed tomography. The ideal pedicle screw trajectory was defined as the line passing the center of the pedicle, with 10° inward in T10–L2 or 10°–15° in L3–5; consequently, the entry points were slightly inside the lateral wall of the pedicle. Anatomical relationships between the 25 mm point from the entry point on the ideal screw pathway, the posterior wall of the spinal body, and the medial wall of the pedicle were evaluated in axial view.

**Results:** The average height and body mass index were 158.6 cm and 24.8 kg/m<sup>2</sup>, respectively. The average screw length and pedicle width were 50.3 mm and 7.8 mm, respectively. In all 140 cases, the 25 mm point from entry was beyond the posterior wall. The average distance between the 25 mm points and the line of the medial wall of the pedicle was 1.7 mm outside this line. The average length that the ideal screw reached the medial wall line was 34.5 mm. These results indicated that the safe placement of pedicle screws could be achieved only with anteroposterior fluoroscopy, except for the final confirmation of lateral fluoroscopy, if the tip of the fully advanced 25 mm guide pin was slightly outside the medial wall of the pedicle. With this technique, safety placements of 52 screws were accomplished without misplacements or complications.

**Conclusions:** Guide pin integrated pedicle screws can be safely placed only with anteroposterior fluoroscopy. The tip of the 25 mm advanced guide pin, with 10° inward, should be slightly outside the medial wall of the pedicle in anteroposterior fluoroscopy for safe placement. This method is also helpful for reducing radiation exposure.

1717

## Is Three-Dimensional Navigation Decreasing the Learning Curve for Thoraco-Lumbar-Sacral Pedicle Screw Insertion? Comparative Study of Accuracy between Chief Spine Consultant and Spine Fellows under His Study

Shreenidhi Kulkarni

*Kokilaben Dhirubhai Ambani Hospital and Medical Research Institute, Mumbai, India*

**Introduction:** To compare the accuracy of thoracolumbar sacral pedicle screw insertion by an experienced spine consultant and spine fellow with the routine use of three-dimensional (3D) intraoperative imaging and navigation. The use of 3D intraoperative imaging and navigation in spinal surgery is aimed at improving the accuracy of pedicle screw insertion.

**Methods:** Patients who had undergone thoracolumbar pedicle screw insertion using intraoperative imaging and navigation between 2017 and 2021 were retrospectively analyzed. Computed tomography (CT) images acquired after the insertion of pedicle screws were analyzed for breach of the pedicle wall. The pedicle screw breaches were graded according to the Gertzbein classification. The breach rate and revision rate were subsequently calculated.

**Results:** A total of 2,646 thoracolumbar pedicle screws inserted using intraoperative 3D navigation were analyzed, of which 1,573 were inserted by a spine consultant, 503 by fellow 1 and 570 by fellow 2 under his training. A total of 18 pedicle screws showed grade 1 breach out of which 11 were by the consultant, 4 and 3 by the two fellows under his study. The accuracy of the insertion was 99.31% (2,628 of 2,646) overall with 99.3% (1,562 of 1,573) being the accuracy of the chief consultant, 99.2% (499 of 503), and 99.4% (567 of 570) by two fellows under his study. All the breaches were grade 1, the intraoperative screw revision rate was 0%.

**Conclusions:** The routine use of 3D navigation and intraoperative CT imaging resulted in consistently accurate pedicle screw placement irrespective of the consultant or his fellow. This improved the safety of spinal instrumentation and helped in avoiding revision surgery or complications related to mal-positioned screws.

1720

## Biplanar Expandable Cages for Transforaminal Lumbar Interbody Fusion Is Safe and Achieves Good 1-Year Clinical and Radiological Outcomes in an Asian Population

David Shaoen Sim

*Singapore General Hospital, Singapore*

**Introduction:** Biplanar expandable (BE) cages have been recently designed for use in transforaminal lumbar interbody fusion (TLIF) to treat degenerative lumbar spinal conditions as they offer advantages over conventional static cages and uniplanar expandable cages. The BE cage assessed in this study involves a 2-piece device consisting of a polyetheretherketone shell that expands bidirectionally in width and height with the insertion of a titanium shim, allowing for improved restoration of segmental lordosis with decreased theoretical risk of subsidence due to greater implant-endplate contact surface area. This study investigated 1-year clinical and radiological outcomes of biplanar expandable cages following TLIF in an Asian population.

**Methods:** Retrospective review was conducted of all consecutive patients who underwent TLIF with BE cages performed by two fellowship trained spine surgeons from 2020 to 2021. Inclusion criteria included open or minimally invasive (MIS) TLIF, of up to three spinal segments, performed for treatment of degenerative disc disease, spondylolisthesis, or spinal stenosis. Patient reported outcomes including Visual Analog Scale (VAS) for back and lower limb pain, Oswestry Disability Index (ODI), and North American Spine Society Neurogenic Symptom Score (NSS) were assessed. Radiographs taken preoperatively and at final follow-up were compared with evaluation of the following radiographic parameters: anterior disc height, posterior disc height, foraminal height, segmental lordosis, lumbar lordosis, cage subsidence, and implant loosening.

**Results:** Twenty-three patients underwent TLIF with BE cages with a follow-up duration of 1.25 years. Seven patients (30%) underwent one-level TLIF, 12 patients (52%) underwent two-level TLIF, and four patients (18%) underwent three-level TLIF, with a total of 43 spinal segments fused. Four patients (17%) underwent MIS TLIF while 19 patients (83%) underwent open TLIF. VAS for back pain

improved by  $4.8 \pm 3.4$  from  $6.5 \pm 2.6$  to  $1.7 \pm 2.2$  ( $p < 0.001$ ); VAS for lower limb pain improved by  $5.2 \pm 3.8$  from  $5.7 \pm 3.4$  to  $0.5 \pm 1.6$  ( $p < 0.001$ ); ODI improved by  $29.0 \pm 18.1$  from  $49.4 \pm 15.1$  to  $20.4 \pm 14.2$  ( $p < 0.001$ ); NSS improved by  $36.8 \pm 22.1$  from  $53.3 \pm 21.1$  to  $16.5 \pm 19.8$  ( $p < 0.001$ ). Significant improvements in radiological parameters included an increase in anterior disc height by  $3.2 \pm 2.0$  mm from  $8.8 \pm 2.7$  to  $12.0 \pm 2.4$  mm ( $p < 0.001$ ), posterior disc height by  $2.1 \pm 1.5$  mm from  $5.3 \pm 1.5$  mm to  $7.4 \pm 1.5$  mm ( $p < 0.001$ ), foraminal height by  $1.7 \pm 1.7$  mm from  $12.1 \pm 2.6$  mm to  $13.8 \pm 2.9$  mm ( $p < 0.001$ ), segmental lordosis by  $2.8^\circ \pm 2.2^\circ$  from  $7.2^\circ \pm 3.9^\circ$  to  $10.0^\circ \pm 3.3^\circ$  ( $p < 0.001$ ), and lumbar lordosis  $6.1^\circ \pm 7.2^\circ$  from  $36.5^\circ \pm 14.8^\circ$  to  $42.6^\circ \pm 12.1^\circ$  ( $p < 0.001$ ). There were no implant-related complications or revision surgery at 1 year.

**Conclusions:** Early results of TLIF performed with BE cages lead to significantly improved patient satisfaction at 1 year, improved radiographic parameters, and are safe for use in Asians. Nevertheless, larger studies with longer follow up duration are required to elucidate the unique potential benefits of biplanar expandable cages.

1728

## An Indigenously Developed Versatile Halopelvic Ilizarov Distraction Assembly for Correction of Spine Deformities

Muhammad Saad Ilyas

*Ghurki Trust Teaching Hospital, Lahore, Pakistan*

**Introduction:** Halopelvic traction device has been used in the past to manage severe spinal deformities but many cumbersome complications were reported. Keeping in view the halo-pelvic distraction as an effective and affordable means of treatment, which can also be modified to reduce the rate of complications, a halo-pelvic apparatus was designed using a standard Ilizarov set. The constructed assembly incorporated the versatility of an Ilizarov ring fixator and was used for various types of spinal deformities.

**Purpose:** Current study aims to assess the functional outcomes of the modified assembly.

**Methods:** Patients presented to the department with various spinal deformities between January 2021 to August 2021 were applied to modified halopelvic assembly before definitive surgery of kyphoscoliosis. The modified

assembly consisted of a pelvic component made from 2 Ilizarov femoral arches, connected to each other anteriorly, through a threaded rod. The posterior aspect of the assembly was kept free from any rods or arches so that the patient could lie supine. The Ilizarov femoral arches were anchored to the pelvis bone with Ilizarov half pins (6 mm in adults and 5 mm in children). On each side of the pelvis, one pin was placed in the supra-acetabular area and a 2nd pin 10 to 12 cm posterior to the anterior superior iliac spine. The halo ring was anchored with the skull using 6 pins in a standard manner. The pelvic assembly and the halo ring were connected using 4 threaded rods, through which distraction was given at the rate of 2 to 3 mm per day. Distraction was continued from 4 to 8 weeks, keeping an eye on the neurology, signs of pin tract infection, and pin loosening. For cervical scoliosis patients, 4 hinges were incorporated into the construct, after an osteotomy at the level of the C3 vertebra, gradual distraction was done at the concave side and compression at the convex side for 6 weeks.

**Results:** Modified assembly was applied to 32 patients (age range, 8–36 years; 20 males and 12 females), among them 30 presented with kyphoscoliosis (of various etiologies including 7 post caries severe kyphotic deformities with maximum Cobb angle of 168°), 01 with cervical scoliosis and 01 with cervical trauma. More than 60% improvement in the magnitude of the deformity was noted in all cases of kyphoscoliosis with the improvement of neurology in 4/5 paraplegic patients. Two patients gained grade 4 power in the 1st week of distraction while the other two gained grade 2 power. The cervical scoliosis patient had a congenital fusion of C2–C5 vertebrae with severe torticollis, the deformity was corrected in 6 weeks. The cervical trauma had an unstable fracture of the C2 vertebra, assembly was applied to immobilize the spine and the patient was mobilized the very next day. After 8 weeks the assembly was removed with complete healing of the fracture.

**Conclusions:** The results of this study reveal that our modified halo-pelvic Ilizarov distraction assembly is a device with unlimited potential, which can achieve good correction in various severe spinal deformities without significant risk to neurology, fewer complications, and good patient compliance.

1739

## Useful Axial Reformatting of Magnetic Resonance Myelography Based on Balanced Steady-State Free Precession

Hiroki Iwai

*Iwai Orthopaedic Medical Hospital, Tokyo, Japan*

**Introduction:** Iwai Orthopaedic Medical Hospital and Inanami Spine and Joint Hospital have taken three-dimensional (3D) magnetic resonance (MR) myelography obtained from balanced steady-state free precession for all cases of lumbar magnetic resonance imaging (MRI) since 2007. The coronal images are scanned with a 1.4 mm slice thickness and additionally require only around 3 minutes. These views have contributed to radiographic diagnosis, especially in intra- or extra-foraminal herniation and stenosis. Moreover, axial planes with 1.5 mm thickness have been reconstructed using these coronal images since 2017. These images are extremely useful for lumbar disorders related to nerves and actual cases in which this reformatting was highly beneficial will be displayed.

**Methods:** Our institutions possess 1.5T and 3.0T General Electric MRI devices. We have employed FIESTA (fast imaging employing steady-state acquisition, General Electric) application, one of the balanced steady-state free precession techniques, in the 3D MR-myelography. Radiological technicians took these planes with 1.4 mm slice thickness leading to 72–90 images as routine lumbar MRI sequences. They set repetition time at 5.6 ms, echo time at 2.2 ms, which depends on the number of slices, and flip angle of 65°. In addition, the technologists automatically reconstructed 1.5-mm-thickness axial views. We picked up three types of case series where the reconstructed images are advantageous for tracing nerve roots and diagnosing small herniations and various kinds of stenoses.

**Results:** (1) Pursuing nerve roots: 1.5-mm-thickness axial images help physicians to trace nerve roots. Some patients have bifurcated S2 nerve roots located at L5/S1 level; however, usual 3- or 4-mm-thickness axial T2 images hardly detect this abnormal anatomical condition. Especially the reconstructed planes are useful for tracing S2 nerve roots from the caudal side and determining bifurcations. (2) Diagnosis of herniation: images with 3 to 5 mm thickness can easily lead to misdiagnosis of small-sized herniation. The thinner MR planes are, the less misdiagnosis occurs.



(3) Diagnosis of stenoses: the degree of stenosis is more precisely assessed compared with conventional axial images. These images are essential for identifying mild to moderate lateral recess stenoses, far-out syndrome, and stenoses at abnormal locations such as between L6/S1 disc and spurred transverse process.

**Conclusions:** The axial reconstructed images obtained from FIESTA are critical when patients are suspected to have lumbar degenerative diseases.

1741

## Single Step Percutaneous Pedicle Screw System Is Safe, Effective and Has Good 1-Year Outcome in an Asian Population

David Shaoen Sim

*Singapore General Hospital, Singapore*

**Introduction:** Minimally invasive transforaminal lumbar interbody fusion (MIS-TLIF) is an increasingly popular method to treat degenerative lumbar spinal conditions as the minimally invasive approach reduces skin incision and soft tissue morbidity. New single-step percutaneous pedicle screw systems (SSPPSS) have been developed for MIS-TLIF. SSPPSS eliminates the need for Jamshidi needles and guidewires, which are still required when using conventional MIS screw systems (CMSS). This new design aims to cut down operating time and potentially decrease surgical morbidity because of the reduced steps involved. The goal of this study is to demonstrate that SSPPSS is safe and effective, when compared to CMSS, in an Asian population.

**Methods:** This is a retrospective review of consecutive patients who underwent MIS-TLIF with SSPPSS or CMSS by a single surgeon from 2018 to 2021 with 1-year follow-up. Inclusion criteria for both procedures consisted of degenerative disc disease, spondylolisthesis, and spinal stenosis. This study evaluated inpatient details including operating time and length of hospital stay. Patient-reported outcomes recorded included Oswestry Disability Index (ODI), North American Spine Society Neurogenic Symptom Score (NSS), and Visual Analog Score (VAS) for back pain. One-year radiographic parameters such as subsidence, loosening, and bony fusion were also evaluated. MIS-TLIF was first performed with CMSS for the initial cases while SSPPSS was used for all subsequent cases after

this new technology was available.

**Results:** Twelve SSPPSS and 22 CMSS MIS-TLIF patients were included. Both groups were similar in age, body mass index, gender, preoperative ODI, NSS, and VAS. Operating time for SSPPSS was significantly shorter than CMSS ( $230 \pm 33$  minutes vs.  $275 \pm 40$  minutes for SSPPSS and CMSS group, respectively;  $p=0.002$ ). Length of hospital stay was similar for both groups ( $3.3 \pm 1.9$  days vs.  $4.6 \pm 1.8$  days,  $p=0.061$ ). There was no significant statistical difference in the 1-year postoperative ODI ( $12.0 \pm 6.7$  vs.  $12.3 \pm 13.6$ ,  $p=0.942$ ), NSS ( $12.3 \pm 11.2$  vs.  $11.6 \pm 13.2$ ,  $p=0.879$ ), and VAS ( $0.6 \pm 1.6$  vs.  $0.6 \pm 1.5$ ,  $p=0.993$ ) between SSPPSS and CMSS group. There was no cage subsidence, implant loosening, or vessel injury. Radiographic evidence of fusion was observed at 1-year follow-up for all patients.

**Conclusions:** No complications were reported in patients who were operated with SSPPSS. Patients in this group also experienced shorter operating time compared to the CMSS group. The 1-year follow-up on patients from both SSPPSS and CMSS groups showed similar outcome scores. This study has also shown that SSPPSS is safe and effective in an Asian population.

1849

## Identification and Validation of Self-Screening Tests for Endemic Cervical Fluorosis

J. Naresh-Babu

*Mallika Spine Centre, Guntur, India*

**Background:** Diagnosis of cervical myelopathy is often difficult due to subtle symptoms and lack of suspicion. In many cases, patients from the endemic areas present late with severe myelopathy. By developing self-screening tests and symptoms, awareness can be created in the endemic population to seek medical help early. Currently, there are no screening tools available in the world literature. With a combination of simple questionnaires and easily elicitable clinical tests, we aim to develop self-screening tools for fluorotic myelopathy.

**Methods:** The study was conducted in two phases. In phase I, screening tools were developed with 30 cervical myelopathic patients as cases and 30 patients with neck/radicular complaints but no myelopathic symptoms as controls. Twenty items from the Japanese Orthopedic Association Cervical Myelopathy Evaluation Questionnaire

and five easily demonstrable clinical signs were evaluated. Data were analyzed by univariate analysis and multiple logistic regression analysis. In phase 2, the validity of the developed questionnaire and tests were evaluated in 480 subjects by five health workers in the endemic population with the help of the National Program for Prevention and Control of Fluorosis. Those who satisfy the criteria were subjected to the magnetic resonance imaging examination and the results were analyzed.

**Results:** Five questions were chosen by statistical analysis and each was assigned a score of two. A score greater than or equal to 6 was as cut-off, and two of the five positive clinical tests were found to predict cervical myelopathy with the area under the receiver operating characteristic curve of 0.78, sensitivity of 91.6%, and a specificity of 63.2%. Of the clinical tests, Romberg test was found to demonstrate the highest sensitivity (83%). Of the 480 subjects screened with these developed tools, 37 (7.7%) were found to satisfy the criteria, and of them, 11 were found to have radiological cord compression with a positive predictive value of 0.84.

**Conclusions:** Simple self-screening tools with a combination of five questions and five clinical tests were found to successfully screen fluorotic myelopathy. The presence of three of five positives in the questionnaire or two of five positive tests was found to be highly sensitive for screening. Of all the clinical tests, the Romberg test was found to be highly sensitive in predicting cervical myelopathy. These tools can be utilized to rapidly screen cervical myelopathy in the outpatient clinic as well as for epidemiological purpose by educating the local health workers.

---

**1873**

## Analysis of Patients with Delayed Diagnosis of Pyogenic Spondylitis

Junya Tsukisaka

*Matsuyama Red Cross Hospital, Matsuyama, Japan*

**Introduction:** Pyogenic spondylitis is a life-threatening, severe disease. Delayed treatment initiation can lead to sepsis or neurologic paralysis. Pyogenic spondylitis is increased with the increasing population of elderly and the number of compromised hosts in Japan. Early diagnosis and treatment initiation are important to improve prognosis; however, many patients with pyogenic spondylitis

have delayed diagnosis and treatment initiation.

**Purpose:** The study aimed to analyze patients with pyogenic spondylitis who had delayed diagnosis.

**Methods:** We retrospectively analyzed 73 patients (men, 47; women, 26) who were diagnosed with pyogenic spondylitis at our orthopedic clinic from January 2010 to August 2022. The average age at the time of diagnosis was 70.9 years. A total of 32 patients who required  $\geq 2$  weeks for diagnosis (group D) were analyzed for factors of delayed diagnosis. Furthermore, the prognosis of patients in group D was compared with that of the other 41 patients (group E), who required  $< 2$  weeks for diagnosis.

**Results:** In group D, 24 patients visited our clinic at  $> 2$  weeks after the onset, 12 visited other departments in our institute for the treatment, and nine had treatment in other hospital. Eight patients visited our orthopedic clinic in  $< 2$  weeks after the onset, but they were not diagnosed with pyogenic spondylitis, five showed no typical symptoms, two showed no typical findings even on blood examination and contrast-enhanced magnetic resonance imaging (MRI), and one with a pacemaker could not have MRI. The C-reactive protein positive period (average in group D: 100.8 days, group E: 75.8 days) and length of hospital stay (average in group D: 77.8 days, group E: 72.2 days) in group D were longer than those in group E. Four patients (12.5%) in group D and one (2.4%) in group E died even after the systemic therapy.

**Conclusions:** Some patients with pyogenic spondylitis were difficult to diagnose, and some did not have typical physical findings or blood examination and radiographic findings during the early period after the onset. The possibility of pyogenic spondylitis should be considered in patients with fever or pain in the neck, back, and lumbar areas due to unknown causes. In addition, patients without typical findings on blood or radiographic examination may possibly suffer from pyogenic spondylitis if complain of symptoms similar to those suspected with pyogenic spondylitis.

1882

## Assessment of Outcomes of Spine Surgery in Indian Patients Involved in High-End Contact Sports

Priyank Patel

Jupiter Hospital, Pune, India

**Introduction:** About 30% of athletes suffer from spinal symptoms over the course of their career which accounts for one of the most common reasons for absenteeism from sports. Successful return to play for professional athletes at their preinjury level of performance is important. A large subset of patients does not respond to non-surgical management. There is a paucity of data regarding the duration of return to play especially in contact sports after spine surgery. There are few review articles summarizing the outcomes of spine surgery in athletes and return to play. There are no studies with Indian data.

**Purpose:** The aim of the study is to assess the outcomes of spine surgeries in Indian patients involved in contact sports.

**Methods:** This is a retrospective study that included 10 consecutive patients involved in high-end contact sports undergone surgery for degenerative spine pathology. Eight patients underwent lumbar surgery (two patients of microdiscectomy and six patients of fusion) and two patients underwent cervical fusion. Primary outcome measures returned to training and return to sports. Also, endpoint criteria for return to sports were set, which included resolution of preoperative pain, restoration of the full range of motion, full strength, and no evidence of neurologic injury. Also, complications requiring reintervention were documented.

**Results:** Out of 10 patients, eight were males and two were females. The average age of intervention was 32.4 years (range, 25–41 years). The average time for return to training was 7.3 weeks (range, 3–12 weeks). The average time for a return to contact sports was 45.6 weeks (range, 36–72 weeks). The average follow-up is 59 months (range, 27–120 months). One patient had aseptic discitis following lumbar fusion which got better with antibiotics. No patient had any major complications requiring reintervention (Table 1).

**Conclusions:** Spine surgery in patients involved in contact sports is safe and effective with excellent outcomes.

Patients can return back to training and playing contact sports at the pre-surgery level. Currently, there are no standardized consensus guidelines for return to play after spine injuries. In patients with complete resolution of preoperative pain, restoration of full range of motion, full strength, and no evidence of neurologic injury it is safe to return to sports as early as 3 months.

**Table 1.** Results of spinal surgery in patients

No.	Name	Age (yr)/sex	Sports	Diagnosis	Surgery	Return to training	Return to contact sports (mo)	Recurrence of symptom	Follow-up (mo)	Reintervention/complications
1	Dranun	35/M	Marathoner	L4–5PID	Discectomy	12 wk	5		75	None
2	Narendra Hirwani	30/M	Cricketer	L4–5PID	Fusion	6 wk	3		60	None
3	Charuhas Joshi	37/M	Mountaineer	L3–5PID	L35 fusion	6 wk	3		52	None
4	Lendli Simons	31/M	Cricket	Disc disease	L45 fusion	6 wk	3	None	27	None
5	Jaidev Punjabi	25/M	Tennis	Instability	Redo L3-5 fusion	6 wk	3		120	None
6	Kaizeen	29/F	Marathoner	L4–5PID	Discectomy	10 wk	6	Recurrent back pain episodes getting better with rest	105	None
8	Jayeshmukadam	28/M	Wrestling	Disc disease	ACDF	6 wk	3		36	None
9	Vijay kumar	29/M	Shooter/marathoner	Disc disease	ACDF	6 wk	3		45	None
10	Avenjesia	39/F	Marathon	Instability	L3–5 fusion	3 wk	3	0	41	None
11	Harish jere	41/M	Marathon	L3–4 listhesis	L34 fusion	4 mo	6		29	Aseptic discitis immediate post-operative causing delayed rehabilitation

Lumbar microdiscectomy (n=3); lumbar fusion (n=5); ACDF (n=2).

M, male; F, female; PID, prolapsed intervertebral disc; ACDF, anterior cervical discectomy and fusion.

1925

## Assessment of Posterior Ligamentous Complex Injury by Computed Tomography and Magnetic Resonance Imaging Scan in AO Type-A Fractures of the Thoracolumbar Spine on Radiographs

Manish Chadha

University College of Medical Sciences, New Delhi, India

**Introduction:** The posterior ligamentous complex (PLC) is thought to contribute significantly to the stability of the thoracolumbar spine. PLC functions as a posterior tension band and acts as the primary stabilizer of the vertebral column. Many studies focus on plain radiographic find-

ings and various radiological parameters were identified that were determinants of probable PLC injury. However, confusion exists when plain radiography shows no signs of posterior column involvement.

**Methods:** We recruited 49 normal appearing plain radiographs cases for the study after fulfilling inclusion and exclusion criteria. Following this subsequent computed tomography (CT) scans and magnetic resonance imaging (MRI) was done and evaluated by orthopedic surgeon and radiologists for any signs of PLC injury. We also evaluated the correlation of PLC injury with parameters like loss of vertebral body height (LOVBH) and local kyphosis (LK) and their significance.

**Results:** Of the 49 patients, 13 patients initially diagnosed as AO-A on radiographs were revised to a diagnosis of AO-B on a CT scan. Of the 49 patients, 22 patients diag-

nosed as AO-A on radiographs were revised to a diagnosis of AO-B on MRI scans. This included 13 cases where a CT scan also showed posterior column injury and nine cases where even a CT scan did not show evidence of posterior column injury. Using the chi-square test we found that there was a statistically significant difference between CT scan and MRI in identifying PLC injury ( $p < 0.001$ ). We found a significant correlation between LK and PLC injury in patients having a kyphotic angle of  $>20^\circ$  and it was statistically significant by the chi-square test ( $p < 0.05$ ), however for LOVBH was statistically non-significant.

**Conclusions:** In a setting of normal-appearing plain radiographs, we noted to have missed 44.9% (22/49) of cases of PLC injury in AO type A fractures. Local kyphosis was significantly correlated with PLC injury but loss of vertebral body height was not.